

## The Diagnosis of posterior Reversible Leukoencephalopathy Syndrome: A Prospective Study

Dr PareshKumar Sukhani<sup>1</sup>, Dr Nipun Gumber<sup>2</sup>, Dr Hemant Kumar Mishra<sup>3</sup>

Associate Professor<sup>1</sup>, Junior Resident<sup>2</sup>, Professor and Head of Department<sup>3</sup>

Department Of Radiodiagnosis, Mahatma Gandhi Medical College And Hospital,Jaipur.

\*Corresponding Author: Dr PareshKumar Sukhani

---

### Abstract

#### Introduction

Reversible posterior leukoencephalopathy syndrome (PRES) is a reversible condition with vasogenic cerebral edema as main pathological feature. Lesion mainly involves posterior part of cerebrum with wide range of symptoms ranging from headache, seizure, altered mental status, nausea, vision loss etc.

#### Aim

To study the clinical and radiological features of PRES.

#### Material And Methods

A prospective study was conducted in Mahatma Gandhi Medical College, Jaipur with 15 cases from June 2017-December 2017.

#### Results

Out of 15 patients, 12 were female and 3 were male with a mean age of 32.06 years. Most common presentation was seizure (53.3%) followed by altered mental status (33.3%) and headache (13.3%). Main comorbid illness in our study were eclampsia and postpartum sepsis (46.6%), renal diseases (26.6%), hypertension (26.6%). Most common site was occipito-parietal region on MRI brain (86.6%). Other atypical presentation involved temporal lobe (40%), basal ganglia (20%) and infarct (13.3%).

#### Conclusion

PRES is a reversible condition and has good outcome in most of the patients. In our study seizure is the most common presentation and hypertension is the most common comorbid illness and occipital regions are most common site on MRI.

**Key words** – PRES, hypertension, occipital

---

Date of Submission: 03-02-2018

Date of acceptance: 19-02-2018

---

### I. Introduction

Posterior reversible encephalopathy syndrome also known as reversible posterior leukoencephalopathy is a clinic-radiological entity, comprising headache, seizure, and mental confusion as main clinical feature. In radiological imaging abnormalities are seen in posterior region of both cerebral hemispheres<sup>1</sup>. Though pathophysiology of PRES is not clearly understood, but disruption of blood-brain barrier, which leads to vasogenic edema is characteristic of it. There is no specific age group for this condition, but most of the cases occur in 3<sup>rd</sup> to 5<sup>th</sup> decade of life, with predominance in females. Eclampsia is the main comorbidity in PRES. Other major comorbidities involved are hypertension, renal diseases, organ transplantation, autoimmune diseases, (SLE, scleroderma), electrolyte imbalance, sepsis. The outcome is good with complete recovery in most of the patients in a period ranging from days to months<sup>2</sup>. Though several studies were done in INDIA and elsewhere on PRES, it has not been extensively studied of late in our state. The purpose of this study was to describe the clinic-radiological profile of PRES.

### II. Material And Methods

A prospective study was conducted in Mahatma Gandhi Medical hospital, Jaipur from a period of June 2017 to December 2017 in radiology department. Inclusion criteria included who had positive findings on MRI and exclusion criteria included those who had no positive finding on MRI IMAGING.

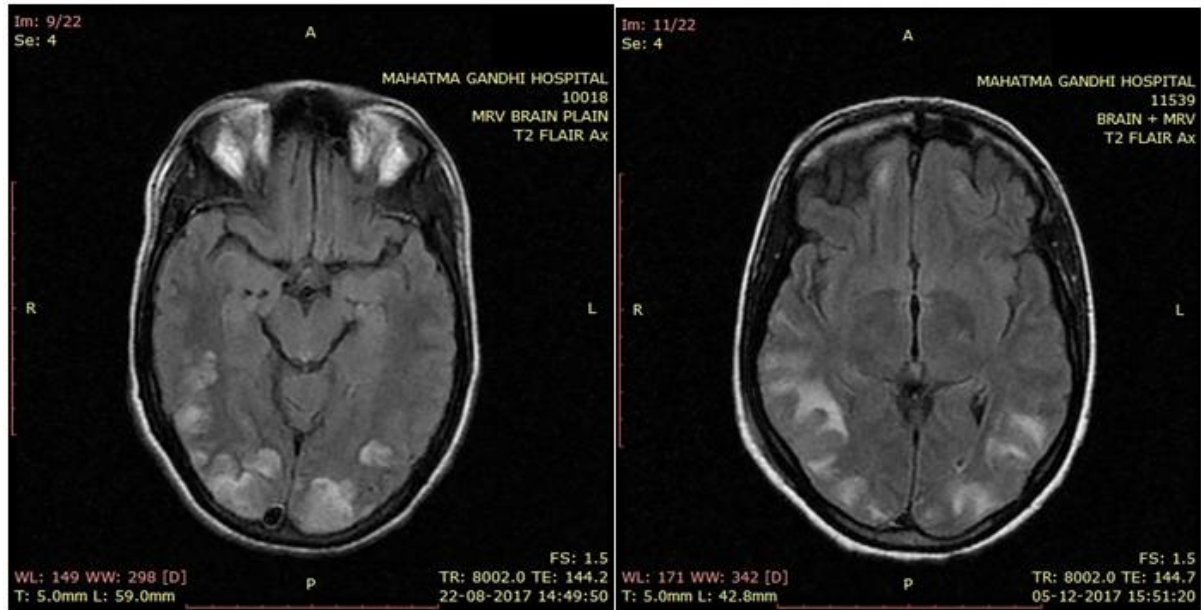
### III. Result

Out of 15 patients, 12 were female and 3 were male with a mean age of 32.06 years. Most common presentation was seizure (53.3%) followed by altered mental status (33.3%) and headache (13.3%). Main comorbid illness in our study were eclampsia and postpartum sepsis (46.6%), renal diseases (26.6%),

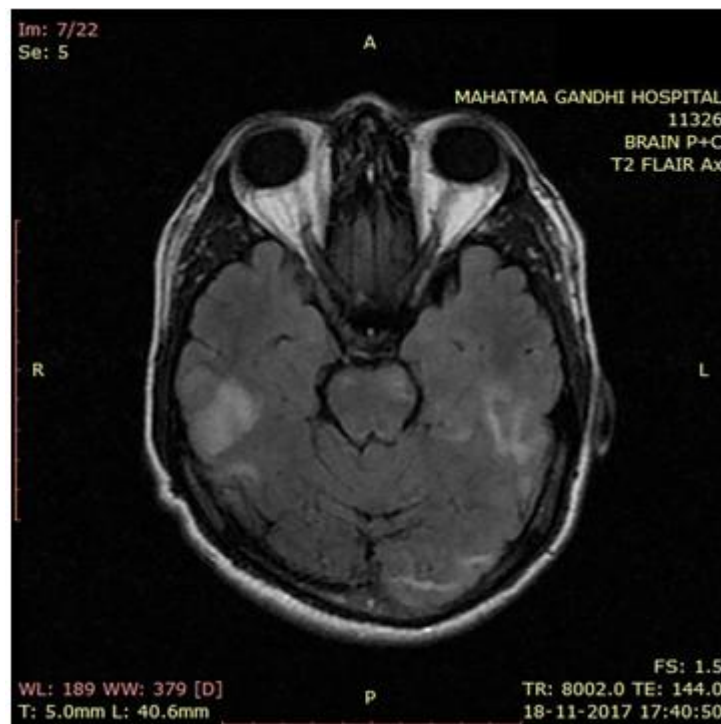
hypertension (26.6%). Most common site was occipito-parietal region on MRI brain (86.6%). Other atypical presentation involved temporal lobe (40%), basal ganglia (20%) and infarct (13.3%).

### NEURO-imaging

MRI imaging is the cornerstone for the diagnosis of PRES. It has characteristic hypointensity on T1W image and hyper intensity on T2W image and FLAIR images. Most common site was occipitoparietal lobe, followed by temporal lobe. Atypical presentation involved temporal lobe, corpus callosum, brainstem, thalamus, basal ganglia and infarct. Least common involvement was seen in the internal capsule. Diffusion weighted images do not show any restricted diffusion in typical PRES. However, areas of restricted diffusion can be seen in atypical PRES.



**FIGURE 1 &2-**Axial images showing FLAIR hyperintensities in bilateral occipital and parietal lobes. These are consistent with typical PRES.



**FIGURE3-**Axial image showing FLAIR hyper intensities in bilateral parietal and midbrain –ATYPICAL PRES

#### **IV. Discussion**

**Posterior reversible encephalopathy syndrome (PRES)** is a neurotoxic state that occurs secondary to the inability of the posterior circulation to auto regulate in response to acute changes in blood pressure. Hyper perfusion with resultant disruption of the blood brain barrier results in vasogenic oedema, but not infarction, most commonly in the parieto-occipital regions.

Neuroimaging by Computed Tomography and MRI helps in reaching the diagnosis. The pathophysiology of PRES remains unclear. Various theories have been proposed, the most widely accepted theory of which states that rapidly developing hypertension leads to a breakdown in cerebral auto regulation, particularly in the posterior head region where there is a relative lack of sympathetic innervation<sup>3</sup>. Hypo perfusion ensues with protein and fluid extravasation, producing focal vasogenic edema. An alternative theory, which has been best characterised in pre-eclampsia, eclampsia and sepsis implicates endothelial dysfunction. A third theory proposes that vasospasm with subsequent ischemia may be responsible<sup>4</sup>.

Most commonly there is vasogenic oedema within the occipital and parietal regions (~95% of cases), perhaps relating to the posterior cerebral artery supply<sup>5</sup>. Despite being termed posterior, PRES can be found in a non-posterior distribution, mainly in watershed areas, including within the frontal, inferior temporal, cerebellar, and brainstem regions. Both cortical and subcortical locations are affected. Parenchymal infarctions and haemorrhage are associated with PRES in respectively 10-25% and 15% of cases. On MRI the affected regions are hypo intense on T1W and hyper intense on T2W and FLAIR images. They do not show contrast enhancement on post contrast sequences. Diffusion weighted imaging is usually normal. GRE may show hypo intense signal in cases of haemorrhage and SWI may show microhaemorrhages in some cases.

#### **V. Conclusion**

PRES is a challenging condition because of its variability of clinical symptoms and signs. A high index of clinical suspicion is needed to diagnose PRES. Radiological imaging is the hallmark in the diagnosis of this condition.

#### **References**

- [1]. Fugate JE1, Claassen DO, Cloft HJ, Kallmes DF, Kozak OS, Rabinstein AA. Posterior reversible encephalopathy syndrome: associated clinical and radiologic findings, Mayo Clin Proc. 2010 May;85(5):427-32.
- [2]. Raroque HG Jr1, Orrison WW, Rosenberg GA. Neurologic involvement in toxemia of pregnancy: reversible MRI lesions. 1990 Jan;40(1):167-9.
- [3]. Pedraza R, Marik PE, Varon J. Posterior reversible encephalopathy syndrome: A review. Crit Care Shock 2009;12:135-43.
- [4]. Bartynski WS, Boardman JF, Zeigler ZR, Shaddock RK, Lister J. Posterior reversible encephalopathy syndrome in infection, sepsis, and shock. AJNR Am J Neuroradiol 2006;27:2179-90.
- [5]. Okamoto K1, Motohashi K, Fujiwara H, Ishihara T, Ninomiya I, Onodera O, Fujii Y [PRES: Posterior Reversible Encephalopathy Syndrome]. 2017 Feb;69(2):129-141.

Dr Paresh Kumar Sukhani "The Diagnosis of posterior Reversible Leukoencephalopathy Syndrome: A Prospective Study. "IOSR Journal of Dental and Medical Sciences (IOSR-JDMS), Volume 17, Issue 2 (2018), PP 62-64.