

Non Operative Management in Blunt Injury Abdomen, Our Experience at a Tertiary Centre – A Case Series

Dr. Arun Babu.C¹, Dr. Somanatha Sharma.S²

¹ Assistant Professor, Department of General Surgery, Government Stanley Hospital, Chennai, India

² Senior Resident, Department of General Surgery, Government Stanley Hospital, Chennai, India

Corresponding author: Dr.Somanatha Sharma. S

Abstract: Trauma is one of the leading causes of mortality at all age group. Blunt trauma to abdomen is one of the leading cause of death in young. BAT can remain silent after initial injury only to present later with clinical deterioration and can be almost always fatal if not intervened. Liver and spleen are the commonly injured solid organs. Over the past few decades, there is a transition of trend in management from operative procedures to non-operative management as the former carried more mortality and morbidity. NOM has become the widely accepted standard practice of management for BAT. This case series is our institutional experience in the NOM of hemodynamically stable blunt liver, spleen and pancreatic trauma patients irrespective of the severity of a single / multiple solid organ injury or other associated injuries.

Keywords: Blunt Abdomen Trauma, Blunt Injury Abdomen, BAT, Non Operative Management, NOM, Liver and Spleen injuries

Date of Submission: 03-02-2018

Date of acceptance: 17-02-2018

I. Introduction

Trauma is the leading cause of death and disability in the first four decades of life and third most common cause of death overall. Blunt abdominal trauma is one of the leading causes of death in youth. Specifically, solid organs are the most frequently injured organ during abdominal trauma. During the last century, the management of blunt force trauma to the liver has shifted from mainly operative intervention to the practice of selective operative and non-operative management (NOM). Due to high rate of operative morbidity and mortality, non operative management of solid abdominal organ injury has rapidly gained acceptance and has become the standard for care patients with stable hemodynamics, which account for approximately 85% of all those with blunt abdominal trauma. This case series is our institutional experience in the NOM of hemodynamically stable blunt abdominal injuries monitored with serial measurements of various parameters and imaging.

II. Materials And Methods

A retrospective analysis of 32 blunt abdominal trauma patients treated by NOM at Govt Stanley medical college hospital, Chennai, for a period of 1 year (July 2016 – July 2017) to determine the indications, methods and results of NOM. Hemodynamic stability along with ultrasound, computed tomography scan and repeated clinical examination were the pillars of NOM.

Patients were grouped as

1. Those managed by NOM successfully
2. Failure of NOM
 - a. Failed NOM due to clinical deterioration
 - b. Failed NOM due to associated bowel injury

Inclusion Criteria for NOM

- Stable hemodynamic status on arrival or after initial resuscitation: Heart rate < 110 beats/minute and Systolic blood pressure more than 90 millimetres of mercury.
- Imaging study [FAST/ Ultrasonography/ Computed Tomography] of Abdomen whichever deemed necessary revealing Grade of injury from II to V
- The patients with hemodynamic instability, altered level of consciousness, complete avulsion of major vessel, less than 16 years old, and needed invasive and/or surgical intervention were all excluded from this study.

III. Data Collection

Patients who were admitted to our Casualty with blunt trauma between July 2016 and July 2017 were screened for radiological diagnosis. During the 1 year period, 210 polytrauma patients were evaluated for abdominal trauma. Based on initial findings 33 patients were admitted for NOM with solid organ injury of grade 2 and above. Baseline characteristics of patients with blunt abdominal injury such as age, gender, heart rate (HR), systolic blood pressure (SBP), diastolic blood pressure (DBP), mechanism of injury, preferred imaging modality, CT injury grading scale according to American Association for the Surgery of Trauma (AAST) and patient hospitalization were recorded. Blood samples drawn at admission such as serum Hgb, AST, and ALT levels were recorded. Blunt liver injury was defined as radiological findings on abdominal ultrasonography and/or computed tomography (CT) with no evidence of penetrant injury. Hemodynamic stability was defined as systolic blood pressure above 90 mmHg, heart rate below 110/minute, and normal level of consciousness on arrival or during follow-up. NOM consisted of close monitoring with repeated clinical assessment including the evaluation of vital signs such as SBP, HR, temperature, and fluid balance with estimating input and output of fluids in the body and measurement of hemoglobin and hematocrit twice daily at 12 hours apart for the first 48 hours and later once a day until the end of the 5th day follow-up. Any fall in Hemoglobin or Hematocrit levels were monitored more aggressively with serial measurements of Hb and hematocrit every 6 hours. Any worsening of their levels despite adequate measures or fall in systolic blood pressure were considered for operative intervention and categorized under failed NOM. Repeat CT may not be mandatory in failed NOMs.

IV. Results

During the 1 year period, 218 polytrauma patients were evaluated for abdominal trauma. Based on initial findings 32 patients were admitted for NOM with solid organ injury of grade 2 and above. Out of these patients initially selected, 29 were successfully managed non operatively, 2 were subjected to laparotomy due to failure of NOM and 1 patient had combined liver and bowel injury, operated for bowel perforation.

In our analysis NOM succeeded in 100% of all stable isolated liver injuries and in 91.5% isolated splenic trauma. One patient with isolated splenic injury and another patient with combined liver, spleen and pancreas injury who were under NOM criteria deteriorated clinically on day 3 despite adequate measures and underwent laparotomy and considered as failed non operative management. One patient with blunt abdominal injury [bull gore injury] with initial CT revealing Grade IV splenic injury kept under NOM but presented with sealed perforation of bowel on day 2 for which patient was taken up for laparotomy. On table the splenic hematoma looked contained and left untouched. Most splenic and liver injuries required close observation for 3 days and discharged in 1-2 weeks. Mean duration required for close observation in isolated liver injuries were around 4 days and discharged in 2 weeks. The Overall success rate of 88% in our study favours NOM as the standard line of management and concurs with the results of other established studies.

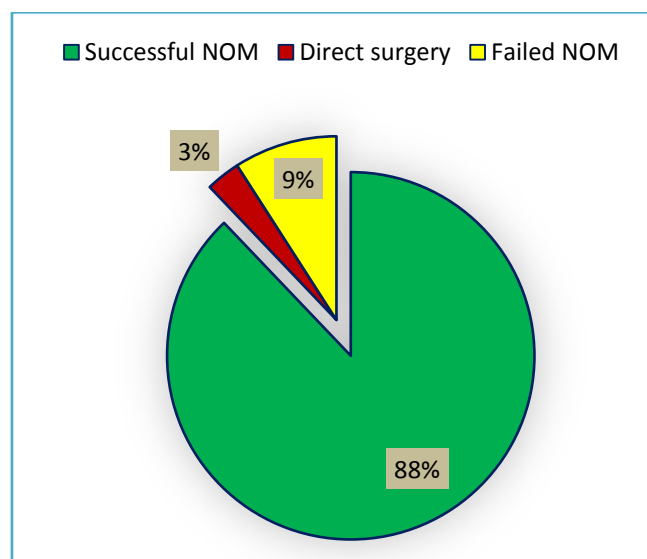


Fig 1 Result of Non Operative Management at our Institution

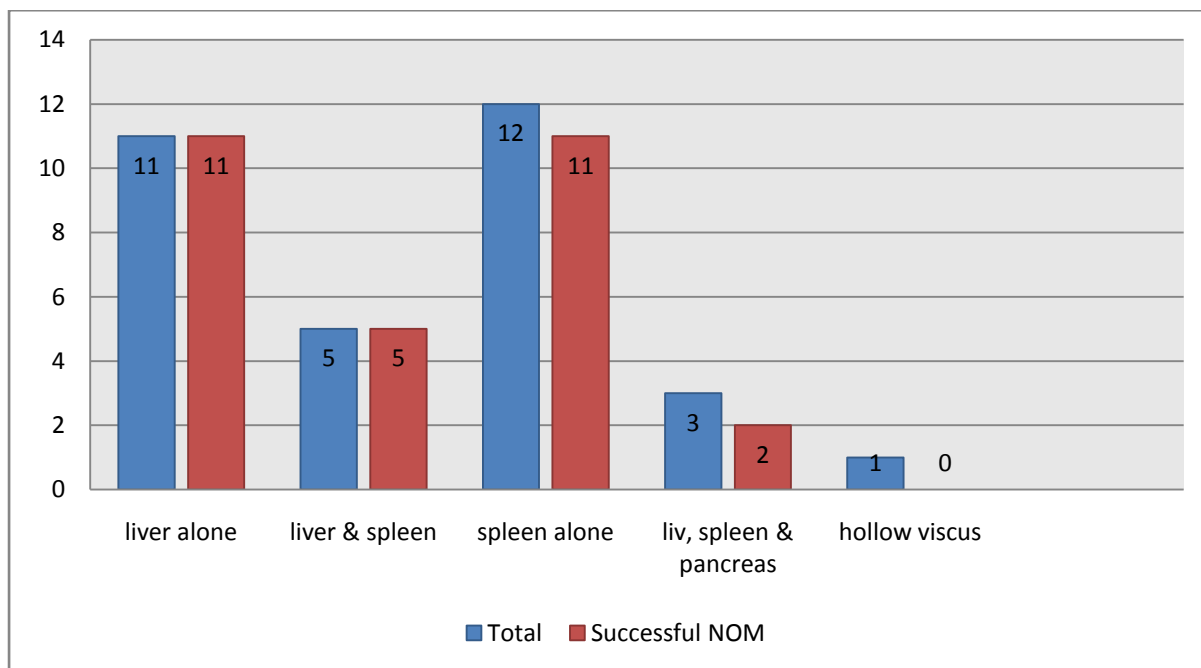


Fig 2 Analysis of Organ involvement and concurrent success of NOM

Number of Patients studied for NOM	32
Age	13-46
Gender	M:F 21:9
Mode	RTA/Assault/Bullgore/Fall of Heavy object
Interval between injury & arrival (Mean)	3 hours 20 mins
Successful NOM [Category - 1]	29
Failed NOM [Category - 2 a]	2
Associated Hollow Viscus perforation [Category - 2 b]	1
Success rate of NOM	88%

Fig 3 Consolidation of the study

V. Conclusion

To conclude, Non operative management for blunt abdominal injuries proves to be highly successful in isolated or combined solid organ injuries of grade 2 and above in our study. Management depended on early arrival following trauma, clinical and hemodynamic stability of the patient, regular clinical examinations and follow up with imaging techniques. An elevated Injury Severity Score significantly increased the risk of failure of nonsurgical management.

Success of NOM is highest in isolated single solid organ injury and better in multiple organ injury in blunt abdomen injuries. Higher anatomical image grading [3-5] of solid organ injury is not a deterrent to NOM. Even patients with multiple abdominal injuries can be successfully managed by NOM provided they are closely monitored. NOM has a significant decrease in length of hospital stay and morbidity compared to patients who undergo surgery. NOM to be terminated if patient develops hemodynamic instability and appearance of new peritoneal signs due to delayed hollow viscus or missed injuries. No procedure /practice are free from risk. Admission to ICU and its related problems, delay in diagnosis and management of missed bowel and vascular injuries are few of the risks involved in NOM. With newer modalities of imaging the percentage of delay in diagnosis is negligible.

References

- [1]. High success with non-operative management of blunt hepatic trauma:the liver is a sturdy organ. *Arch Surg* 2003, 138(5):475-480. Velmahos GC, Toutouzas KG
- [2]. Successful nonoperative management of the most severe blunt spleen injuries: a multicenter study of the research consortium of New England centers for trauma. *Arch Surg* 2012, 147(5):423-428. Gwendolyn M, Van der Wilden
- [3]. Non-operative management of blunt abdominal injuries. *Chir Ital* 2007, 59(1):1-15. Marmorale C, Guercioni G, Siquini W
- [4]. Nonoperative management of blunt abdominal trauma: have we gone too far? *Surg Infect (Larchmt)* 2009 Oct, 10(5):427-433. Peitzman A, Ferrada P, Puyana J
- [5]. Non-operative management of liver trauma. *J R Army Med Corps* 2012 Jun, 158(2):85-95. Swift C, Garner J

Dr. Somanatha Sharma.S "Non Operative Management in Blunt Injury Abdomen, Our Experience at a Tertiary Centre – A Case Series." IOSR Journal of Dental and Medical Sciences (IOSR-JDMS) , vol. 17, no. 2, 2018, pp. 72-75.