

Visual Outcome Following Combined Cataract and Pterygium Surgery

Dr. Pravin Tidake¹, Dr. Rohit Agrawal²
JNMC, Sawangi (Meghe), Wardha

Abstract-

Introduction- In our country both pterygium and cataract have a high incidence. Hence in this study, thirty patients with pterygium and cataract were treated with a simultaneous pterygium excision and cataract extraction procedure.

Material and methods- It was prospective interventional study. The pterygium excision was done without graft following which the cataract was extracted and the patients were treated post-operatively with topical betamethasone 0.1% for a duration of three months. They were followed up for a duration of 2 months postoperatively.

Results- 20 patients (66.6%) had visual recovery of 6/12 and better at the end of 2 months. 14 patients (46.6%) had recurrence of pterygium at the end of 2 months. The combined procedure did not result in any complications after cataract surgery. Post-operatively, after 2 months 12 patients (40%) had with the rule astigmatism and 18 patients (60%) had against the rule astigmatism.

Date of Submission: 25-01-2018

Date of acceptance: 09-02-2018

I. Introduction

A pterygium (plural pterygia) is a triangular fibrovascular subepithelial in growth of degenerative bulbar conjunctival tissue over the limbus onto the cornea.[1]. Loss of vision occurs if it extends across the visual axis[2]. Hence this study is conducted with the aim of evaluating a combined procedure consisting of pterygium excision and cataract extraction. Further, the effect of the combined procedure on the postoperative astigmatism has been studied by doing retinoscopy and by estimation of the visual Outcome[3].

The occurrence of pterygium with cataract creates some additional optical problems. Tight closure of the cataract wound and pterygium both create a with-the-rule astigmatism wound closure by steepening the vertical meridian and pterygium by flattening the 180° axis.[8]

II. Aims And Objectives

1. To study the visual outcome following combined surgery.
2. To study the effect of the combined procedure on the postoperative astigmatism

III. Material And Methods

Study design- prospective interventional study

Inclusion Criteria:

1. Both sexes.
2. >18 years old
3. Primary pterygium > 2mm across corneal limbus [Measurement made from the imaginary line of surgical limbus to the most advance edge of the visible pterygium tissue] Concurrent visually significant cataract
4. Informed consent for both pterygium and cataract surgery

Exclusion Criteria:

1. Temporal pterygium
2. Double headed pterygium
3. Previous ocular surgery in which conjunctival-limbal graft is not feasible
4. Pterygium covering visual axis that preclude keratometric assessment
5. History of scleritis or autoimmune diseases

Pre-operative- Thirty patients (age group 30-80 years) having both pterygium and senile cataract (n = 30 eyes) and able to attend a 2 months follow-up regularly were selected for this prospective study. Those with multiple pterygia, recurrent pterygium, traumatic cataract, complicated cataract and cataract with posterior segment

disorders were not included in this study. 18 of 30 patients (60%) were in the age group of 45-60 years. Sex distribution showed that 21/30 cases (70%) were males.

All the patients were operated after confirming normalcy of blood pressure, sac syringing, intraocular tension and post-prandial blood sugar. Operations were done under local anaesthesia with facial and retrobulbar injections. Initially, pterygium excision was done by performing a superficial keratectomy and creating an area of bare sclera. Next manual small incision cataract surgery (SICS) was done in all the patients without sutures.

Post-operative- These cases were hospitalised for 2 days and administered oral antibiotics for 3 days and topical 2% Homide eye drops twice daily and Moxifloxacin 0.5% and 0.1% dexamethasone eye drops 7-8 times a day for 1 month. The patients were followed up at 15th day, 30th day and 60th day. Postoperative retinoscopy was carried out to assess presence of astigmatism.

IV. Observation & Results

During 2 months of follow-up, recurrence of pterygium was seen in 10 patients (33.3%)

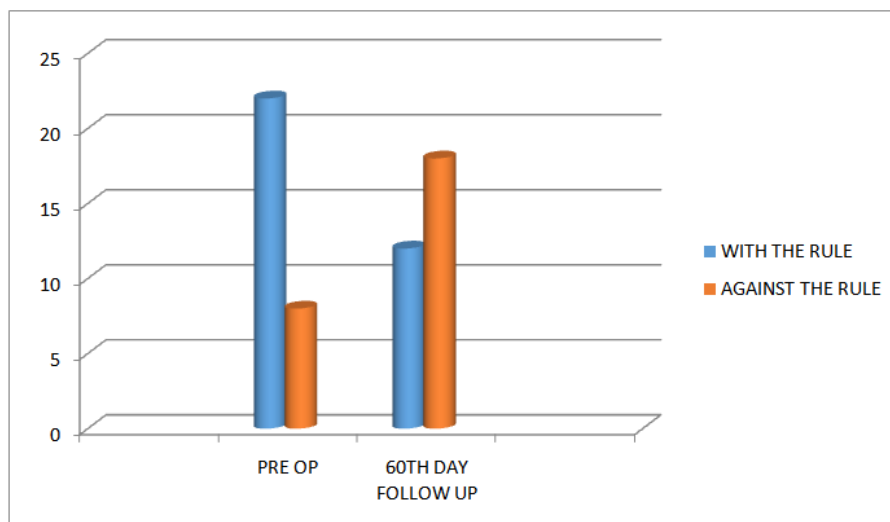
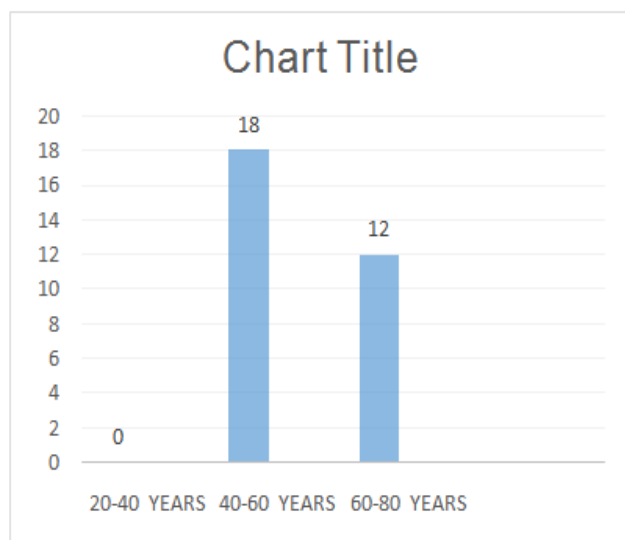
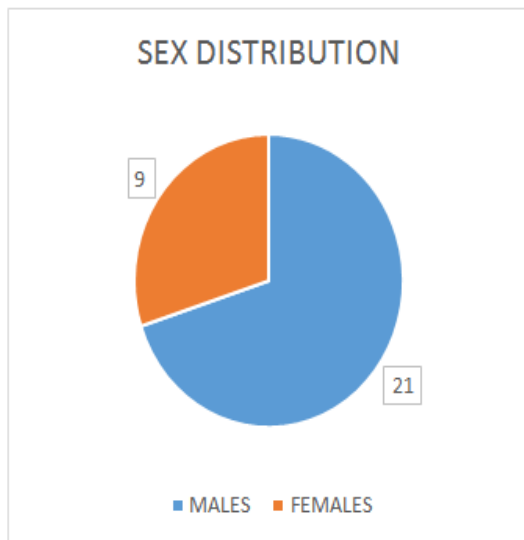
Post-operative retinoscopy revealed that 12 (40%) patients had with the rule astigmatism at 2 months post-operatively and 18 (60%) had against the rule astigmatism at 2 months.

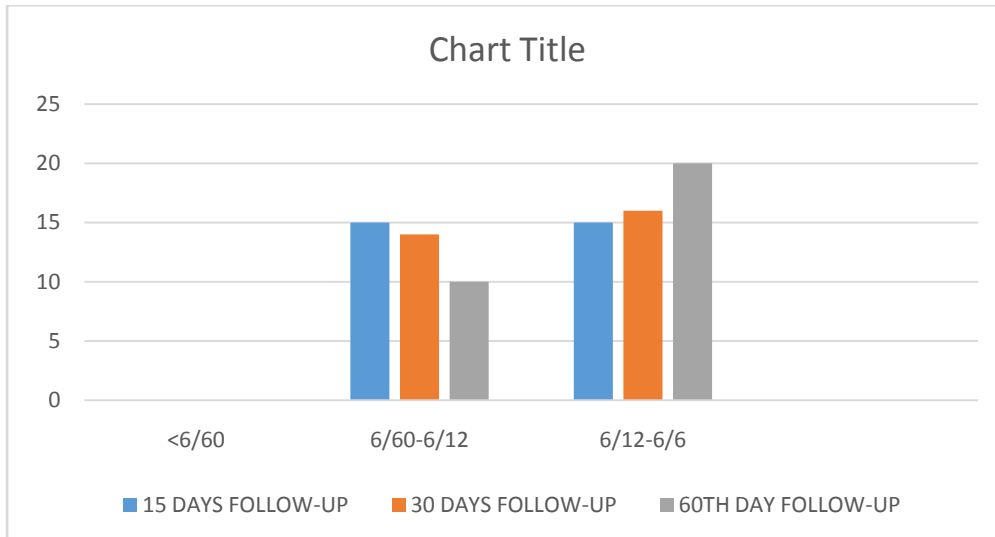
Mean post-operative with the rule astigmatism was 1.5D in 12 patients and post-operative against the rule astigmatism was 1.2D in 18 patients

Mean age of the patients who were operated was 56 years.

Visual outcome at 2 months follow-up was 6/12 and better in 20 patients (66.6%)

No vitreous loss, scleral necrosis, indolent corneal ulcer, or shallow anterior chamber was observed in cataract surgery with this combined procedure during the 2 months follow-up.





V. Discussion

The visual recovery in the combined pterygium and cataract procedure showed that 20 of 30 patients (63%) had 6/12 vision or better, 2 months postoperatively. High recurrence of pterygium is may be due to bare sclera technique. It can be reduced by conjunctival autograft transplant. [4],[5],[6] The amount of astigmatism is proportional to the pulling force, which in turn is related to the length, depth, and width of the pterygium.[7]

The combined procedure did not interfere with the healing of the cataract incision and complications such as shallow anterior chamber, iris prolapse and hyphema were not noted in our study. Usually after 6 weeks-2 months of small incision cataract surgery, the patients develop 2 diopters against the rule astigmatism. However, after the combined procedure in this study in spite of the lamellar keratectomy done for pterygium excision, none of the 30 patients had astigmatism greater than 2 diopters at 2 months follow-up[3]

VI. Summary & Conclusion

In our environment pterygium occurs in most patients requiring intraocular surgery. We advocate that whenever there is no contraindication the pterygium should be removed just before the eye is opened for the intraocular operation. The simultaneous procedure is beneficial to both the hospital and the patient and makes for a better visual prognosis in patients undergoing cataract extraction.

Bibliography

- [1]. Kanski's Clinical Ophthalmology 8th edition pg no. 162-164
- [2]. Duke ES. System of Ophthalmology, vol. 8, part 1, 2nd ed. London: Henry Kimpton; 1965, pp 573-583.
- [3]. Brenden II. Simultaneous pterygium and intraocular surgery Br J Ophthalmol 1990; 265-266
- [4]. Lewallen S. Randomised trial conjunctival auto-grafting for pterygium in the tropics. Ophthalmology 1989; 96:1612-1614.
- [5]. Singh G, Wilson MR, Foster CS. Long term follow-up study of mitomycin-C eye drops as adjunctive treatment for pterygia and its comparison with conjunctival auto-graft transplantation. Cornea 1990; 9:331-334.
- [6]. Kenyon KR, Wagoner MD, Hettinger ME. Conjunctival autograft transplantation for advanced and recurrent pterygium. Ophthalmology 1985; 92:1461-1470.
- [7]. Huchbaum DR, Moskowitz SE, Wirtschafter JD: A quantitative analysis of astigmatism induced by pterygium. J Biomech 10:735-746, 1977
- [8]. Holladay JT, Lewis JW, Allison ME, et al. Pterygium as cause of post-cataract with-the-rule astigmatism. J Am Intraocular Implant Soc 1985; 2: 176-9.

Dr. Pravin Tidake "Visual Outcome Following Combined Cataract and Pterygium Surgery". IOSR Journal of Dental and Medical Sciences (IOSR-JDMS), vol. 17, no. 2, 2018, pp. 41-43.