

## Comparative evaluation of fractures of the angle region of mandible operated via extraoral approach and intraoral approach.

Dr. Samir D. Khaire<sup>1</sup>, Dr. Shameeka S. Khaire (Thopte)<sup>2</sup>

<sup>1</sup>Assistant Professor, Maxillofacial and Oral Surgeon, Department Of Dentistry, Byramjee Jeejeebhoy Government Medical College & Sassoon General Hospitals' Pune.

<sup>2</sup>Dr. Shameeka S. Khaire (Thopte), Assistant Professor In Oral Medicine, Diagnosis & Radiology, Bharati Vidyapeeth Deemed University Dental College & Hospital, Pune.

Corresponding author: Dr. Samir D. Khaire

---

**Abstract:** The incidence of injuries to the maxillofacial skeleton has shown a progressive rise owing to increase in the road traffic accidents, interpersonal violence and sports injuries. Management of these injuries warrants a comprehensive assessment and meticulous management for successful surgical outcomes. Also, concern needs to be shown for preserving the cosmetics of the patient as the injuries are in the facial region. Early restoration of the form and function of the patient will ensure early restoration to good health. This article compares the management of fractures of angle region of mandible via intraoral approach and extraoral approach.

---

Date of Submission: 21-01-2018

Date of acceptance: 07-02-2018

---

### I. Introduction

Mandible is a dense compact bone and is the only movable bone in the facial skeleton. It is the second bone to ossify in the human body, next only to the clavicle. The movements of mandible are carried out by the muscles of mastication and thus various functions are possible (for example chewing, speech, etc.). The jaw bones are specialized bones in that they are having the alveolar processes which anchor the teeth. The presence of teeth in the jaws is important for various functions like development of speech, articulation of words, mastication, aesthetics. However, the presence of teeth in the jaw bones also accounts for anatomical weakness in these bones. In most of the cases of injuries to the facial skeleton following assaults or road accidents, the fracture lines are seen to be involving the teeth and the angle region of mandible is a potential site for fracture. The angle of the mandible marks the junction of the body of mandible with the ramus. The third molars are more commonly located at this site<sup>1</sup>. Depending on several factors like the availability of space in the mandibular dental arch, the diet of the individual, environmental influences, and the eruptive pattern of teeth, most of the third molars are found to be impacted at different levels. Sometimes the third molars may be partially impacted, at other times, they may be completely impacted. The presence of a partially impacted third molar interrupts with the continuity of the superior border of mandible, which is cortical in nature, and thereby predisposes the mandible to fracture following an injury<sup>2</sup>. Isolated angle fractures may occur or they may be seen in combination with contralateral parasymphiseal fractures. The angle fractures of mandible are associated with the highest complication rates<sup>3</sup>. Fractures of the mandible are influenced by the magnitude of the impact force, direction of the force.

### II. Materials and methods

In this retrospective analysis, an attempt has been made to study the clinical improvement in function of the patients who have undergone open reduction direct internal fixation via extraoral approach and intraoral approach for treatment of fractures of the angle region of mandible and the impact on cosmesis of the patient following the two approaches. From the trauma cases treated in past 10 years, 10 representative patients were selected for the analysis; 3 patients who were treated via extraoral approach and 7 patients who were treated via intraoral approach. Of the 10 patients selected, 5 patients had isolated angle fractures, remaining 5 patients had fractures in the parasymphiseal region and angle region of mandible. Patients included in this analysis were treated under general anaesthesia (nasal endotracheal intubation). A stainless steel arch bar was fixed to the maxillary and mandibular dental arches. Maxillomandibular fixation was done prior to fixing the stainless steel miniplates. The fractures in parasymphiseal region were exposed by placing a degloving incision in mandibular buccal vestibule. The fractures in angle region of the mandible which were treated by an intraoral approach, incision was placed in the mandibular buccal vestibule extending from the anterior border of the ramus down to

the mandibular first molar region. Fractures in angle region of mandible treated by the extraoral approach were exposed by placing a submandibular incision and dissecting through the platysma down to the inferior border of mandible after incising the pterygomasseteric sling. The fractured fragments were reduced by manipulation. Due care was taken to confirm that the mandibular condyles were properly seated in the glenoid fossae. Maxillomandibular fixation was done after achieving satisfactory occlusion. In the patients treated via an extraoral approach, the implants were fixed along the inferior border of mandible. In the patients treated via an intraoral approach, the fractured fragments in the angle region of mandible were immobilized by fixing one 2mm 4 hole stainless steel plate with gap using 2mm x 8mm stainless steel screws. The miniplate fixed in the angle region of mandible were contoured to adapt to the angle region and then fixed with screws along the external oblique ridge. Fractures in the parasymphiseal region of mandible were also reduced and immobilized by fixing stainless steel miniplates with the help of screws. The wounds were irrigated with normal saline and betadine prior to closure. Patients were given parenteral antibiotics and analgesics for 3 days postoperatively and then after discharge, they had to continue oral antibiotics and analgesics for a period of 8-10 days. Patients were given instructions to have soft diet, avoid lifting heavy weights for the next few weeks, avoid crowded places and travelling long distances in the immediate postoperative period. Patients were followed up periodically for 6 weeks after which the arch bars were removed under local anaesthesia. Patients were followed up for minimum period of 1 year.

Case 1: Fracture of right angle region of mandible managed via extraoral approach. (Representative case)

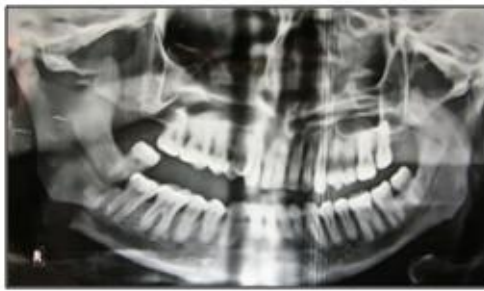

Figure 1a Orthopantomogram of a patient showing fracture of right angle region of mandible.

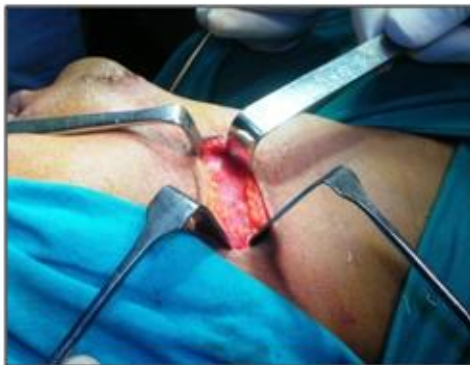

Figure 1b Submandibular dissection for exposing the angle region of mandible.

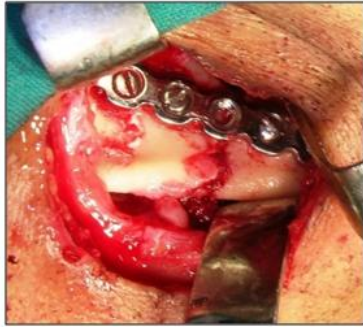

Figure 1c Fractured fragments immobilized by fixing the plate in the angle region of mandible.

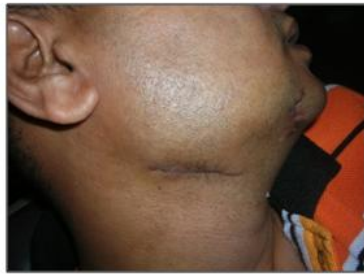

Figure 1d The scar seen in the submandibular region.

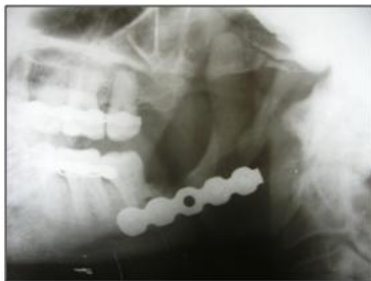


Figure 1e Right lateral oblique view showing the plate in the angle region of mandible.

Case 2: Fracture of left angle region of mandible managed via intraoral approach. (Representative case)

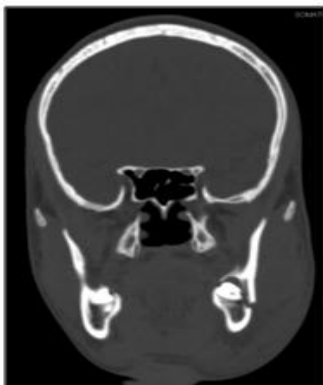

Figure 2a Coronal section of the CT scan of facial skeleton of a patient showing fracture of left angle region of mandible.

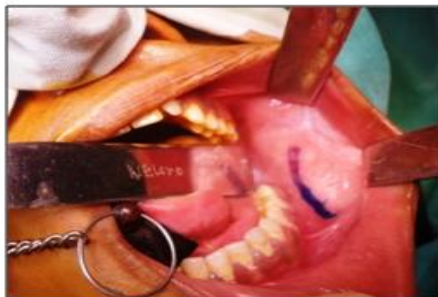

Figure 2b The site where the incision is to be placed is marked with the marking ink.

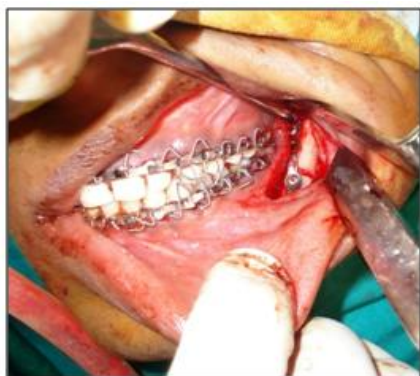

Figure 2c The fracture in left angle region of mandible immobilized by fixing the miniplate with screws.

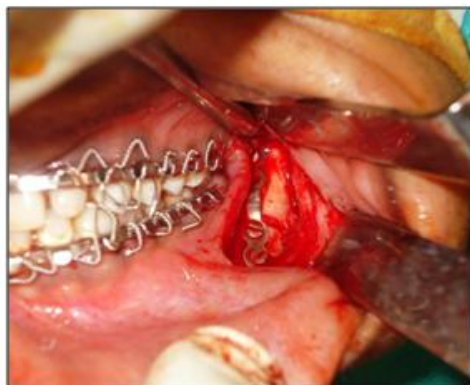

Figure 2d The plate is recontoured for adaptation along the external oblique ridge.

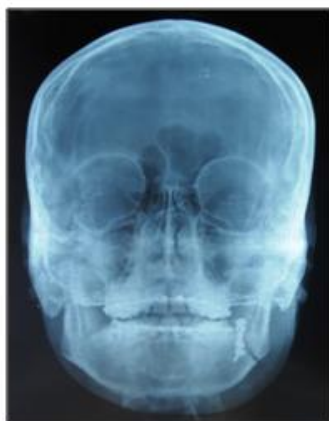

Figure 2e PA Skull view showing the plate fixed along the external oblique ridge in left angle region of mandible.

### III Observations and results

Sr. No	Factor for comparison	Fracture in angle region of mandible	
		Extraoral approach	Intraoral approach
1	Patient acceptability	Less	More
2	Surgical dissection	More complicated	Relatively easy
3	Manipulation of the fracture fragments	Relatively easy	Difficult
4	Difficulty encountered in fixing the plate	Relatively less	More
5	Postoperative pain, swelling, discomfort	More	Comparative.
6	Aesthetics	Obvious scar	Aesthetically acceptable
7	Function	Maintained	Maintained
8	Potential for displacement of fracture fragments postoperatively.	Relatively More (Plate fixed close to the inferior border of mandible)	Less (Plate fixed close to the superior border of mandible)
9	Vascularity at fracture site	More stripping of the muscles compromises vascularity	Minimal stripping of the muscles preserves vascularity at the surgical site.
10	Injury to the marginal mandibular branch of facial nerve	Neuropraxia noted for few days.	No risk of injury to the nerve.

#### **IV Discussion**

Management of the fractures of the angle of mandible is a challenging task. Fractures in this region are influenced by the muscles of mastication and this factor needs to be taken into consideration during the surgical management. The surgical skill in the management of fractures of the jaw bones lies in achieving satisfactory reduction of the fractured bones with minimal reflection of the soft tissues thereby preserving the vascularity of the affected bones. Healing of a surgical wound depends on several factors<sup>4</sup>. Gentle handling of the tissues, careful and optimum reflection of the soft tissues and adequate reduction of the fracture fragments with the hardware and a stable occlusion will allow the wound to heal better, faster and with good surgical results. As the fractures in the angle region of mandible tend to open up at the superior border during function, fixation of a miniplate at the superior border along the external oblique ridge tends to maintain good reduction of the fractured fragments<sup>5</sup>. Exposure of the fracture site by placing a degloving incision halfway along the anterior border of the ramus and extending it anteriorly upto the first molar gives good access to the surgical site. Careful reflection of the tissues ensures a clean field. The miniplate needs to be bent to ensure proper adaptation along the external oblique ridge. It is a good practice to mark the site for drilling the holes with a sterile marker. A four hole miniplate with two holes on either side of the fracture line ensures rigid fixation. When drilling holes for miniplate fixation, it is very important to have control over the direction of the drill bit to ensure good osseointegration of the screws postoperatively. The natural lateral flare of the ramus from the body of the mandible should be taken into consideration when adapting the miniplate. The drill bit should be directed laterally when drilling holes in the proximal fracture fragment and medially when drilling holes in the distal fracture fragment. When the screws are being tightened, it is necessary to have a good counterforce applied to ensure good reduction of the fracture fragment, to maintain the occlusion achieved after maxillomandibular fixation and to prevent undue stress on the condylar region. The mandibular third molars in the fracture line that are healthy can be retained as they help to maintain stability at the fracture site. Infected third molars should be considered for removal intraoperatively.

In the intraoral approach for management of the mandibular angle fractures, the patient may experience trismus for few days. But as the oedema reduces and wound healing progresses, the interincisal opening improves gradually.

Management of facial fractures demands careful assessment of the case and due care in the management. However, the success of surgical management depends upon patient co-operation as well. It is very important that the fracture wound is not loaded under the masticatory forces to ensure uneventful healing. Patient needs to be informed to take soft diet for a few weeks. Protein supplements can be prescribed for the patient. Patient should be informed about maintenance of good oral hygiene. The sutured wound needs to be kept clean, also, with the arch bars in position for a period of about 4-6 weeks postoperatively; regular brushing after meals will ensure good periodontal health. Patient should be informed to avoid lifting heavy weights or strenuous exercises as this can also load the fracture site with undue stresses.

#### **V. Conclusion**

Intraoral approach for the management of the fracture of mandibular angle will give good cosmetic results as the extraoral facial scar is avoided. Recovery of the patient is faster as the tissue handling is kept to a minimum. Also, surgical complications are kept to a minimum. However, displacement of the fractured fragments can be a deciding factor for the surgical approach to angle fractures of mandible.

#### **References**

- [1]. A Review of Mandibular Angle Fractures; Ramiro Perez, John C. Oeltjen and Seth R. Thaller.
- [2]. Craniomaxillofac Trauma Reconstr. 2011 Jun; 4(2): 69–72.
- [3]. Mandibular third molars as a risk factor for angle fractures: a retrospective study; K. Rajkumar, Sinha Ramen, Roy Chowdhury and P. K. Chattopadhyay
- [4]. J Maxillofac Oral Surg. 2009 Sep; 8(3): 237–240
- [5]. Management of Mandibular Angle Fracture; Daniel Cameron Braasch, A. Omar Abubaker,
- [6]. Oral and Maxillofacial Surgery Clinics November 2013 Volume 25, Issue 4, Pages 591–600
- [7]. Wound Healing Problems in the Mouth; Constantinus Politis, Joseph Schoenaers, Reinhilde Jacobs and Jimoh O. Agbaje
- [8]. Front Physiol. 2016; 7: 507
- [9]. Versatility of a single upper border miniplate to treat mandibular angle fractures: A clinical study; P. Satish Kumaran and Lalitha Thambiah
- [10]. Ann Maxillofac Surg. 2011 Jul-Dec; 1(2): 160–165.

Dr. Samir D. Khaire "Comparative evaluation of fractures of the angle region of mandible operated via extraoral approach and intraoral approach." IOSR Journal of Dental and Medical Sciences (IOSR-JDMS), vol. 17, no. 2, 2018, pp. 20-24.