

Histopathological Study of Lesions in Nasal Cavity & Nasopharynx: An Experience at Tertiary Care Hospital

Dr.V.Manikanta¹, Dr.P.Babu.Ukkadala², Dr.T.Bharath³

¹(Assistant Professor, Department of pathology, Katuri Medical College, Chinakondrupadu, Guntur, A.P. India)

²(Assistant Professor, Department of pathology, RVS IMS, Chittoor, A.P. India)

³(Assistant Professor, Department of pathology, Nimra institute of medical sciences, Ibrahimpatnam, Vijayawada, A.P. India)

Corresponding author: Dr. P.Babu.Ukkadala

Abstract

Background: A variety of non-neoplastic and neoplastic lesions of nasal cavity and nasopharynx are commonly encountered in routine clinical practice. The main aim of this study was to study of spectrum of histopathological lesions of nasal cavity, paranasal sinuses and nasopharynx in a tertiary care hospital, over the period of two years.

Material & Methods: This is a descriptive, cross sectional study over a period of 2 years, from September 2014 to August 2016. A total 235 biopsies, received to the department of pathology at Dr.PSIMS & RF, Chinnaoutpalli, india., presented as mass lesions in the nasal cavity and nasopharynx. After fixation, processing and H & E staining, histopathological diagnosis was made. This study was approved by the institutional ethical committee.

Results: Total 235 biopsies were analyzed, and broadly categorized into non-neoplastic and neoplastic lesions. Most of the lesions presented at 2nd and 3rd decade of life with male preponderance. Inflammatory polyp was most common non-neoplastic lesion. Among the neoplastic lesions, inverted papilloma was the most common benign lesion and nasopharyngeal carcinoma was the most common malignant lesion observed.

Conclusion: Complete clinical, radiological and histopathological correlation helps to categorize these sinonasal lesions into various non-neoplastic and neoplastic types, but histopathological examination is gold standard procedure providing a confirmatory diagnosis and ambiguous diagnosis were confirmed by immunohistochemistry.

Keywords: polyp, inverted papilloma, nasopharyngeal carcinoma, histopathological examination.

Date of Submission: 09-02-2018

Date of acceptance: 24-02-2018

I. Introduction

Nose is the most prominent part of face, with great aesthetic significance and functional importance. Variety of Non-neoplastic and neoplastic lesions commonly encountered in routine clinical practice and present as mass lesions⁽¹⁾. This was the common finding in the all age groups. Common presenting symptoms was nasal blockade, nasal discharge, epistaxis, facial swelling, orbital and ear symptoms⁽²⁾. Although, clinical complaint of a mass in the nose seems to be a simple problem but it gives think of large number of differential diagnosis in the mind of treating physician and diagnosing pathologists. These lesions can be ranged from simple nasal polyps to infective polypoidal granulomatous lesions to malignant lesions. Nasal polyps are the most common cause of nasal obstruction⁽³⁾. Their exact pathogenesis is unknown but they have associated with allergy, asthma, infections and aspirin sensitivity⁽³⁾. Benign lesions of sinonasal region are common and lack of appreciation of these lesions can lead to radical surgeries. They have long clinical history with frequent local recurrence and thus relatively significant morbidity. Malignant lesions in nasal cavity, paranasal sinuses and nasopharynx accounts for not more than 3% of head and neck malignancies and less than 1% of all the malignant tumors. Geographically, they have tendency for Africans, Japanese and Arabians and are rarely seen in Americans and Western Europeans⁽⁴⁾. Due to varieties of histopathological types and grades of malignancies, it is very important to study their clinical and pathological aspects. Coupled with radiological techniques, histopathology has become indispensable in the timely diagnosis and treatment of these lesions^(5,6). The aim of this study was to categorize these lesions into non neoplastic and neoplastic and to study their clinical and histopathological patterns.

II. Materials And Methods

Present study was a descriptive, cross sectional study conducted over a period of 2 years from September 2014 to August 2016, referred to department of pathology at Dr.PSIMS & RF, chinnaoutpalli, Andhra Pradesh, India. A total 235 biopsies were analyzed. Demographic data regarding age, sex, chief complaints, clinical examination, radiological investigations was retrieved from histopathology department and OPD record. All received biopsies were examined, fixed with 10% buffered formalin. Processed and H & E staining for microscopic examination was done. Immunohistochemistry was used wherever required. Final diagnosis was made, based on morphological examination of lesions into inflammatory, benign and malignant. Data tabulated and analyzed to know relative frequencies of lesion presentation.

III. Results

In this present study, age of the patient ranged from less than 10 years to more than 60 years. Majority of patients with sinonasal mass were found that 31-40 years(58.4%) of age, and showing male preponderance. In this study, it was observed that non-neoplastic lesions were more common than the malignant lesions accounting for 219(93.2%) cases and 9(3.82%) cases respectively and 7(2.98%) cases were benign.

Non-neoplastic lesions comprises of inflammatory polyps (75.8%), allergic polyps (20.1%), and fungal polyps (4.1%). These lesions are commonly presented that the age group of 31-40 years. Inflammatory polyp was the most common lesion followed by allergic polyp. Males were preponderance than the female with M:F ratio 1.26:1.

In the present study benign lesions were observed that inverted papilloma (42.8%) was the most prevalent lesions followed by lobular capillary hemangioma(28.6%), angiofibroma(14.3%) and sinonasal papilloma (14.3%). Nasopharyngeal carcinoma is the most common malignant lesion (33.3%) followed by low grade nasopharyngeal adenocarcinoma (22.2%), undifferentiated nasopharyngeal carcinoma (11.1%), poorly differentiated nasopharyngeal adenocarcinoma (11.1%), Esthesio neuroblastoma (11.1%) and neuroectodermal tumor(11.1%). In this present study malignant lesions were found that later age of 51-60 years. Common presenting symptoms of nasal and nasopharyngeal lesions were nasal blockade, nasal discharge, epistaxis and facial swelling.

IV. Discussion

Heterogenous group of lesions with wide range of histomorphological variants are seen in the biopsies from masses of nasal cavity, paranasal air sinuses. It is quite difficult to differentiate clinically and they are routinely diagnosed as nasal polyp⁽⁷⁾.

In our study it was observed that males (55.3%) were predominantly affected than females(44.7%). Similar study done by Chan SH et al⁽⁸⁾ also showed that males (68.29%) outnumbered the females (31.71%).

Regarding age, our study revealed 2nd and 3rd decade of life most vulnerable period for sinonasal lesions. It is consistent with finding observed by Bakari et al⁽⁹⁾ and Zafar et al⁽¹⁰⁾ Malignant lesions was seen in 6th & 7th decades and it is in concordance with the study of Patel et al⁽¹¹⁾

Total number of non-neoplastic lesions were 93.2% found in our study, Similarly a low proportion of non-neoplastic lesions (89%) are also reported in the study by Zafar et al⁽¹⁰⁾. Nasal polyps are commonest lesion of nasal cavity. Exact pathogenesis is not known but they have strong association with allergy, asthma, aspirin sensitivity.

Among sinonasal lesion the prevalence of inflammatory nasal polyp was 75.8%. This was found to be less in studies done by Tondon et al⁽⁵⁾ and Dasgupta et al. (62.5%)⁽⁷⁾. Inverted papilloma commonly occurring benign nasal lesion forming 42.8% of all benign neoplastic lesion. These findings are also similar to other study conducted by Humayun et al (33.3%).⁽¹³⁾ we have reported other benign lesions are lobular capillary hemangioma (25%), is the second most common benign lesions. This findings were similar to other study done by Modh et al⁽¹²⁾ showing 19.4% of prevalence. All these lesions presented same clinical feature as that, bleeding nasal polyp.

Malignant sinonasal lesions were reported in this present study was 3.82% of all cases of nasal lesions. Nasopharyngeal carcinoma (33.3%) commonest lesion, it is comparable with the findings of Modh et al⁽¹²⁾ and Panchal et al⁽¹⁴⁾. These lesions were common in 6th and 7th decades of life, this finding was similar with study done by Ghosh.⁽¹⁵⁾

V. Conclusion

Sinonasal lesions shows diversity of histological types. Most common age group of presentation was 2nd and 3rd decade of life with male preponderance. These lesions were commonly presented as polyp mass and presenting symptom was nasal obstruction and epistaxis. Clinical and radiological examination helps only presumptive diagnosis but histomorphological study was the gold standard procedure for confirmation.

Conflict of interest: None to declare

Source of funding: Nil.

Bibliography

- [1]. Zafar U, Khan N, Afroz N, Hasan SA. Clinicopathological study of non-neoplastic lesions of nasal cavity and paranasal sinuses. Indian J PatholMicrobiol.2008;51:26-29.
- [2]. Somani S, Kamble P, Khadkear S. Mischievous presentation of nasal masses in rural areas. Asian J Ear Nose Throat. 2004;2:9-17.
- [3]. Hedman J, Kaprio J, Poussa T, et al. Prevalence of asthma, aspirin intolerance, nasal polyposis and chronic obstructive pulmonary disease in a populationbased study. Int J Epidemiol.1999;28:717-22.
- [4]. Settupane GA. Epidemiology of nasal polyps. Allergy Asthma Proc. 1996;17:231-36.
- [5]. Tondon PL, Gulati J, Mehta N. Histological study of polypoidal lesions in the nasal cavity. Indian J Otolaryngol. 1971;13:3-11.
- [6]. Khan N, Zafar U, Afroz N, Ahmad SS, Hafan SA. Masses of Nasal cavity, Paranasal sinuses and Nasopharynx. A clinicopathological study. Indian J otolaryngol Head Neck Surg. 2006;58:233-37
- [7]. Dasgupta A, Ghosh RN, Mukherjee C. Nasal polyps- Histopathologic spectrum. Indian J Otolaryngol Head Neck Surg.1997;49:32-36.
- [8]. Chan SH, Day NE, Kunaratnam N, Chia KB, Simons MJ. HLA and nasopharyngeal carcinoma in Chinese. A further study. Int.J.Cancer 1983;32:171-176.
- [9]. Bakari A, Afolabi QA, Adoga AA, et al. Clinicopathological profile of sino nasal masses: An experience in National Ear Care Center Kaduna, Nigeria. BMC Res Notes. 2010;3:186.
- [10]. Zafar U, Khan N, Afroz N, Hasan SA. Clinicopathological study of non-neoplastic lesions of nasal cavity and paranasal sinuses. Ind.J. Pathol Microbio. 2008;51:26-29.
- [11]. Patel SV, Katakwar BP. Clinicopathological study of benign and malignant lesions of nasal cavity, paransal sinuses and nasopharynx: A prospective study. Orissa J Otolaryngol Head Neck Surg. 2009;3: 11-15.
- [12]. Modh SK, Delwadia KN, Gonsai RN. Histopathological spectrum of sinonasal masses- A study of 162 cases. Ind J Cur Res Rev. 2013;5(03):83-91.
- [13]. Humayun AHM, Zahurul Huq AHM, Ahmed SMT, et al. Clinicopathological study of sinonasal masses. Bangladesh J Otorhinolaryngol.2010;16:15-22.
- [14]. Panchal L, Vaideeswar P, et al. Sinonasal epithelial tumors: A pathological study of 69 cases.J Postgrad Med.2005;1(1):30-34.
- [15]. Ghosh A, Bhattacharya K. Nasal and nasopharyngeal growth- A 10 year survey. J Ind Med Ass. 1966;47:13.

Table No:1 Distribution of lesions according to age

Age(years)	Non-neoplastic (93.2%)	Neoplastic (6.8%)	
		Benign (2.98%)	Malignant(3.82%)
<10 years	--	--	1
10-20	8	1	1
21-30	59	--	--
31-40	128	6	1
41-50	15	--	1
51-60	6	--	3
>60	3	--	2
Total	219	7	9

Table no:2 Distribution of lesions according to sex

Lesion type	Male	Female	M:F ratio	Total
Non-neoplastic	122	97	1.26:1	219 (93.2%)
Benign	1	6	1:6	7 (2.98%)
Malignant	7	2	3.5:1	9 (3.82%)

Table no:3 Distribution of non-neoplastic sinonasal lesions

Non-neoplastic lesion	No of cases(%)
Inflammatory polyp	166 (75.8%)
Allergic polyp	44 (20.1%)
Fungal polyp	9(4.1%)
Total	219(93.2%)

Table no:4 Distribution of benign sinonasal lesions

Benign lesion	No of cases(%)
Inverted papilloma	3(42.8%)
Capillary hemangioma	2(28.6%)
Angiofibroma	1(14.3%)
Sinonasal papilloma	1(14.3%)
Total	7 (100%)

Table no 5: Distribution of malignant sinonasal lesions

Malignant lesion	No of cases (%)
Nasopharyngeal carcinoma	3(33.3%)
Undifferentiated nasopharyngeal carcinoma	1(11.1%)
Low grade nasopharyngeal adenocarcinoma	2(22.2%)
Poor differentiated nasopharyngeal adenocarcinoma	1(11.1%)
Esthesio neuroblastoma	1(11.1%)
Neuroectodermal tumor	1(11.1%)
Total	9(100%)

Fig no.1 Nasal polyp (H & E 10x)

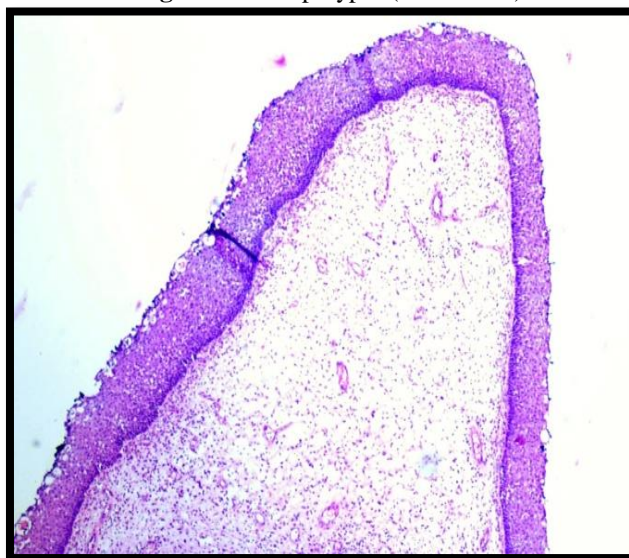


Fig no.2 Lobular capillary haemangioma (H & E 10x)

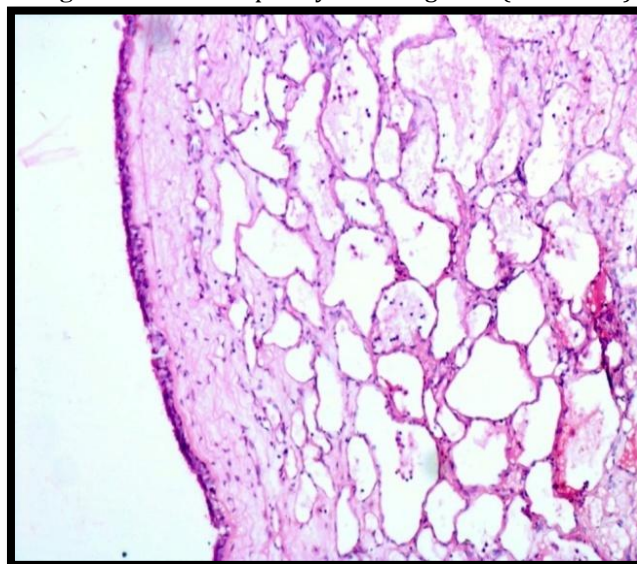


Fig no.3 Inverted papilloma (H & E 40x)

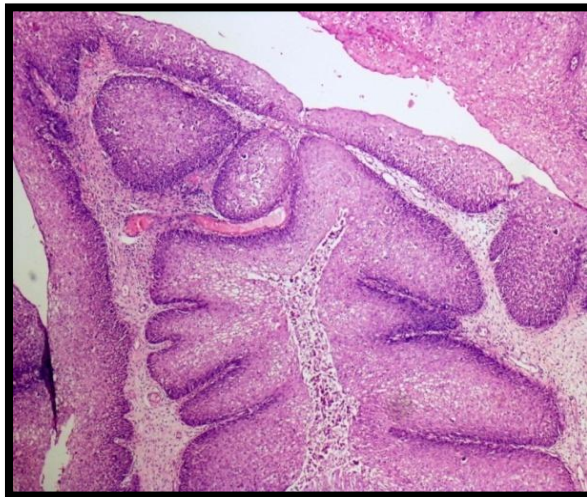

Fig no.4 Nasopharyngeal carcinoma Regaud's type (H & E 40x)

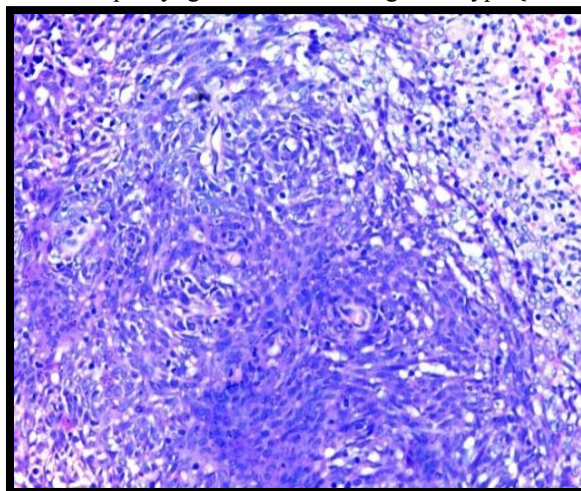
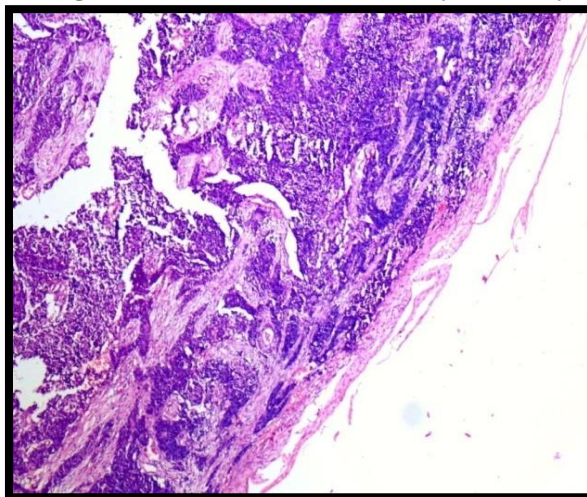


Fig no.5 Esthesio neuroblastoma (H & E 10x)



Dr.V.Manikanta "Histopathological Study of Lesions in Nasal Cavity & Nasopharynx: An Experience at Tertiary Care Hospital." . "IOSR Journal of Dental and Medical Sciences (IOSR-JDMS), Volume 17, Issue 2 (2018), PP 47-51.