

To repost a case of ocular toxoplasmosis

Dr. Neelam Kalbande¹, Dr. Pravin Tidake², Dr. Rohit Agrawal³

Corresponding Author: Dr. Neelam Kalbande

Abstract: A 23 year old female, came to ophthalmology OPD, Acharya VinobaBhave Rural Hospital, Sawangi, Wardhawith chief complains of diminution of vision in right eye since 6 months. On examination, right eye visual acuity was counting fingers 3 metres with no improvement with pinhole, left eye visual acuity was 6/6. Slit examination of the anterior segment was normal. Fundus examination revealed single large healed excavated chorioretinal scar, yellow in colour involving the macula, with punched out edges with chorioretinal atrophy with visible choroidal blood vessels suggestive of healed toxoplasmicchorioretinitis.

Date of Submission: 27-11-2018

Date of acceptance: 08-12-2018

I. Introduction

Toxoplasmosis gondii is an intracellular parasite with hosts in mammals and birds. Humans can be infected by ingesting the eggs or cysts of toxoplasma. After infection, the parasite may be passed across the placenta from a pregnant mother to her fetus causing congenital toxoplasma. The prevalence of T. gondii infection varies widely across geographic locations. Patients with ocular toxoplasmosis most commonly present with chief complaints of diminution of vision, floaters, ocular discomfort and sometimes scars can be found on routine examination.

II. Objective

We want to describe a clinical presentation and discuss a case typical of ocular toxoplasmosis

III. Materials and method

This is a retrospective case report of a 23 year old female who presented with complaints of decreased vision in her right eye since 6 months. She also complained of floaters in right eye since 6 months.

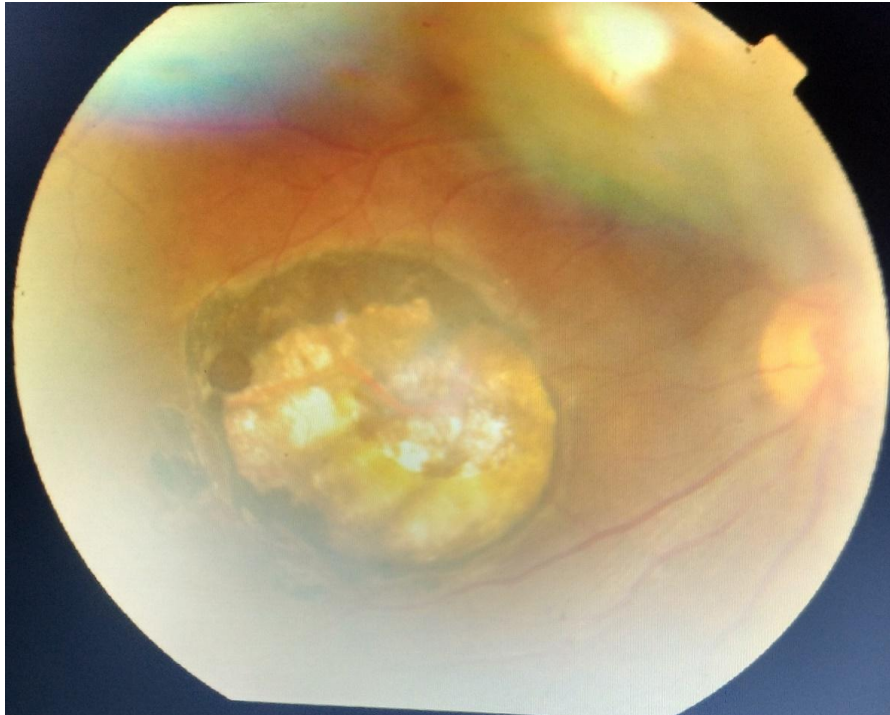
Ocular examination-

- BCVA- Right eye- finger counting 3 metres with no improvement on pinhole Left eye- 6/9
- Pupil- NSRL Both eyes
- Fundus examination-

Right eye-single large healed excavated chorioretinal scar, yellow in colour involving the macula, with punched out edges with chorioretinal atrophy with visible choroidal blood vessels suggestive of healed toxoplasmicchorioretinitis

Left eye- within normal limits

As the patient presented with absence of active chorioretinal focus, suggesting inactive phase of disease and hence no treatment was given.



IV. Discussion

Toxoplasma gondii is an ubiquitous obligate intracellular parasite, which infects both humans and animals(1). Approximately one-third of human population worldwide is supposed to be infected with *T. gondii*(2).The prevalence of toxoplasmosis vary among different geographic regions with different toxoplasmic environments(3). Cats are definitive host whereas human become accidentally infected when they ingest oocytes in fecal matter of cats.Once infected, the replicating form of the parasite, or tachyzoite, may be passed across the placenta from a pregnant mother to her fetus, resulting in a congenital form of the disease. After humans are infected, active form of the parasite i.e.tachyzoite is passed across placenta from infected mother to fetus which results in congenital toxoplasmosis.Diagnosis of ocular toxoplasmosis is based largely on the clinical examination. Serologic testing for toxoplasmosis, polymerase chain reaction analysis of aqueous humor and vitreous can prove the diagnosis.Ocular toxoplasmosis usually is a self-limiting condition in immunocompetent individuals. Treatment is decided based on the location of the lesion and severity of the inflammation. Classic treatment of ocular toxoplasmosis ispyrimethamine, sulfadiazine, and prednisone for 4 to 12 weeks(4). Prognosis depends on location and severity of infection. Visual outcome is poor if lesion is involving macula. According to a study, ocular toxoplasmosis can reactivate in about 79% of cases(5).

V. Conclusion

Several eye diseases may go undetected during routine examination. A detailed history and full ocular assessment including routine fundus examination are essential to derive to a correct diagnosis. Ocular toxoplasmosis is a potentially blinding condition with possible recurrence. Patient education and regular follow-up are useful to reduce ocular morbidity.

Bibliography

- [1]. Holland GN. Ocular toxoplasmosis: a global reassessment. Part I: epidemiology and course of disease. *Am J Ophthalmol.* 2003 Dec;136(6):973–88.
- [2]. Subauste CS, Ajzenberg D, Kijlstra A. Review of the series “Disease of the year 2011: toxoplasmosis” pathophysiology of toxoplasmosis. *OculImmunolInflamm.* 2011 Oct;19(5):297–306.
- [3]. Dodds EM. Toxoplasmosis. *CurrOpinOphthalmol.* 2006 Dec;17(6):557.
- [4]. Rothova A, Meenken C, Buitenhuis HJ, Brinkman CJ, Baarsma GS, Boen-Tan TN, et al. Therapy for ocular toxoplasmosis. *Am J Ophthalmol.* 1993 Apr 15;115(4):517–23.
- [5]. Bosch-Driessen LEH, Berendschot TTJM, Ongkosuwito JV, Rothova A. Ocular toxoplasmosis: clinical features and prognosis of 154 patients. *Ophthalmology.* 2002 May;109(5):869–78.

Dr.Neelam Kalbande. “To repost a case of ocular toxoplasmosis.” *IOSR Journal of Dental and Medical Sciences (IOSR-JDMS)*, vol. 17, no. 12, 2018, pp 63-64.