

## Management of a furcal perforation with Mineral Trioxide Aggregate: A case report

Roshan Sadiya<sup>1</sup>, Shashikala K<sup>2</sup>, B.S Keshava Prasad<sup>3</sup>, H Murali Rao<sup>4</sup>

(<sup>1</sup>Post Graduate Student,<sup>2</sup>Professor and Vice Principal,<sup>3</sup>Professor and Head of the Department,<sup>4</sup> Professor, Department of Conservative Dentistry and Endodontics, D.A.P.M R.V Dental College, Bangalore)

Corresponding Author: Roshan Sadiya

---

**Abstract :** Mineral trioxide aggregate is a versatile material with numerous clinical applications such as a root end filling material, in cases of pulp capping, pulpotomy, apexification, apexogenesis, etc due to its inherent superior properties like the biocompatibility and sealing ability. Perforation of the furcation area is an untoward incident that may occur during root canal treatment. Poor prognosis of furcal perforations may be attributed to the bacterial leakage or lack of biocompatibility of repair materials. Based on the recent studies conducted on the physical and biologic properties of MTA, this material may be considered suitable for sealing the communication between the pulp chamber and the underlying periodontal tissue.

The current article describes the clinical management of a furcal perforation with MTA, highlighting the long term clinical success exhibited by the material.

**Keywords:** Furcal Perforation, MTA

---

Date of Submission: 27-11-2018

Date of acceptance: 08-12-2018

---

### I. Introduction

The dental pulp communicates with the periodontium via the apical foramen and lateral canals.<sup>1</sup> Leakage of irritants from the oral cavity into the periapical tissues may result in endodontic failures.<sup>2</sup> The development of mineral trioxide aggregate (MTA) by Mahmoud Torabinejad at the Loma Linda University, California, U.S.A in 1993 resulted in a material that possessed the ideal characteristics of sealing the pathways of communication between the root canal system and the surrounding tissues.<sup>2,3</sup>

MTA was commercially introduced as ProRoot MTA in 1998 which belongs to a group of materials known as calcium silicate cements. It is a bioactive material having exceptional biocompatibility and antimicrobial properties with considerable sealing properties even in the presence of moisture. However, its drawbacks include a long setting time, difficult handling properties and dentin discoloration.<sup>4</sup>

Due to its inherent improved properties MTA has been suggested to have an extended use in the field of conservative dentistry and endodontics in various procedures such as root end filling, pulp capping, pulpotomy, apexogenesis, apexification, apical barrier formation, repair of root perforations and resorptive defects and as a root canal filling material.<sup>2</sup>

According to the Glossary of Endodontic terms, perforation is defined as a mechanical or pathological communication between the root canal system and the external tooth surface. Root perforations may occur pathologically due to caries or by a resorptive process or iatrogenically as a complication during or after root canal treatment.<sup>5</sup> Perforations of teeth constitute 9.6% of endodontic failures. Repair of furcation and lateral perforations can be achieved by a surgical approach or a nonsurgical approach by sealing the defect using materials like calcium hydroxide, glass ionomer cement and MTA.<sup>6</sup>

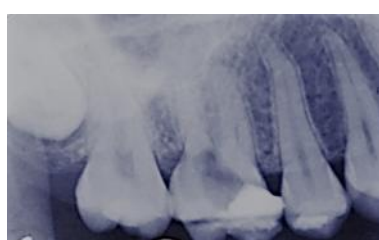This paper highlights a case report pertaining to the management of a furcal perforation using MTA.

### II. Case Reports

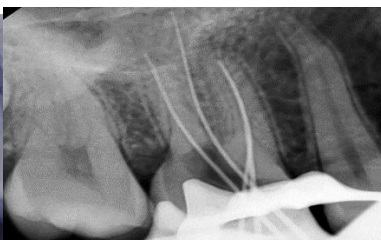
#### Case I:

A 26 year old female patient with the history of pain in the maxillary right first molar, for which emergency root canal treatment was initiated by a local dentist was referred to the Department of Conservative Dentistry and Endodontics, D.A.P.M RV Dental College and Hospital for further treatment. On clinical examination, an intact temporary restoration was noted in relation to 16. Radiographic examination revealed the presence of a perforation involving the floor of the pulp chamber and no periapical radiolucency was noted. The treatment plan thus formulated included the root canal treatment of 16 followed by the perforation repair scheduled for the same appointment as the patient was asymptomatic when she reported to the hospital.

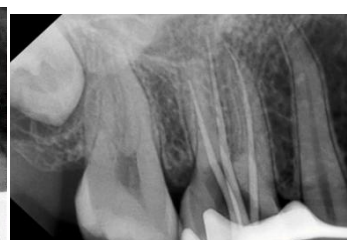After rubber dam application and removal of the temporary restoration, profuse bleeding was noted in the floor of the pulp chamber. The perforation site was rinsed thoroughly with diluted NaOCl. The mesiobuccal canal and palatal canals were located however due to the calcified nature and approximate location to the perforation site, it was difficult to locate the distobuccal canal. After negotiation with a stainless steel #10 K-file and RC Prep near the buccal aspect of the perforation site, the distobuccal canal was located. The working length was determined radiographically followed by which the canals were cleaned and shaped as per the standard procedure using NeoEndo rotary file system up to #25, 0.6 and obturated by lateral condensation technique. The furcal perforation was irrigated with saline solution and 2% chlorhexidine. MTA was dispensed and mixed according to the manufacturer's instructions and was placed in the floor of the pulp chamber with an amalgam carrier. The MTA was packed with a moist cotton pellet to achieve good adaptability. A radiograph was taken to ensure proper placement. A moist cotton pellet was placed on the MTA to provide adequate conditions for setting and the tooth was temporized with Cavit. The patient was recalled after 1 week for a permanent coronal restoration and as she was asymptomatic, placement of a crown was planned for the following appointment which was scheduled within a week. The 6 months follow up radiograph showed adequate sealing of the perforation area with no periapical rarefactions.



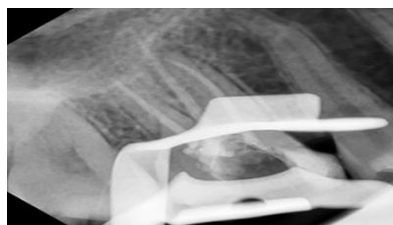
**Fig 1:** Pre-operative radiograph



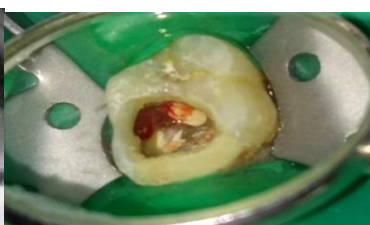**Fig 2:** Working length radiograph



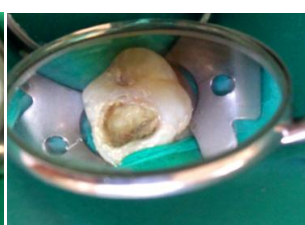
**Fig 3:** Master cone radiograph



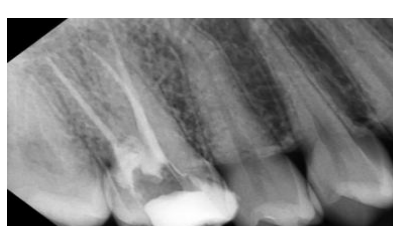**Fig 4:** Obturation radiograph



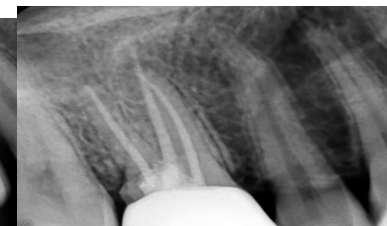**Fig 5:** Perforation in the floor of the pulp chamber



**Fig 6:** MTA placement



**Fig 7:** Radiograph following MTA placement



**Fig 8:** 6 months follow-up radiograph

### **III. Discussion**

It has been hypothesized that the success of a perforation repair procedure include the location of the perforation, the size of the perforation, time lapse between the occurrence of the perforation and repair, the ability of the material to seal the perforation site and the biocompatibility of the material.<sup>7</sup>

Due to the closer proximity to the oral environment and increased potential to cause periodontal defects, furcal perforations are reported to have a diminished prognosis.<sup>8</sup> A furcal perforation causes damage to the periodontal ligament with subsequent inflammatory reaction. Exposure of the perforated region to bacterial contaminants from the oral environment for a substantial period results in a downward proliferation of the epithelium and consequently leading to the breakdown of bone and ultimately tooth loss.<sup>8,9</sup>

The lapse of time between sealing a perforation and its inception plays a critical role in determining the prognosis of periodontal repair.<sup>10</sup> Literature advocates the immediate closure of the communication between the

periodontal tissues and root canal system to promote superior healing potential.<sup>10</sup> However favourable prognosis was obtained in delayed repair in the presence of aseptic conditions which is in accordance with a study done wherein a good short term clinical outcome was reported when the time elapsed from the inception of the perforation to the repair of the defect did not exceed 6 months.<sup>10,11</sup>

The ultimate goal in the management of perforations is to arrest the inflammatory process and subsequent loss of tissue attachment by preserving healthy tissues at the site of perforation. Historically, the repair materials were not able to achieve this regenerative process until the development of MTA.<sup>7</sup>

MTA is a powder with fine hydrophilic particles of tricalcium silicate, tricalcium aluminate, tricalcium oxide and silicate oxide which forms a colloidal gel on hydration that solidifies in approximately 3 hours.<sup>8</sup>

MTA sets in the presence of moisture and blood does not affect its sealing ability.<sup>5</sup> A study done by Sluyk et al demonstrated that the presence of moisture in perforations during placement of MTA increased its adaptation to perforation walls and for this reason it was suggested that MTA did not require the use of an internal matrix when sealing furcal perforations.<sup>12,13</sup>

Studies involving the use of MTA to repair perforations in animal models have shown minimal or no inflammation and demonstrated cementum repair at the material interface. The high surface pH of MTA facilitates repair and hard tissue formation. Calcium oxide in MTA reacts with the tissue fluids to form calcium hydroxide which encourages hard tissue deposition which is accordance to studies done by Holland et al.<sup>14</sup>

In the case report presented, the management of furcal perforation with MTA highlights the long term clinical success exhibited by the material which has been eminently reported in literature and thus its usage as a perforation repair material could be advocated.

#### **IV. Conclusion**

Among the various endodontic materials available MTA has shown superior properties such as good sealing ability, insolubility in tissue fluids, dimensional stability, non-resorbable nature, excellent biocompatibility with a certain degree of bioactivity. Hence, MTA could be considered as an alternative to calcium hydroxide in the treatment of open apices and perforation repair.

#### **References**

- [1]. Torabinejad M, Chivian N. Clinical applications of mineral trioxide aggregate. *Journal of endodontics*. 1999 Mar 1;25(3):197-205.
- [2]. Malhotra N, Agarwal A, Mala K. Mineral trioxide aggregate: a review of physical properties. *Compendium of continuing education in dentistry* (Jamesburg, NJ: 1995). 2013 Feb;34(2):e25-32.
- [3]. Macwan C, Deshpande A. Mineral trioxide aggregate (MTA) in dentistry: A review of literature. *Journal of Oral Research and Review*. 2014 Jul 1;6(2):71.
- [4]. Ree MH, Schwartz RS. Long-term Success of Nonvital, Immature Permanent Incisors Treated With a Mineral Trioxide Aggregate Plug and Adhesive Restorations: A Case Series from a Private Endodontic Practice. *Journal of endodontics*. 2017 Aug 1;43(8):1370-7.
- [5]. Clauder T, SHIN SJ. Repair of perforations with MTA: clinical applications and mechanisms of action. *Endodontic Topics*. 2006 Nov;15(1):32-55.
- [6]. Tsai YL, Ian WH, Jeng JH. Treatment of pulp floor and stripping perforation by mineral trioxide aggregate. *Journal of the Formosan Medical Association*. 2006 Jan 1;105(6):522-6.
- [7]. Elumalai D, Kapoor B, Tewrai R, Mishra S. Comparison of mineral trioxide aggregate and biodentine for management of open apices. *Journal of Interdisciplinary Dentistry*. 2015 Sep 1;5(3):131-.
- [8]. Main C, Mirzayan N, Shabahang S, Torabinejad M. Repair of root perforations using mineral trioxide aggregate: a long-term study. *Journal of Endodontics*. 2004 Feb 1;30(2):80-3.
- [9]. Torabinejad M, Hong CU, McDonald F, Ford TP. Physical and chemical properties of a new root-end filling material. *Journal of endodontics*. 1995 Jul 1;21(7):349-53.
- [10]. Seltzer S, Sinai I, August D. Periodontal effects of root perforations before and during endodontic procedures. *Journal of dental research*. 1970 Feb;49(2):332-9.
- [11]. Ingle J, Bakland L, Baumgartner J, Ingle J. *Ingle's endodontics* 6. Hamilton, Ontario: BC Decker; 2008.
- [12]. Unal GC, Maden M, Isidan T. Repair of furcal iatrogenic perforation with mineral trioxide aggregate: two years follow-up of two cases. *European journal of dentistry*. 2010 Oct;4(4):475.
- [13]. Arens DE, Torabinejad M. Repair of furcal perforations with mineral trioxide aggregate: two case reports. *Oral Surgery, Oral Medicine, Oral Pathology, Oral Radiology and Endodontics*. 1996 Jul 1;82(1):84-8.
- [14]. Sluyk SR, Moon PC, Hartwell GR. Evaluation of setting properties and retention characteristics of mineral trioxide aggregate when used as a furcation perforation repair material. *Journal of Endodontics*. 1998 Nov 1;24(11):768-71.

Roshan Sadiya. "Management of a furcal perforation with Mineral Trioxide Aggregate: A case report." *IOSR Journal of Dental and Medical Sciences (IOSR-JDMS)*, vol. 17, no. 12, 2018, pp 20-22.