

## Wandering Appendix in inguinal hernia sac: Amyand's hernia, a case report

Arun Singh, Sunil Kumar Singh

Department of Surgery, V.M.M.C. & Safdarjung Hospital, New Delhi-110029

Corresponding Author: Dr. Arun Singh,

**Abstract:** Hernia and Appendix are two most common surgical problem encountered by a general surgeon. The presence of Appendix within inguinal hernia sac is termed as Amyand's hernia. It is an uncommon condition and rare presentation, estimated to be found in Approximately 1% of adult Inguinal Hernia. Its diagnosis is very difficult preoperatively, generally diagnosed accidentally and intra-operatively. We present a case of Inguinal Hernia where normal Appendix was found intra-operatively during repair of right inguinal hernia in a 60 years male patient. Mesh Hernioplasty was done without appendicectomy.

**Keywords:** Amyand's hernia, Inguinal hernia, Appendix

Date of Submission: 25-11-2018

Date of acceptance: 07-12-2018

### I. Introduction

Hernia is defined as the protrusion of a viscous or part of viscous through the wall of its containing cavity. Inguinal hernia and Appendix are two most common surgical problems encountered by a general surgeon. The content of Hernia Sac can be omentum, bowel, urinary bladder, ovary, fallopian Tube. Very rarely the content of Hernia Sac is Appendix. Amyand's Hernia is presence of Vermiform Appendix in Inguinal Hernia Sac. The incidence reported in the literature varies between 0.19 to 1.7%. [1]. Amyand's Hernia is commonly seen in children because of patent vaginal process [2]. Preoperatively the diagnosis of this hernia is very difficult as imaging is generally not done since hernia is a clinical diagnosis. We are reporting a case of this rare type of hernia diagnosed intraoperatively.

### II. Case Report

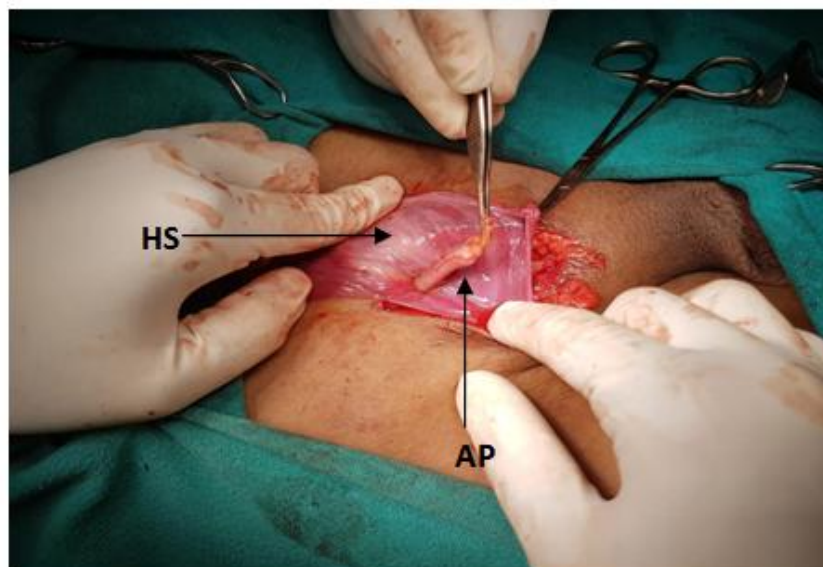


Figure 1. Showing normal appendix in Hernial Sac. (HS-Hernia Sac, AP-Appendix)

A 60 years old male patient came in OPD with complaints of reducible swelling in Right Inguinal region since 2 years. The swelling was reducible, non-tender and cough impulse was present. Patient was known case of Hypertension, taking regular medication. Diagnosis of right sided Indirect Hernia was made and patient was taken up for elective hernioplasty after proper pre-anesthetic check-up. On Opening the Sac, Vermiform Appendix was content. Appendix was normal, without any sign of inflammation (figure 1). The Sac content was

reduced and Hernia Sac was ligated with non-absorbable suture. Lichtenstein Repair was done using synthetic mesh. Post-operative period was uneventful.

### III. Discussion

Amyand's Hernia is defined as Appendix in Inguinal Hernia Sac. This Hernia is named after the surgeon who performed first Appendectomy. This rare Hernia is most frequently reported in men and almost exclusively on Right Side[3,4]. Left sided Amyand's Hernia can be seen in exceptional cases such as Situs inversus, Intestinal Malrotation, Very loose Caecum [5,6,7,8].

The diagnosis in majority of the cases is usually made intra-operatively on surgical exploration of Inguinal Hernia. One of the hypothesis regarding its pathophysiology is that once appendix descends in the Sac, it becomes vulnerable to Trauma and develops adhesion with Sac and similarly is likely to become inflamed in due course of time due to Trauma and decreased blood supply leading to bacterial overgrowth.

Various classifications have been proposed for the Amyand's Hernia such as Losanoff and Basson Classification. And its modification by Rikki. We are proposing a new and simple and more clinical classification of Amyand's Hernia as "Delhi Classification of Amyand's Hernia".

**Table 1: Delhi Classification of Amyand's Hernia**

Classification	Description
Type 1	Normal Appendix in an inguinal hernia
Type 2	Inflamed appendix in an inguinal hernia
Type 3	Appendicular Phlegmon in inguinal hernia
Type 4	Perforated Appendix in inguinal hernia +/- abdominal sepsis/peritonitis
Type 5	Appendix in left inguinal hernia

Majority of the surgeon still believe that normal appendix within Hernia Sac does not require Appendectomy as every effort should be made to preserve the organ found in Hernia Sac, for uneventful post-operative recovery [9,10]. The treatment of Hernial Appendicitis should be Appendectomy with primary repair of Hernia without mesh [11]. Patient in whom the appendix is inflamed, suppurative or perforated, no prosthetic material should be used because of increased risk of surgical site infection and fistula formation from Appendicular stump [12,13].

### IV. Conclusion

Amyand's Hernia is a rare condition in which Appendix as a content of Hernia Sac. Generally diagnosed accidentally, intra-operatively, hence surgeon must keep the possibility of Amyand's Hernia in mind while operating Inguinal Hernia specially obstructed or strangulated Inguinal Hernia.

### Reference

- [1]. Ivashchuk G, Cesmebasi A, Sorenson EP, Blaak C, Tubbs SR, et al. (2014) Amyand's hernia: A review. *Med Sci Monit* 20: 140-146.
- [2]. IvashchukGalyna. Amyand's hernia: a review, *Med Sci Monit*. 2014;20:140–146. [PubMed]
- [3]. Ramsingh Jason, Ali Ahmad, Cameron Caroline, Al-Ani Ahmed, Hodnett Robert, Chorushyj Catriona. De Garengot's hernia: diagnosis and surgical management of a rare type of femoral hernia. *J Surg Case Reports*. 2014;(2) [PMC free article] [PubMed]
- [4]. Michalinos A., Moris D., Vernadakis S. Amyand's hernia: a review. *Am J Surg*. 2014;207:989–995.[PubMed]
- [5]. Ortega-León L.H. Hernia de Amyand: Presentación de un caso y revisión de la literatura. *Rev Med Hosp Gen Méx*. 2011;74(2):98–100.
- [6]. Tsang W.K. Acute appendicitis complicating Amyand's hernia: imaging features and literature review. *Hong Kong Med J*. 2014;20:255–257. [PubMed]
- [7]. IvashchukGalyna. Amyand's hernia: a review, *Med Sci Monit*. 2014;20:140–146. [PubMed]
- [8]. Hussain K., Aurangzeb, Ahmed M., Masood J. Left sided Amyand's hernia. *J Coll Physicians Surg Pak*. 2014 Jan;24(1):62–63. <http://dx.doi.org/01.2014/JCPSP.6263> [PubMed]
- [9]. Bleichrodt RP, Simmermacher RK, van der Lei B, SchakenraadJM. Expanded polytetrafluoroethylene patch versus polypropylene mesh for the repair of contaminated defects of the abdominal wall. *SurgGynecolObstet* 1993; 176: 18-24
- [10]. Franko J, Raftopoulos I, Sulkowski R. A rare variation of Amyand's hernia. *Am J Gastroenterol*.2002 Oct; 97(10):2684-5.
- [11]. Logan MT, Nottingham JM: Amyand's Hernia: A case report of an incarcerated and perforated appendix within an inguinal hernia and review of the literature. *AmSurg* 2001; 67:628-629
- [12]. Samani R.S. Amyand's hernia: an extremely rare condition of inguinal hernia accompanied with acute appendicitis. *Ann Colorectal Res*. 2014;2(1):e17748.
- [13]. Nicola S.M. Hernia de Amyand: presentación de un caso y revisión de la literatura. *Rev ChilCirugía*. 2007;59(2):142–144.

Dr. Arun Sing. , ""Wandering Appendix in inguinal hernia sac: Amyand's hernia, a case report". " IOSR Journal of Dental and Medical Sciences (IOSR-JDMS), vol. 17, no. 12, 2018, pp 42-43.