

Underlay technique of Myringoplasty – Easier and Faster method of placing lateral to handle of malleus – How effective and successful ?

Durgaprasad. V.N. Kaza¹, Achyuth. Panuganti²

¹Assistant Prof. Of ENT, Osmania Medical College and Govt. ENT Hospital, Koti, Hyderabad, India.

²Resident Dept., of ENT, Osmania Medical College and Govt. ENT Hospital, Koti, Hyderabad India.

Corresponding Author: Durgaprasad. V.N. Kaza

Abstract: The study is to compare the hearing improvement in patients after myringoplasty/ type 1 Tympanoplasty, between two groups i.e., (Group A) graft placed medial to handle of malleus, and (Group B) graft placed lateral to the handle of malleus, based on Pure Tone Audiometry reports postoperatively. This study is done in Govt ENT Hospital/ Osmania Medical College, from August 2014- October 2015. 100 cases with dry central perforation were selected for the candidacy with the help of inclusion and exclusion criteria. Patients were alternatively distributed among two groups. Patient is kept on regular follow up and audiogram is obtained on 4-6th month postoperatively. Data analysed using graphs, tables and p value. When the two groups were compared, after 4-6 months, the hearing improvement between the two groups was not significant.

Key Words: Myringoplasty, Tympanoplasty type 1, medial to handle, lateral to handle, underlay technique.

Date of Submission: 14-11-2018

Date of acceptance: 29-11-2018

I. Introduction

Tympanoplasty type 1 or myringoplasty is carried out in the patients with dry central perforation without ossicular disruption. A graft which is most often temporalis fascia is used to close the perforation. The techniques employed are overlay and underlay.

In underlay technique, the graft is placed medial to handle of malleus, giving a slit and with or without, double breasting handle of malleus with the two flaps. Tabb and Shea first innovated medial positioning of grafting tissue to malleus and residue of TM^{1,2,3,4}. But some surgeons improvised the technique by placing the graft lateral to the handle of malleus without exteriorising the ossicle and medial to tympanomeatal flap.

Present study is to assess the results in terms of hearing improvement following Tympanoplasty by underlay technique by placing graft medial and lateral to the handle of malleus.

Aims and Objectives

To assess and compare the hearing improvement in patients who underwent tympanoplasty type 1 or myringoplasty with graft placed medial to handle of malleus and in patients with graft placed lateral to handle of malleus part of underlay technique.

II. Materials and Methods

A randomized prospective study was conducted for a period of 1 year from August 2014 to August 2015. It included 100 patients who presented to the Otorhinolaryngology department with a small or medium sized central perforation in tympanic membrane. They were randomly allocated into two groups of 50 patients each. In group A, the temporalis fascia graft was placed medial to the handle of malleus while in group B the graft was placed lateral to the handle of malleus but medial to the remnants of the tympanic membrane or fibrous annulus while in group B the graft was placed lateral to the handle of malleus but medial to the remnants of the tympanic membrane of fibrous annulus. The two groups were followed up for 6 months post operatively. The preoperative and postoperative air bone (AB) gaps in both groups were compared. The success of surgery was defined as complete repair of tympanic membrane perforation without lateralization or medialization, atelectasis or blunting with post-operative hearing gain.

INCLUSION CRITERIA

1. Patients suffering with unilateral Chronic Suppurative Otitis Media of dry central perforation with hearing loss less than 40 dB.
2. Age group of 20 to 40 years.

EXCLUSION CRITERIA

1. Patients with Central Perforation with active discharge.
2. Patients with Attico Antral Disease or Squamosal disease.
3. Patients with Ossicular disruption are assessed pre operatively by high A-B gap more than 40-60 dB hearing loss are found preoperatively.
4. Recurrent Chronic Suppurative Otitis Media.
5. Bilateral Chronic Suppurative Otitis Media.
6. Patients with sensorineural deafness

Study Area: Govt ENT Hospital, Hyderabad, India.

Design of study: Prospective study.

100 patients with dry central perforations and hearing loss up to 40dBHL are elected and distributed alternatively to both the groups, Group A and group B, after explaining them about the study being undertaken and after taking their consent. In group A, Myringoplasty is done by underlay technique with graft placed medial to handle of malleus, in Group B, Underlay technique with graft placed lateral to the handle of malleus.

Procedure

Anesthesia for Tympanoplasty:

Local anaesthesia (2% lignocaine with 1:100000 adrenaline) with sedation has been the standard protocol in adults. However general anaesthesia is a suitable option in pediatric and group cases and in very apprehensive patients .

Position of the patient

Patient is placed in supine position close to the edge of the table .the head is turned approximately 120 degrees away from the surgeon and is supported with a folded towel placed between the table and the contra lateral cheek.

Approaches

The following approaches were employed to reach middle ear :

- **Transcanal approach**
- **The endaural approach**
- **The postauricular approach**

Grafting materials

Multiple substances have been used for grafting the TM since the inception of tympanoplasty. The original use of full thickness and split thickness skin grafts has been replaced by other graft substances because of the high rate of delayed re-perforation secondary to desquamation and subsequent infection. House and Sheehy started using canal skin and initially had excellent results. Storrs (1960) was the first to use temporalis fascia. It now is the most common source of graft material used in tympanoplasty today. It has the benefit of providing a large quantity of graft material, it is sturdier than loose areolar tissue, more resilient than vein, and is easily harvested without need for a separate incisions.

In the present study only temporalis fascia has been used for grafting dry central perforations to maintain uniformity in the study. Temporalis fascia has a similar basal metabolic rate as that of the tympanic membrane also the colour and sheen is that of the tympanic membrane. Temporalis fascia graft material can also be obtained in adequate quantity .hence temporalis fascia is the most commonly used graft material.

Grafting techniques

There are two widely accepted techniques for grafting in tympanoplasty:

- ❖ The underlay technique or medial grafting and
- ❖ The overlay technique or lateral grafting.

In the Present Study only underlay technique of grafting has been employed

Underlay technique (medial grafting):

The postauricular and canal skin are initially injected with 2% xylocaine with 1: 1 00,000 concentration of adrenaline to assist with hemostasis. Tympanoplasty is typically performed via a postauricular approach although transcanal approaches are also utilized and is equally successful in the appropriate patient.

The postauricular incision is made approximately 5mm behind the postauricular crease. A large temporalis fascia graft is harvested, cleaned of residual muscle, and placed on a ceramic block to allow drying. A T-shaped incision is made in the periosteum overlying the mastoid. Alternatively, a Palva flap can be made.

The periosteum is elevated and moved anteriorly into the ear canal. The canal skin and periosteum is elevated using a duckbill elevator or round knife. A self-retaining retractor is placed to retract the canal skin and the ear forward. The canal incision is designed to create a laterally based canal skin flap or vascular strip. The horizontal incision is cut first approximately 2 to 5 mm lateral to the annulus from the 12 to the 8 o'clock position (right ear). The vertical incisions are made next. The superior limb follows the tympanosquamous suture line and the inferior limb follows the tympanomastoid suture line. The margins of the perforations are debrided.

The undersurface of the Tympanic membrane is then abraded with a round knife to increase adhesion to the graft. A tympanomeatal flap is then elevated anteriorly. The undersurface of the flap should be inspected for any skin that has turned over the edge of the perforation and is subsequently removed. The flap may be incised to create superior and inferior flaps which may give better exposure and may be more easily replaced. The status of the middle ear is then inspected for disease. The ossicles are gently manipulated with a **Rosen** needle to evaluate for mobility. The round window reflex may be inspected at this time. Some curettage of the scutum may need to be done to inspect the stapes footplate

The eustachian tube and middle ear are then packed with Gelfoam. The fascia graft is shaped to the proper size needed for the perforation. It is then carefully tucked into position under the anterior tympanic membrane remnant and onto the posterior canal wall. To prevent the medial displacement of the graft an anterior tucking of the graft should be made by giving a small incision 2mm lateral to the annulus, anterosuperiorly in the bony canal wall skin and bringing out the graft through this incision (KERR's technique). The annulus is placed back into position posteriorly and the vascular strip is carefully moved into its anatomic place. Gelfoam is placed over the drum remnant, graft, and vascular strip and the external canal is filled with a **Neosporin** ointment impregnated cotton ball. The postauricular incision is sutured. A mastoid dressing is placed to provide light pressure and protection.

In the present study grafting was done by placing temporalis fascia medial and lateral to the handle of malleus in equal number of cases each.

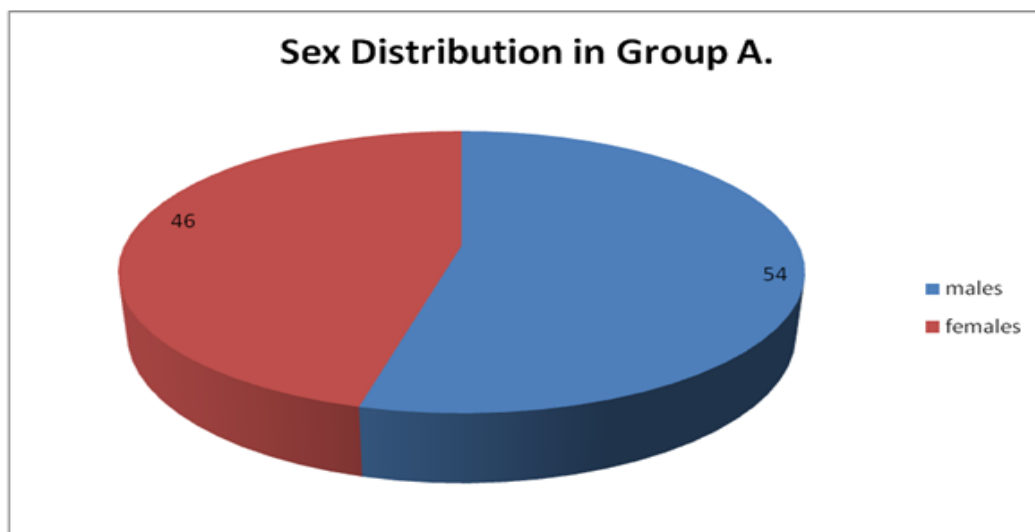
Post-operative care

Patients were prescribed oral antibiotics and anti-inflammatory and decongestant drugs on the 1st post-operative day, the same was continued till 5th post-operative day, dressing of the operated ear changed and patient discharged with oral medication. Patient was reviewed 1 week from the day of discharge and then 2 weeks after that to monitor the graft uptake and occurrence of any postoperative complications. Patients were counselled not to allow water to enter the operated ear, not to blow the nose and avoid heavy weight lifting. Examination under the microscope performed and gel foam gently suctioned off if still present 3 to 4 weeks from the day of surgery. A Pure Tone Audiogram was obtained for each patient after 4 months from date of surgery.

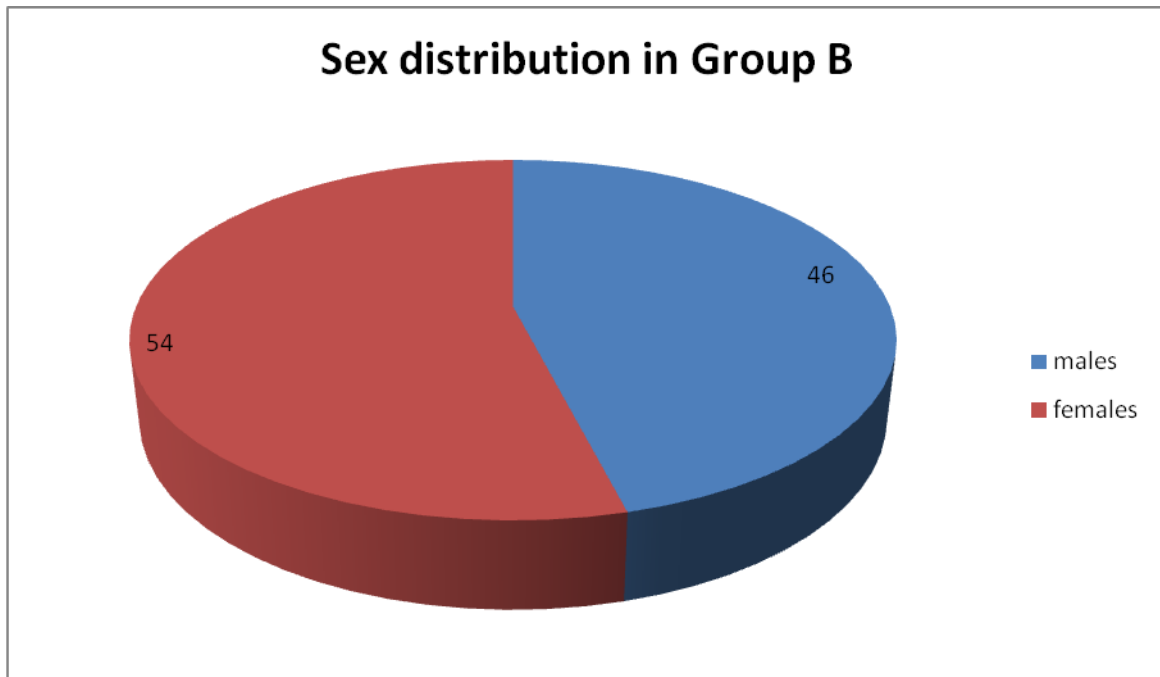
Data Analysis

Data collected were entered into EXCEL Spreadsheet, for processing and the software SPSS version 17.0 is used for processing the *p* values. Value <0.005 is considered significant.

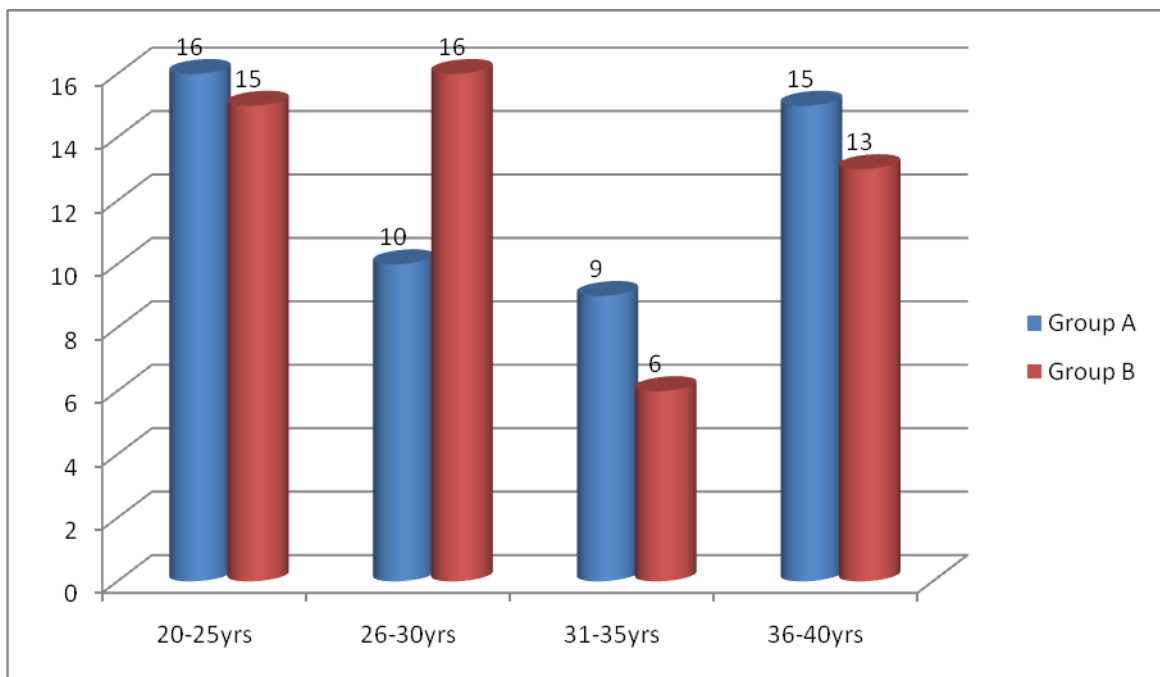
OBSERVATIONS AND RESULTS



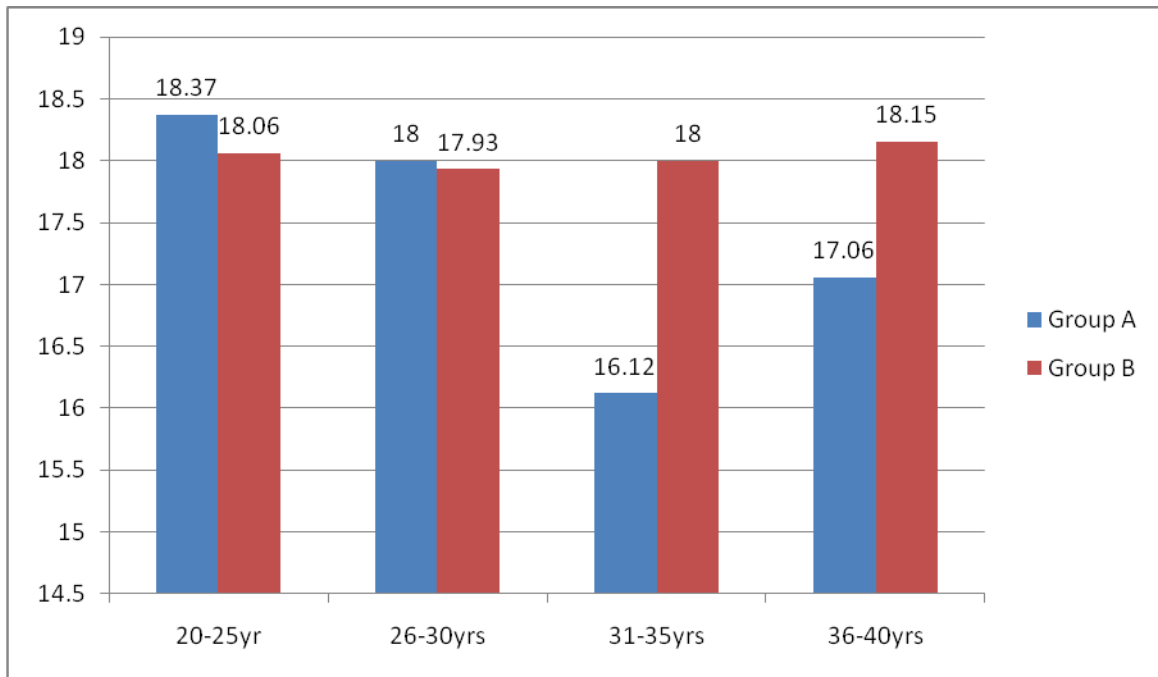
The total no of patients under Group A is 50 with male incidence of 27(54%) and female incidence of 23(46%). Male : Female ratio was 1.17: 1



The total no of patients under Group BG Is 50 with male incidence of 23(46%) and female incidence of 27(56%). Male : Female ratio was 0.8: 1.

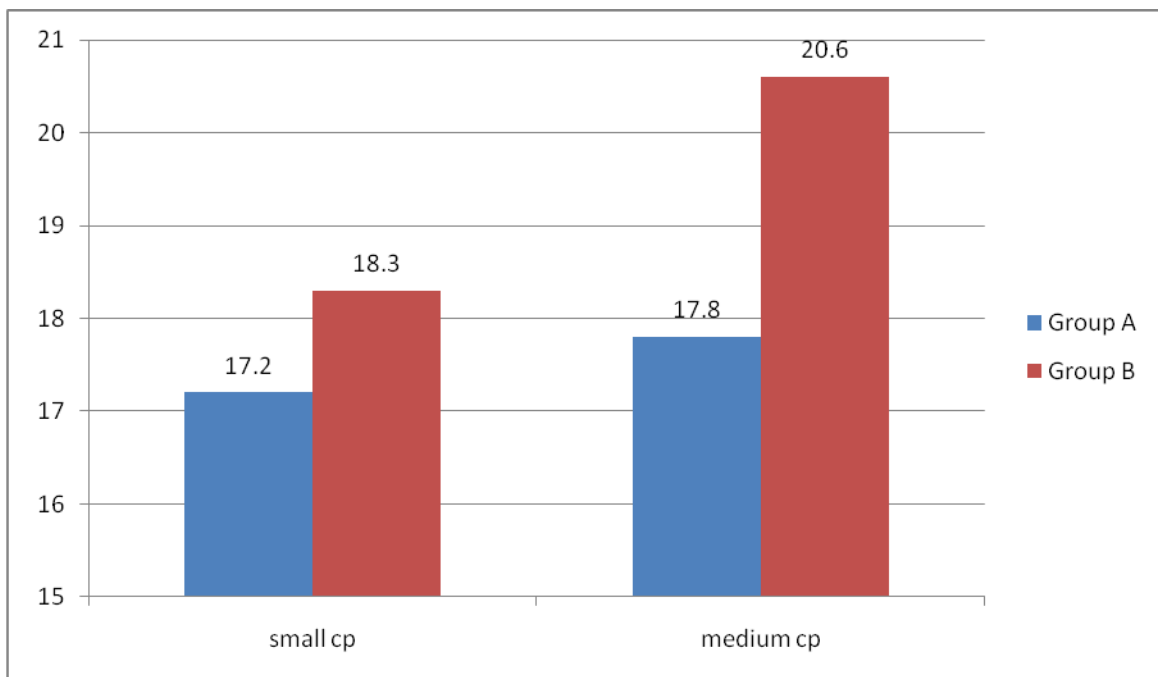


Age wise distribution of patients in both the Groups. Most of the patients were under 20-25 years of age group and least in 31-35 years age group.

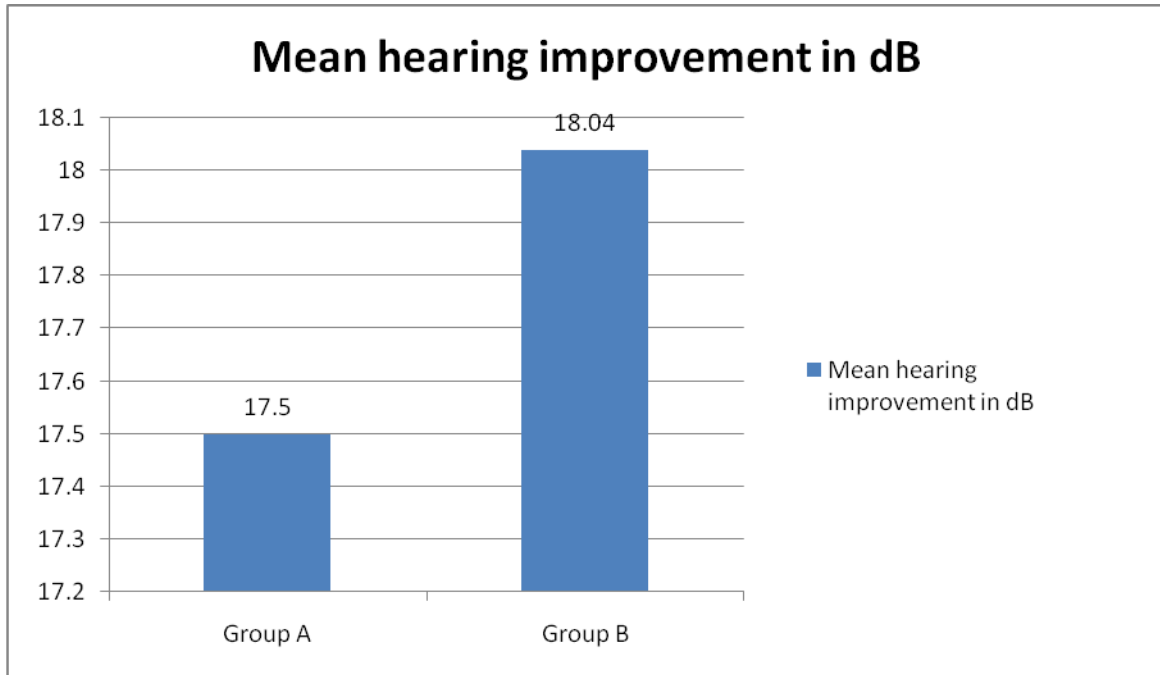


The incidence of Air bone gap improvement among different age groups in Group A and Group B was 18.37dB , 18.06dB in 20-25 years age group, 18dB , 17.93dB in 26-30 years age group, 16.12dB , 18dB in 31-35years age group , 17.06dB, 18.15dB in 36-40 years age group respectively in Group A and Group B.

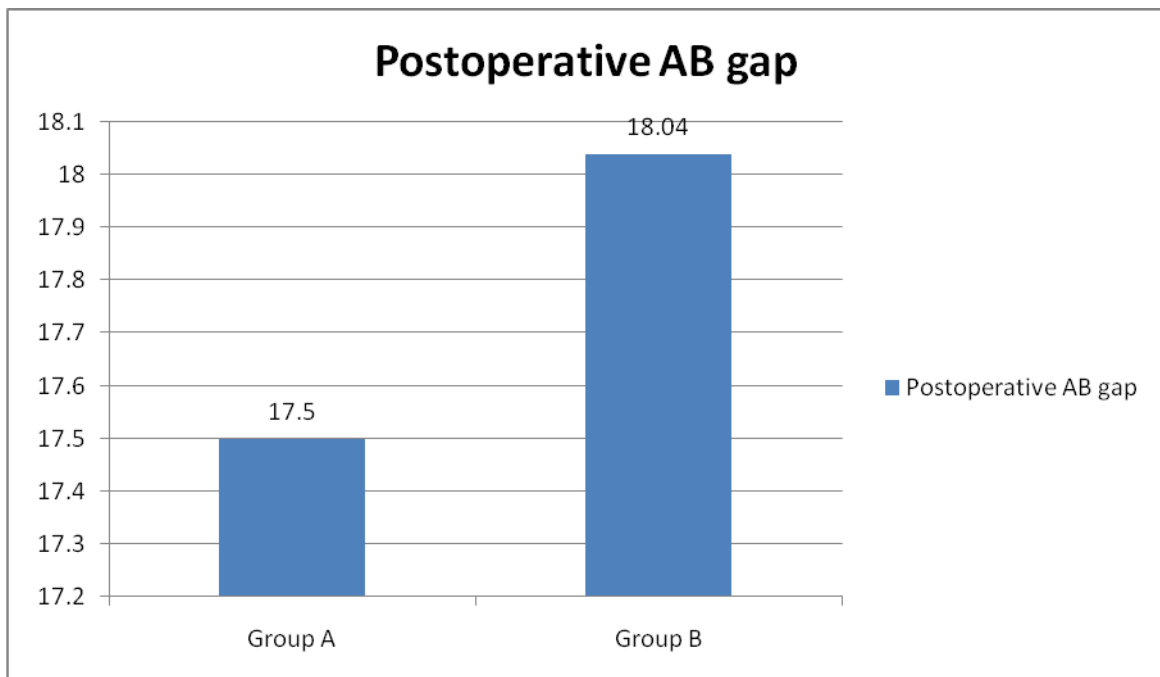
The hearing improvement in age group from 20-30 years was marginally better in group A, and in 31-40 years age group was better in Group B.



Post operative Airbone gap improvement in small Cp and medium Cp comparing both groups shows a better improvement in Group B for both categories.



The mean hearing improvement in dB among the two groups was 6.34dB among medial to malleus technique group and 6.8dB in lateral to malleus technique.



The postoperative AB conduction was better in Group B patients compared to Group A

III. Discussion

In the present study 100 patients with dry central perforation have been chosen for Tympanoplasty Type I by underlay technique. Exclusion criteria were strictly followed. Only patients with unilateral dry central perforation were included in the study and surgery was carried out to maintain uniformity. The patients have been divided into two groups of equal number. The perforation was closed by placing the graft medial to malleus in Group A and lateral to malleus in Group B. Hearing improvement in both instances have been assessed and analyzed.

As early as 1992 Stage J, Bak Pederson K⁵ reported significant improvement in hearing following Tympanoplasty with graft placed lateral to handle of malleus. They carried out procedure in mainly anterior

inferior and also large central perforations. Complications were minimal with one residual perforation from 39 cases and some showing mild laterofixation.

B.Vishwanatha et al., reported in their comparative results obtained by similar procedures concluding that hearing improvement was nearly identical in both methods.⁶

In retrospective study in Turkey, a total of 104 patients underwent tympanoplasty, via underlay technique in 46 patients and over-under technique in 58 patients. The mean follow-up period was 11 months. In the first group of patients with underlay technique (the graft was placed medial to the remaining drum and the manubrium), the success rate was 91.5%. In the second group with over-under technique (the graft was placed under the remaining drum and over the malleus), the success rate was 94.9%. In the patients operated by the underlay technique, the air-bone gap decreased 16.55 db. This rate was 16.96 db in those operated via the over-under technique.

In another study in Michigan Ear Institute, the chosen technique had been under lay tympanoplasty which was performed by placing the graft under the annulus and remnant of Tympanic membrane lateral to handle of malleus. All their 120 patients had successful grafts. Lateralization of the grafted drum did not occur. Seventeen patients had late atelectasis, and 12 patients had late perforations; nearly all of these were noted more than 1 year after surgery and were attributed to persistent Eustachian tube dysfunction or infections. Average improvements in air-bone gap for all patients was 5.3 db, whereas speech reception threshold improved by 5.9 db.

In another study by Fiorino in Italy, 78 umbo-anchored over-under myringoplasties were performed. They used a large graft with a radial slit distended under the TM and annulus, and two tongues were positioned to surround the umbo area and overlapped under a non-perforated portion of the TM. Graft take was obtained in 91% of cases and the auditory result showed an average residual air-bone gap of 6.7 db

In Ryan study on 147 patients, overlay graft technique was highly successful for TM repair which was 98.75%, even in difficult cases

The study of Jung concluded medial graft tympanoplasty is suitable for posterior TM perforation, and medio-lateral graft method is an excellent for the reconstruction of large anterior subtotal TM perforation⁵

On the basis of our study data, short-term outcomes of both techniques were good and there was no significant difference between their graft take and audiometric results. It seems that good performance of any technique by the surgeon is the more important factor in success of surgery than the type of technique. Also noteworthy to mention there are no absolute indications for any of these techniques.

Yawn RJ, Carison ML., Haynes DS and Rivas A reported excellent hearing recovery, very low incidence of lateralization and no risk of excessive ossicular movement and sensorineural deafness. They also claimed improved exposure and formation of air filled tympanic cavity post operatively were much better with the present technique.¹

Recently Tangs and Brown KD have reported high success rate even with lateral graft technique even lateral to Tympanic membrane but present study includes graft placement only lateral to handle of malleus under remnant membrane keeping in view epithelial migration.⁷

Lyons et al., reported no significant difference in graft take up and hearing improvement while comparing temporalis fascia vs composite cartilage graft even in subtotal perforation. Hence temporalis fascia graft lateral to handle of malleus can be considered acceptable for any type of perforation.⁸

Indorewala S et al., reported from a retrospective review of 789 patients over a period of one year and found no significant advantage of one technique over the other and concluded that optimal results can be obtained by appropriate 'surgical' skill and technique.⁹

Kazikdas K C et al., compared results between palisade cartilage tympanoplasty and temporalis fascia grafting and found no significant difference.¹⁰

Kulduk E et al., did not find any significant difference between the two techniques in their study¹¹

IV. Conclusions

For medium and small sized perforations underlay technique of tympanoplasty with graft placed lateral to malleus gives same results as those placed medial to malleus.

The exposure and formation of an air filled middle ear cavity following surgery are excellent and possible injury of middle ear structures and its incidence are much less with this technique. It is of particular value in small sized middle ear with varying degrees of medially placed malleus either anatomically or due to disease process.

Various studies also indicate the results from the present study even in subtotal perforation. No significantly superior results have been reported with alternate graft materials like composite cartilage graft.

Hence it can be safely concluded that underlay technique of tympanoplasty with graft placed lateral to malleus in dry central perforations of Tympanic membrane in Chronic Suppurative Otitis Media of mucosal type provides excellent results in terms of take up of the graft and improvement in hearing.

References

- [1]. Spiros M. Closure of tympanic membrane perforation. In: Glasscock MA, Gulya AJ, editors. Glasscock-Shambough surgery of the ear. Ontario: BC Decker Incorporation; 2003. pp. 400–22
- [2]. Shea JJ., Jr Vein graft closure of eardrum perforations. *J Laryngol Otol.* 1960;74:358–62. [PubMed]
- [3]. Tabb HG. Closure of perforations of the tympanic membrane by vein grafts. A preliminary report of twenty cases. *Laryngoscope.* 1960;70:271–86. [PubMed]
- [4]. Tabb HG. Experience with transcanal and postauricular myringoplasty. *Trans Pac Coast OtoophthalmolSocAnnu Meet.* 1968;52:121–5. [PubMed]
- [5]. Panosian MS, Dutcher PO Jr. Transcynlpauc facial nerve injury in welder. *Occup Med (Lond)* 1994;44(2):99-101
- [6]. Dr B Vishwanath, *Research in Otolaryngology* 2014, 3(5): 65-69 DOI: 10.5923/j.otolaryn.20140305.01
- [7]. Berger G, Finkelstein Y, Harell M. Non-explosive blast injury of the ear. *J LaryngolOtol* 1994;108(5):395-8.
- [8]. Miller IS, McGahey D, Law K. The otologicconsequences of the Omagh bon1b disaster. *Otolaryngol Head Neck Surg* 2002;126(2):127-8.
- [9]. *Clinical Otolaryngology and allied sciences* 1992 Feb; 17(1) 6-9.
- [10]. Yawn RJ, *Otology Neurotology* 2014 Dec; 35 (10); 1809-12 doi 10.1097 MAO 512.
- [11]. Tang S, Brown KD, *otology Neurotology* 2015 Feb; 36 (2) 250-3 doi 10.1097 MAO 94

Durgaprasad. V.N. Kaza, "Underlay technique of Myringoplasty – Easier and Faster method of placing lateral to handle of malleus – How effective and successful ?" *IOSR Journal of Dental and Medical Sciences (IOSR-JDMS)*, vol. 17, no. 11, 2018, pp 51-58.