

Spectrum of Findings on HRCT in Evaluation of Interstitial Lung Diseases: A Single Centre Prospective Observational Study

Dr. Nupur Basu¹, Dr Avere Gangopadhayay²

¹Assistant Professor, Dept of Radio-Diagnosis, Medical College Kolkata

² Junior Resident, Dept of Radio-Diagnosis, Medical College Kolkata

*Corresponding author: Dr. Avere Gangopadhayay

Abstract

Background: Evaluation of the involvement pattern of pulmonary interstitium in suspected cases of Interstitial lung diseases with the help of HRCT and chest radiographic findings and then to arrive at a conclusive diagnosis, comparing accuracies of both modalities.

Objectives: To compare the accuracies of chest radiography and HRCT in the prediction of specific diagnosis of interstitial lung diseases as well as to study the demographic profiles of cases of ILD presenting to a tertiary-care hospital

Method : We investigated 40 patients having symptoms related to suspected Interstitial lung disease with laboratory investigations & imaging modalities like Chest X-ray & HRCT Thorax in our institution, Medical College, Kolkata, (a tertiary care hospital) for a period of 1 year from January, 2017 to December, 2017. We compared the clinical characteristics of patients with HRCT findings of ILD and classified the types of ILD according to the pattern of pulmonary interstitial involvement, the incidence of disease in males & females, age of incidence etc.

Results: 24 of the cases were females constituting 60% of the cases, and 16 were males constituting 40%. Rheumatoid arthritis, progressive systemic sclerosis and systemic lupus erythematosus were more in females. Idiopathic pulmonary fibrosis and pulmonary Koch's infections were common in males. Cases with pulmonary Koch's were the largest group in our study, constituting 27.5% of total number of cases, followed by progressive systemic sclerosis and rheumatoid arthritis (17.5%) each. The most number of cases of Pulmonary Koch's infection were noted in 3rd and 4th decade of life. The most number of cases with rheumatoid arthritis and progressive systemic sclerosis were in 5th and 6th decades.

The positive predictive value of HRCT for ILDs was 97.22% which was found to be superior to that of chest X-rays (93.93%)

Conclusions: Most detailed and precise diagnostic conclusion can be made only with HRCT scans, because HRCT scans can reveal up to the level of secondary pulmonary lobule, thereby closely correlating with histopathology. HRCT is more sensitive and specific in diagnosing most of the ILDs. Moreover, it helps us in describing disease extent and prognosis. Therefore we conclude that HRCT scan is the best non-invasive diagnostic modality in the evaluation of interstitial lung disease.

Keywords: High resolution computed tomography, Interstitial Lung Disease, Usual interstitial pneumonia, Idiopathic pulmonary fibrosis, Hypersensitivity pneumonitis, Systemic lupus erythematosus.

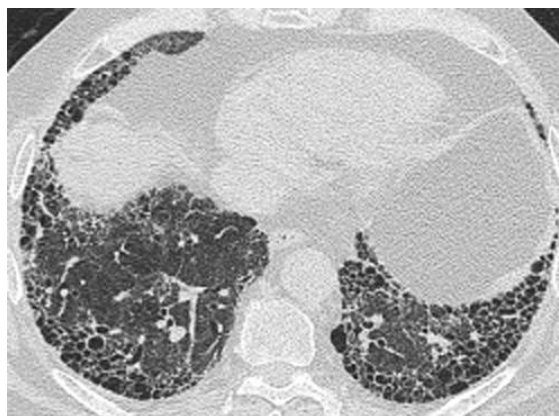
Date of Submission: 14-11-2018

Date of acceptance: 29-11-2018

I. Introduction

The term "interstitial lung diseases" indicates a heterogeneous group of conditions caused by diffuse thickening of the alveolar walls and the perialveolar tissue with inflammatory cells, exudates, granulomas, haemorrhage and/or fibrosis.¹

In some types of interstitial lung diseases, the causative factors are known, while majority are in the idiopathic category. The lung disease may occur in isolation or as a part of systemic connective tissue disorders, for example, in rheumatoid arthritis and scleroderma.



Classical Usual interstitial pneumonia pattern on HRCT

ILDs may present acutely, as in acute drug reactions, ARDS or the early stages of extrinsic allergic alveolitis, but more often the natural history is one of slowly progressive loss of alveolo-capillary gas exchange units over months or even years.

This relentless progression of increased lung stiffness with disordered matching of ventilation and perfusion results in worsening exertional dyspnoea, which in many cases progress to respiratory failure, pulmonary hypertension, cor pulmonale and eventually death.

The epoch-making description of HRCT dates back to 1985, including landmark descriptions of pulmonary HRCT findings by Nakata, Naidich and Zerhouni.^{2,3}

HRCT brought a revolution in pulmonary interstitial imaging where resolution reached the level of secondary pulmonary lobule or the functional unit of lung. Today HRCT images simulate pathological sections of the lung parenchyma.

HRCT combines the use of thinly collimated CT slices that are 1-1.5 to 2 mm in thickness, with a high spatial frequency algorithm that enhances edge detection.⁴

Thin collimation decreases partial volume averaging and improves the ability of CT to demonstrate small pulmonary lesions.⁵ HRCT helps us to arrive at an early conclusive diagnosis wherever possible and thus save precious pulmonary interstitium.⁶

CAUSES OF INTERSTITIAL LUNG DISEASES

Known Causes	Unknown Causes
<p>1. Occupational and Environmental inhalants</p> <ul style="list-style-type: none"> • Inorganic dusts- silicosis, asbestosis, coal worker's pneumoconiosis • Organic dusts- Hypersensitivity pneumonitis • Gases, fumes and aerosols- oxygen toxicity, sulphur dioxide, toluene 	<p>1. Collagen Vascular diseases:</p> <ul style="list-style-type: none"> • Systemic lupus erythematosus • Rheumatoid arthritis • Systemic sclerosis <p>2. Sarcoidosis</p> <p>3. Idiopathic pulmonary haemosiderosis</p> <p>4. Histiocytosis X</p> <p>5. Idiopathic Pulmonary Fibrosis</p> <p>6. Desquamative Interstitial Pneumonitis</p>
<p>2. Infections</p> <ul style="list-style-type: none"> • Cytomegalovirus • Bacterial-TB • Fungal • Protozoans- pneumocystis carinii 	<p>7. Alveolar proteinosis</p> <p>8. Eosinophilic pneumonia</p> <p>9. Goodpasture's Syndrome</p>
<p>3. Drugs and toxins</p> <ul style="list-style-type: none"> • Chemotherapeutic agents- busulfan, bleomycin • Antibiotics- nitrofurantoin • Antiarrhythmics- amiodarone • Others-gold, penicillamine • Toxins-Paraquat 	

American Thoracic Society/European Respiratory Society International Multidisciplinary Consensus Classification of the Idiopathic Interstitial Pneumonias

Major criteria
<ul style="list-style-type: none"> • Exclusion of other known causes of ILD such as certain drug toxicities, environmental exposures, and connective tissue diseases • Abnormal pulmonary function studies that include evidence of restriction (reduced VC, often with an increased FEV₁/FVC ratio) and impaired gas exchange [increased P(A-a)O₂, decreased PaO₂ with rest or exercise or decreased DL_{CO}] • Bibasilar reticular abnormalities with minimal ground glass opacities on HRCT scans • Transbronchial lung biopsy or BAL showing no features to support an alternative diagnosis
Minor criteria
<ul style="list-style-type: none"> • Age >50 yr • Insidious onset of otherwise unexplained dyspnoea on exertion • Duration of illness >3 months • Bibasilar, inspiratory crackles (dry or “Velcro”-type in quality)

*requirement for the presence of all four major and three of the four minor criteria

High-resolution computed tomography criteria for UIP pattern(2011)

UIP Pattern (All Four Features)	Possible UIP Pattern (All Three Features)	Inconsistent with UIP Pattern (any of the Seven Features)
■ Subpleural, basal predominance	■ Subpleural, basal predominance	■ Upper or mid-lung predominance
■ Reticular abnormality	■ Reticular abnormality	■ Peribronchovascular predominance
■ Honeycombing with or without traction bronchiectasis	■ Absence of features listed as inconsistent with UIP pattern (<i>see</i> third column)	■ Extensive ground glass abnormality (extent >reticular abnormality)
■ Absence of features listed as inconsistent with UP		■ Profuse micronodules (bilateral, predominantly upper lobes)
		■ Discrete cysts (multiple, bilateral, away from areas of honeycombing)
		■ Diffuse mosaic attenuation/air-trapping (bilateral in three or more lobes)
		■ Consolidation in bronchopulmonary segment(s)/lobe(s)

OBJECTIVES OF STUDY :

- To utilize HRCT in the evaluation of pulmonary interstitium in patients having clinical features of interstitial lung diseases.
- To categorise the involvement pattern of the pulmonary interstitium with the help of HRCT and chest radiographic findings and then to arrive at a conclusive diagnosis
- To use HRCT to determine the extent of involvement in cases of interstitial lung diseases
- To compare the accuracies of chest radiography and HRCT in the prediction of specific diagnosis of interstitial lung diseases.

II. Materials And Methods

Study settings: Department of Radiodiagnosis, Medical College & Hospital, Kolkata.

Period of study :The present study was conducted from 1st January 2017 to 31st December 2017.

Source of Data : The study group included all clinically suspected cases of interstitial lung diseases who came to the Dept of Radiodiagnosis, Medical College Kolkata for HRCT from OPD,indoor and referred cases.

PROCEDURE

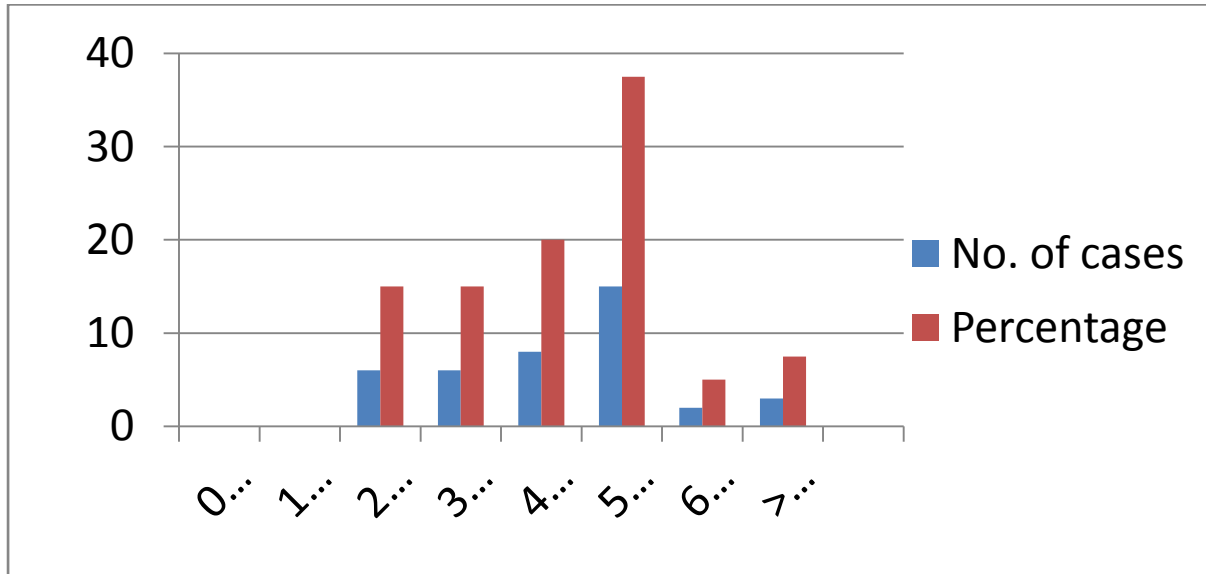
A thorough clinical history of all patients with clinical presentation and suspicion of interstitial lung diseases was taken, viz. symptoms, duration of symptoms, history of occupational exposure, similar symptoms in family members etc.

Any previous investigations in support of interstitial lung diseases were also recorded which included some preliminary chest x-rays and blood reports in support of interstitial lung diseases. The blood tests included Rheumatoid factor, ANA, Anti-Sm, Anti ds-DNA, Anti Scl-70, ABG analysis,ESR etc.

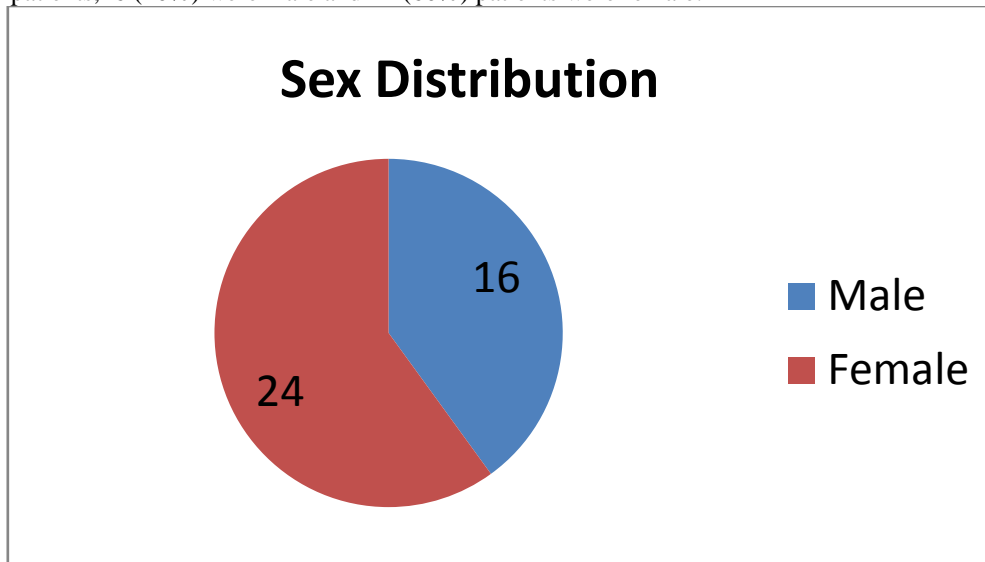
After taking informed consent, a chest radiograph and HRCT scan of thorax were done in all the cases taken up for study. Biopsy correlation and bronchoalveolar lavage was done in a few selected cases wherever necessary.

III. Results:

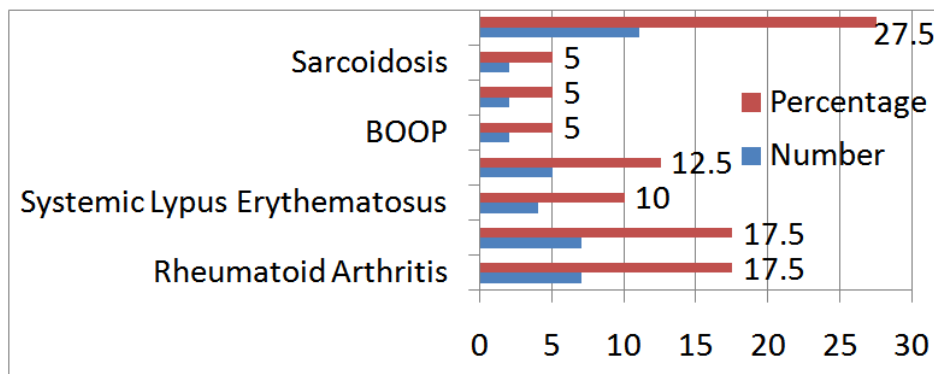
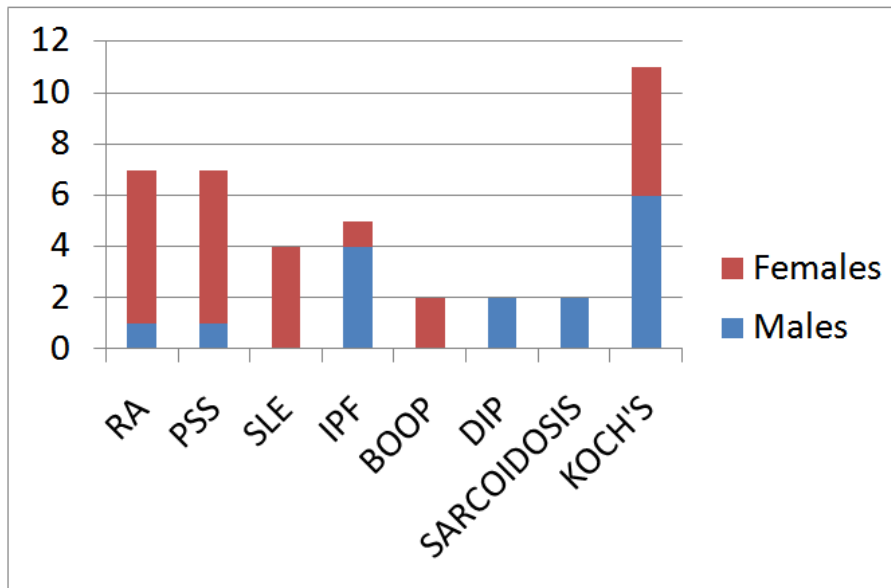
The highest percentage of cases were found in the age group of 50-60 years (37.5%), followed by the age group of 40-50 years (20%). No cases of ILD were found below 20 years and above 80 years.



Out of 40 patients,16 (40%) were male and 24 (60%) patients were female.

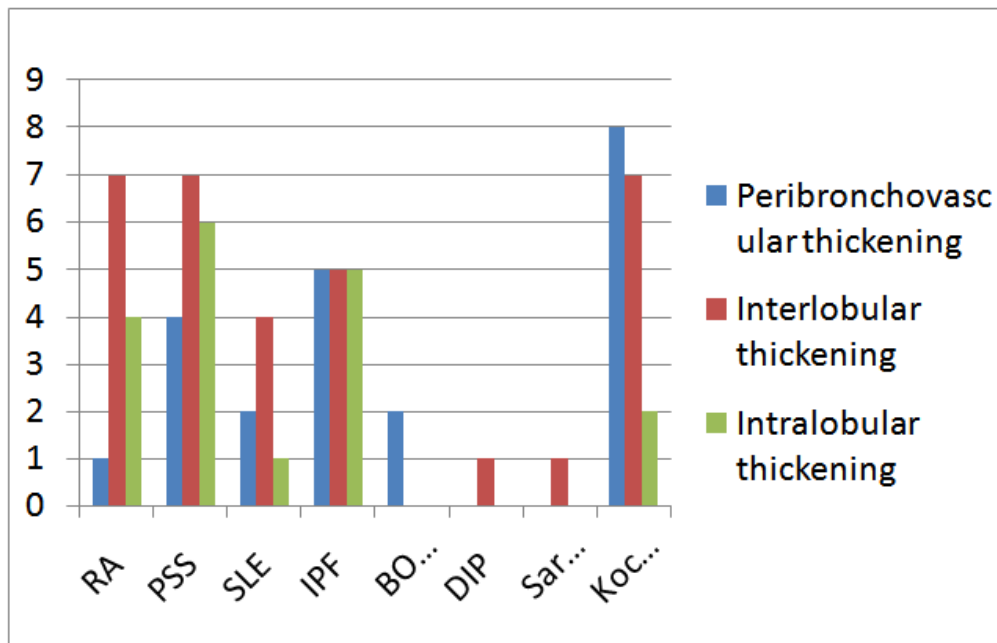


In our study,there was a definite female predominance noted in ILD due to collagen vascular disorders, viz rheumatoid arthritis, progressive systemic sclerosis, SLE. Male predominance was noted in sarcoidosis, desquamative interstitial pneumonia and idiopathic pulmonary fibrosis.



ETIOLOGY OF ILD IN PRESENT STUDY OF 40 CASES

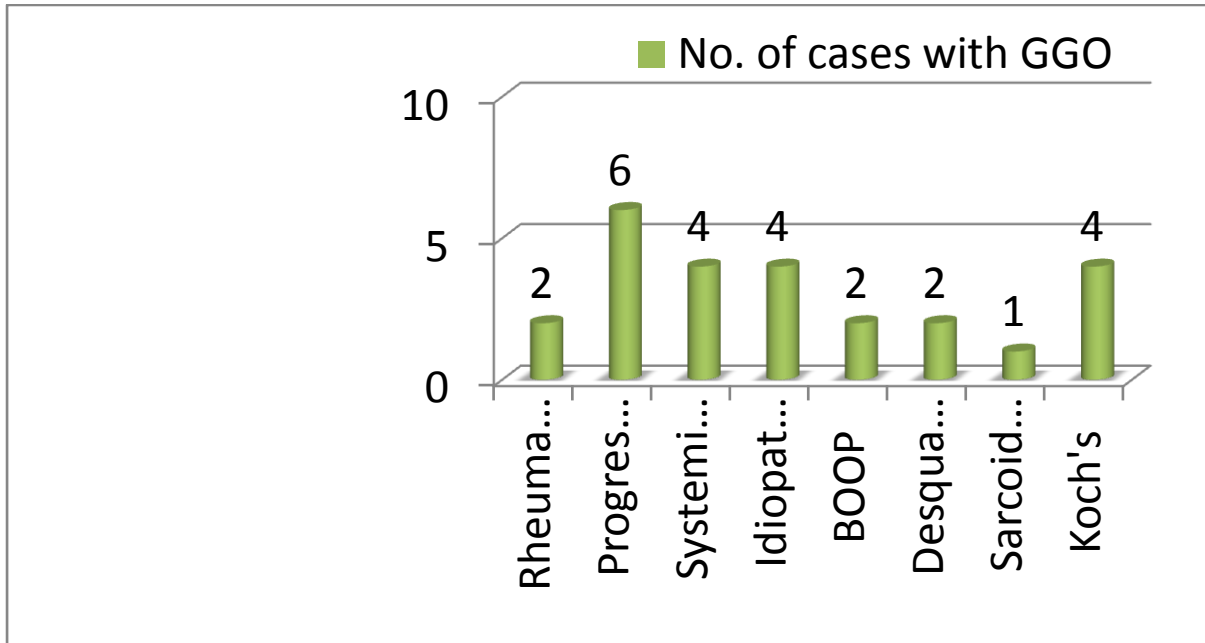
Peribronchovascular interstitial thickening was seen predominantly in the Koch's infection and Progressive Systemic Sclerosis.



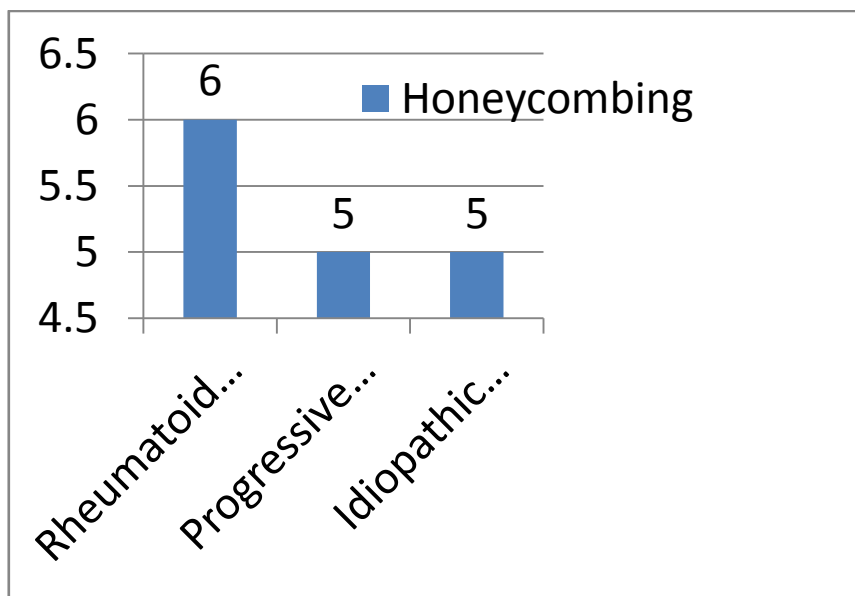
PATTERN OF RETICULAR/LINEAR OPACITIES IN DIFFERENT DISEASES

Interlobular septal thickening and intralobular interstitial thickening were seen predominantly in idiopathic pulmonary fibrosis, rheumatoid arthritis, progressive systemic sclerosis, Koch's infection and SLE, due to fibrosis and scarring.

In this study, ground glass opacity(GGO) was seen in almost all the disease entities. In SLE, BOOP and desquamative interstitial pneumonia, all the cases showed GGO. In progressive systemic sclerosis and idiopathic pulmonary fibrosis, maximum cases had GGO.



In our study, honeycombing was extensively found in cases of Rheumatoid arthritis, Progressive systemic sclerosis, and idiopathic pulmonary fibrosis. The presence of honeycombing indicates severe fibrosis.



Decision Matrix showing HRCT study

	Normal cases	Cases with ILD	Subtotal
Normal HRCT	2 (TN)	2 (FN)	4
Abnormal HRCT	1 (FP)	35 (TP)	36
Subtotal	3	37	

TN- True negative, FN- False negative, FP- False positive, TP- True positive

$$\square \text{ Sensitivity of HRCT in diagnosing ILDs (\%)} = \frac{\text{TP}}{\text{TP} + \text{FN}} = \frac{35}{35 + 2} = 94.59\%$$

$$\square \text{ Specificity of HRCT in diagnosing ILDs (\%)} = \frac{\text{TN}}{\text{TN} + \text{FP}} = \frac{2}{2 + 1} = 66.66\%$$

$$\square \text{ Positive predictive value of HRCT in diagnosing ILDs (\%)} = \frac{\text{TP}}{\text{TP} + \text{FP}} = \frac{35}{35 + 1} = 97.22\%$$

Decision Matrix showing chest radiographic study

	Normal cases	Cases with ILD	Subtotal
Normal chest xray	1 (TN)	6 (FN)	7
Abnormal chest xray	2 (FP)	31 (TP)	33
Subtotal	3	37	

TN- True negative, FN- False negative, FP- False positive, TP- True positive

$$\square \text{ Sensitivity of chest xray in diagnosing ILDs (\%)} = \frac{\text{TP}}{\text{TP} + \text{FN}} = \frac{31}{31 + 6} = 83.78\%$$

$$\square \text{ Specificity of chest xray in diagnosing ILDs (\%)} = \frac{\text{TN}}{\text{TN} + \text{FP}} = \frac{1}{1 + 2} = 33.33\%$$

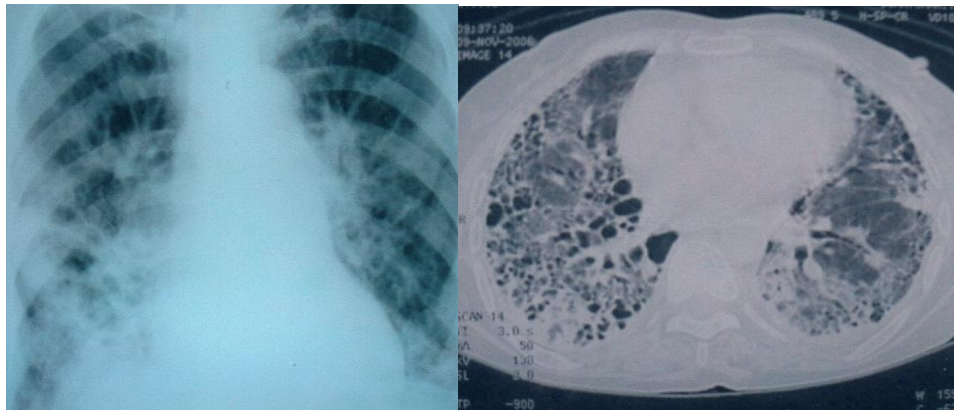
$$\square \text{ Positive predictive value of chest xray in diagnosing ILDs (\%)} = \frac{\text{TP}}{\text{TP} + \text{FP}} = \frac{31}{31 + 2} = 93.93\%$$

REPRESENTATIVE CASES

Case 1: A case of Rheumatoid arthritis

CxR PA view shows diffuse interstitial fibrosis,mainly at bilateral lower zones

HRCT scan shows extensive honeycombing,interlobular septal thickening,intralobular septal thickening,predominantly at peripheral subpleural location.

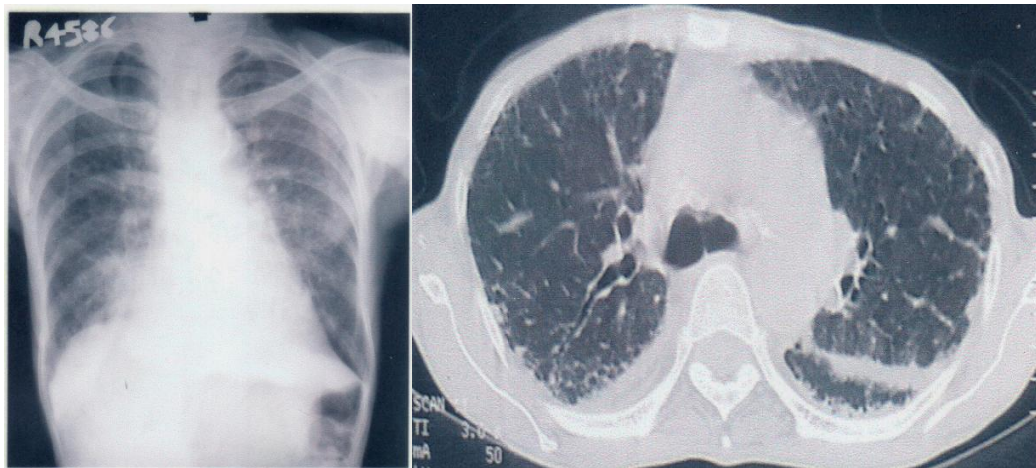


Case 1

Case 2: A case of Progressive systemic sclerosis

CxR PA view shows minimal reticular opacities, mainly at lower zones

HRCT scan shows interlobular septal thickening, subpleural interstitial thickening and ground glass opacities, at posterior subpleural location, features of UIP.

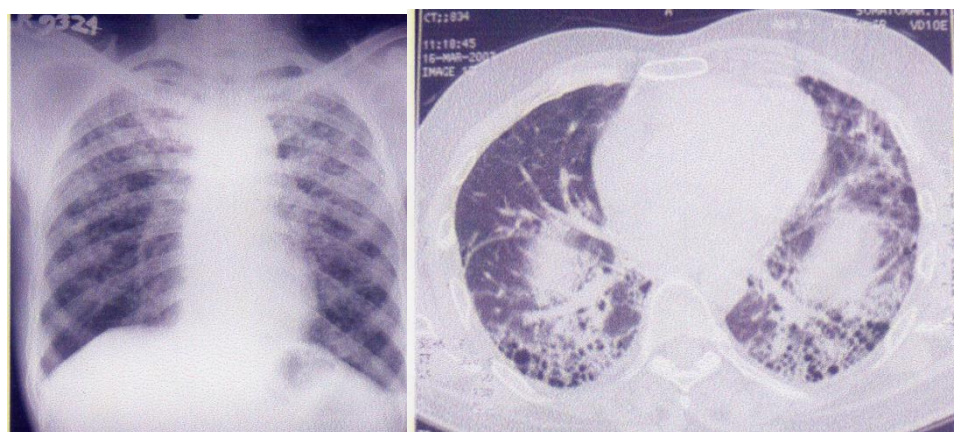


Case 2

Case 3: A case of Idiopathic pulmonary fibrosis

CxR PA view shows diffuse reticular opacities.

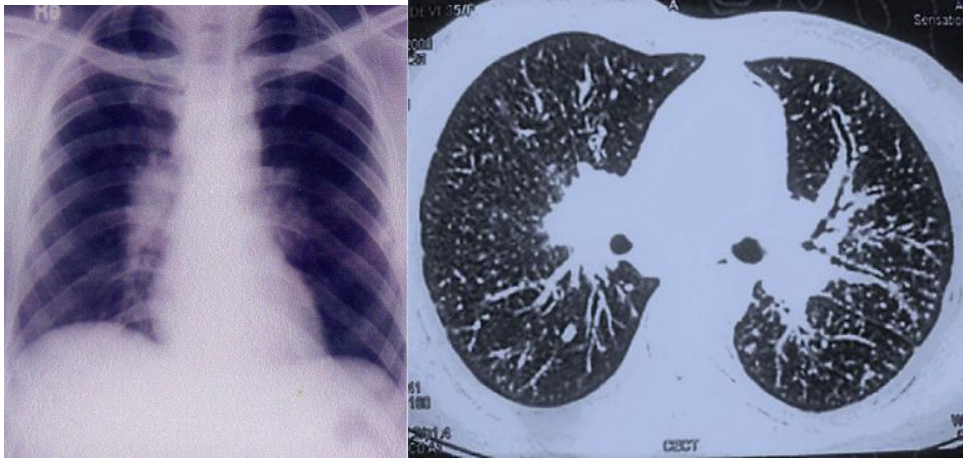
HRCT scan shows extensive honeycombing, interlobular septal thickening, intralobular septal thickening, at bilateral lower lobes, mainly at subpleural location.



Case 3

Case 4: A case of Sarcoidosis

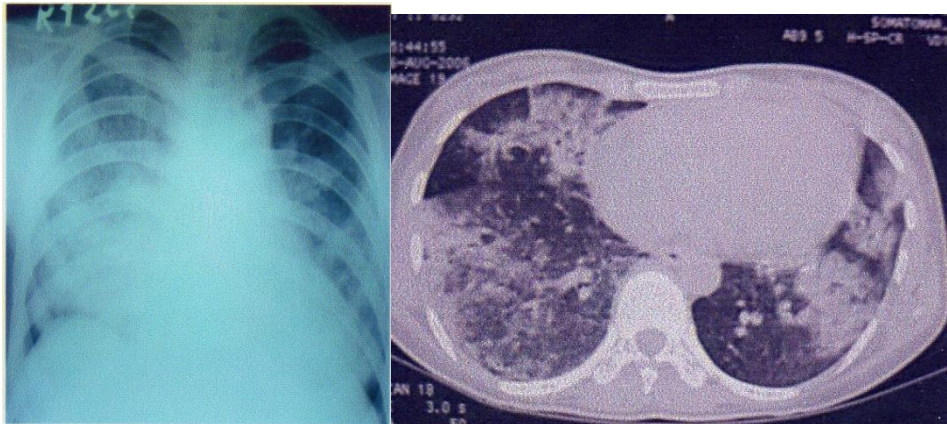
- a) CxR PA view shows bilateral hilar lymphadenopathy
- b) HRCT scan shows bilateral hilar lymph node enlargement, with nodular thickening of peribronchovascular interstitium



Case 4

Case 5: A case of BOOP

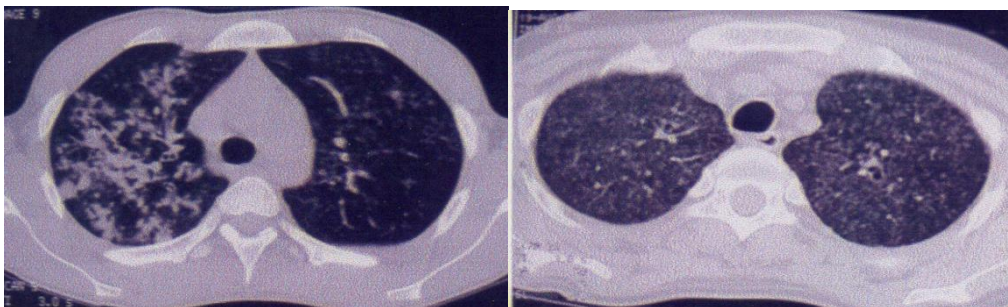
- CxR PA view shows patchy areas of consolidation at bilateral middle and lower zones
- HRCT scan shows patchy air-space consolidation & ground glass opacity bilaterally.



Case 5

Case 6: A case of endobronchial spread of pulmonary Koch's

- a) HRCT scan shows focal clusters of ill-defined nodular opacities and 'tree-in-bud' appearance at right upper lobe
- b) A case of miliary Koch's. HRCT image shows multiple, small, 1-2 mm sized nodules distributed throughout lung parenchyma



Case 6

IV. Discussion

- 40 cases of clinically suspected interstitial lung diseases were evaluated in the department of Radiodiagnosis, Medical College Kolkata from 1st January 2017 to 31st December 2017. High Resolution Computed Tomography and chest radiographs were used as tools to evaluate the cases.
- In our study, 37.5% of the cases were in the 6th decade, followed by 20% cases in the 5th decade. The youngest patient in our study was 20 years old with pulmonary Koch's and oldest case was 75 years old who had idiopathic pulmonary fibrosis.
- Cases with pulmonary Koch's were the largest group in our study, constituting 27.5% of total number of cases, followed by progressive systemic sclerosis and rheumatoid arthritis (17.5%) each.
- The most number of cases of Pulmonary Koch's infection were noted in 3rd and 4th decade of life. The most number of cases with rheumatoid arthritis and progressive systemic sclerosis were in 5th and 6th decades.
- 24 of the cases were females constituting 60% of the cases, and 16 were males constituting 40%. Rheumatoid arthritis, progressive systemic sclerosis and systemic lupus erythematosus were more in females. Idiopathic pulmonary fibrosis and pulmonary Koch's infections were common in males.
- Nodular opacities were seen in Rheumatoid arthritis, progressive systemic sclerosis, BOOP, pulmonary Koch's and sarcoidosis. The distribution of the nodules were centrilobular/random. In our study, tree in bud appearance was seen in 72.72% of cases with pulmonary Koch's.
- Linear and reticular opacities were seen in almost all the cases to different extent with maximum being in idiopathic pulmonary fibrosis, rheumatoid arthritis and progressive systemic sclerosis.
- Decreased lung opacities were seen in our study in the form of air-trapping, bronchiectasis and emphysema. Air trapping was seen in RA, BOOP and desquamative interstitial pneumonia. Emphysematous changes were noted mainly in pulmonary Koch's and progressive systemic sclerosis. Bronchiectasis was seen in pulmonary Koch's, followed by progressive systemic sclerosis and IPF. Honey-combing was seen in most cases of RA, IPF and progressive systemic sclerosis.
- Increased lung opacities were seen in the form of ground glass opacities and associated consolidation. Ground glass opacities were seen mainly in DIP, IPF, BOOP and progressive systemic sclerosis. In our study, consolidation was seen mainly in BOOP and pulmonary Koch's.
- We compared the diagnostic accuracy of HRCT scans and chest radiography in diagnosing interstitial lung diseases. We found that HRCT was more sensitive and specific than chest radiographs in diagnosing interstitial lung diseases. The finding in our study correlated well with the study of Padley et al in 1991.⁷
- Moreover HRCT helps us in assessing the disease extent as well as prognosis.

V. Conclusion

From this preliminary study of 40 cases of interstitial lung diseases using HRCT and chest radiographs, the following conclusions were obtained:

- Chest radiographs remain the first line of investigation in evaluation of ILDs due to its wide availability and low cost. More often, it helps to narrow down the differential diagnoses to a few possibilities.
- However, most detailed and precise diagnostic conclusion can be made only with HRCT scans, because HRCT scans can reveal up to the level of secondary pulmonary lobule, thereby closely correlating with histopathology. HRCT is more sensitive and specific in diagnosing most of the ILDs. Moreover, it helps us in describing disease extent and prognosis.
- Therefore we conclude that HRCT scan is the best non-invasive diagnostic modality in the evaluation of interstitial lung disease.

References

- [1]. Coultas DB, Zumwalt RE, Black WC, et al. The epidemiology of interstitial lung diseases. *Am J Respir Crit Care Med* 1994; 150:967-972
- [2]. Nakata H., Kimoto T, Nakayama T, et al. Diffuse peripheral lung disease: evaluation by HRCT. *Radiology* 1985; 157:181-185
- [3]. Zerhouni EA, Naidich DP, Siegelman SS, et al. Computed tomography of the pulmonary parenchyma. Part 2: interstitial disease. *J Thoracic imaging* 1985; 1(1):54-56
- [4]. Mayo JR, High resolution computed tomography: technical aspects. *Radiol Clin North Am* 1991;29:1043-1049
- [5]. Muller NL, Miller RR. Computed tomography of chronic diffuse infiltrative lung disease: part 1. *Am Rev Respir Dis* 1990;142:1440-1448
- [6]. Mayo JR, Webb WR, Gould R, et al. High resolution CT of the lungs: an optimal approach. *Radiology* 1987;163:507-510
- [7]. Padley SPG, Hansell DM, Flower CDR, et al. Comparative accuracy of high resolution computed tomography and chest radiography in the diagnosis of chronic diffuse infiltrative lung disease. *Clin Radiol* 1991;44:222-226
- [8]. Jacob J, Hansell DM: *Respirology*. 2015 Aug;20(6):859-72. doi: 10.1111/resp.12531. Epub 2015 Apr 21
- [9]. Pankaj Badarkhe-Patil, Dayanand Kawade, Prashant Titare, Varsha Rote- Kaginalkar. HRCT assessment of interstitial lung diseases. *International Journal of Contemporary Medical Research* 2016;3(8):2426-2430.

ABBREVIATIONS:

ARDS- Adult respiratory distress syndrome
ANA- Anti-nuclear antibody
BOOP-Bronchiolitis obliterans organizing pneumonia
COP- Cryptogenic Organizing pneumonia
DIP-Desquamative interstitial pneumonia
ESR-Erythrocyte sedimentation Rate
GGO- Ground glass opacity
HRCT- High Resolution Computed Tomography
IPF- Idiopathic Pulmonary Fibrosis
Ig- Immunoglobulin
PAP- Pulmonary Alveolar Proteinosis
PSS-Progressive Systemic Sclerosis
SLE- Systemic Lupus Erythematosus

Dr. Avereer Gangopadhyay. , "Spectrum of Findings on HRCT in Evaluation of Interstitial Lung Diseases: A Single Centre Prospective Observational Study." " IOSR Journal of Dental and Medical Sciences (IOSR-JDMS), vol. 17, no. 11, 2018, pp 53-63.