

## Giant Lipomas: A Report of Two Cases and Brief Review of Literature

Dr. Deshraj Chawla<sup>1</sup>, Dr. Sunil Kumar Mehra<sup>2</sup>, Dr. Neeraj Kumar Dewanda<sup>3</sup>,  
Dr. Harsh Kumar<sup>4</sup>, Dr. Shivcharan Bairwa<sup>5</sup>, Dr. Amit Saxena<sup>6</sup>, Dr. Sanjay  
Kharoliwal<sup>7</sup>, Dr. Rohit Soni<sup>8</sup>

<sup>1,4</sup> Assistant Professor, Department of General Surgery, Government Medical College, Kota, India.

<sup>2</sup> Consultant Pediatric Surgeon, Jhalawar, Rajasthan, India.

<sup>3</sup> Professor and Unit Head, Department of General Surgery, Government Medical College, Kota, India.

<sup>5,8</sup> Junior Resident, Department of General Surgery, Government Medical College, Kota, India.

<sup>6</sup> Senior Resident, Department of General Surgery, Government Medical College, Kota, India.

<sup>7</sup> SMO, Department of General Surgery, Government Medical College, Kota, India.

Corresponding author: Dr. Deshraj Chawla

**Abstract:** Giant lipomas involving the extremities are rare tumors. These large masses grow slowly and produce symptoms due to their size, location and compression of adjacent structures. Here we present two interesting cases of giant lipomas, one on the left shoulder of eight year duration and other on the right gluteal region of 30 year duration. The lipomas were surgically excised with complete return of normal form and function.

**Key word:** Giant lipoma, surgical excision.

Date of Submission: 03-11-2018

Date of acceptance: 17-11-2018

### I. Introduction

Lipoma is one of the commonest tumor in the body (1, 2). They are common on the trunk and extremities (1). They are usually subcutaneous, however they can occur in any tissue plane including internal organ. Giant lipomas are rare entities (2). Being large in size, they can cause compression of the neighboring structures causing neurovascular disturbances (2). Here we present two interesting cases of giant lipomas, one on the shoulder and other on the gluteal region.

### II. Case Reports

#### case 1

A 42-year old male presented with a swelling on the left shoulder (Fig1A) of eight year duration, which was progressively increasing in size. It was initially painless, but the patient developed dull aching pain in the swelling, associated with difficulty in the shoulder movements, for the last two months. He was also worried about malignancy. General physical and systemic examinations were normal.

Local examination revealed a swelling of size 12×10×4.5 cm. mainly on the anterior aspect of the left shoulder and extending to the left upper anterior chest wall (Fig1A). It was non-tender, ovoid shaped, soft in consistency, smooth surface with well-defined margins and mobile in all direction. The patient had restricted abduction of the left shoulder. Rest of the shoulder movements and neurovascular examination of the chest and left upper limb was normal. X-ray of left shoulder joint was normal

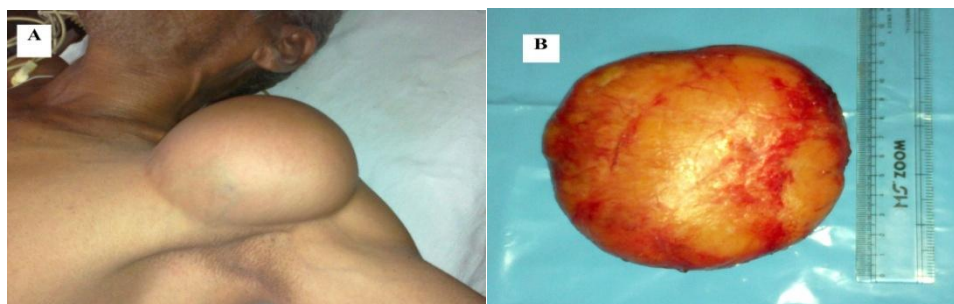
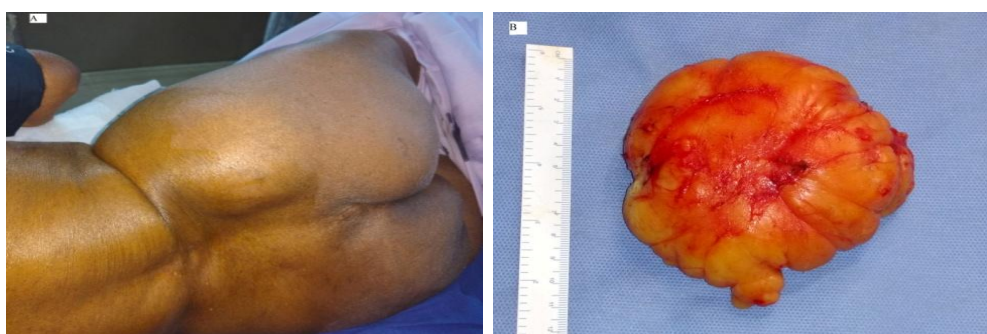

Fig.1: (A) Clinical picture of left shoulder lipoma (B) excised specimen of lipoma.

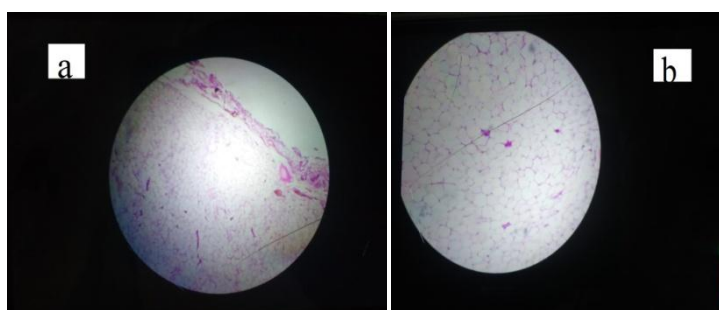
**case 2**

A 75 –year old female presented with a swelling on the right gluteal region (Fig2A) of 30 year duration, which was progressively increasing in size. It was initially painless, but developed dull aching pain in the swelling associated with difficulty in the sitting in last three monts. Local examination revealed a swelling of size 11 ×10×4 cm on the right gluteal region (Fig2A). It was non-tender, ovoid shaped, soft in consistency, smooth surface with well defined margins and mobile in all direction. Hip movements were normal. X-ray of pelvis with hip joint was normal.



**Fig-2 (A) Giant lipoma on the right gluteal region (B) excised specimen of lipoma**

Fine needle aspiration cytology (FNAC) of both swellings was suggestive of lipoma. Both patients were surgically explored under general anesthesia. A 12×10×4.5cm in first patient and 11×10×4cm in second patient, well circumscribed, encapsulated, fatty swelling situated in the subcutaneous plane was found with no evidence of infiltration of surrounding structures. Excision biopsy was done (Fig1B, 2B). Histopathological examination confirmed both swellings to be lipoma (Fig3a, 3b). In subsequent follow-up of 1 year, there was no evidence of local recurrence or restriction of movement of joints in both patients.



**Fig-3(a,b): histopathological examination of the lipoma revealed mature adipocytes accompanied by small vessels.**

### **III. Discussion**

Lipomas are one of the commonest benign soft tissue tumors in the body (2). They are mainly composed of mature adipose cells (2). Lipomas can be found in almost all organ of the body where fat normally exists and are, therefore, known as ubiquitous or universal tumors (3). Giant lipomas were defined by Sanchez as size of at least 10 cm in one dimension, or a minimum of 1000 gm. in weight (4). Treatment of lipoma is usually not necessary (1) but in case of a giant lipoma excision is required due to concerns of malignancy, cosmetic appearance, inability to wear clothes and restriction of limb movements. Surgery is the treatment of choice for these giant swellings due to their size, tendency to recur, and potential hazard of malignant transformation (5). Other modality of treatment includes liposuction and lipolysis using injection or ultrasound waves (1). Intraoperatively, the surgical dissection is easier and uncomplicated in long standing lipomas due to formation of a well-defined pseudo capsule as a result of continuous pressure on the surrounding tissue (2). Regular follow-up is required due to risk of recurrence (2). Histopathologically there is no difference between giant and normal lipoma.

### **IV. Conclusion**

Giant lipomas are rare tumours. They should be surgically excised due to concerns of malignancy, disability and have comparatively easy surgical excision.

#### **References**

- [1]. A.B. Panchani., A.R Shojai , R. Gautam ,M.Topno, A. Panchal.et al (2010) A giant congenital lipoma over the back. Indian J Surg 72(suppl 1):361-362
- [2]. C. Balakrishnan, D.Nanavati, A. Balakrishnan, T.Pane, (2012) Giant lipoma of the upper extremity: case report and a literature review. Can J Plast Surg; 20(3):e40-e41
- [3]. Devis C Jr, Gruhn JG. (1967) Giant lipoma of the thigh. Arch Surg; 95: 151 -6.
- [4]. Sanchez MR, Golomb FM, Moy JA,Potozkin JR (1993) Giant lipoma: Case report and review of the literature. J Am Acad Dermatol 28:266-268.
- [5]. Terzioglu A, Tuncali D, Yuksel A, Bingul F,Aslan G(2004) Giant lipoma: A series of 12 consecutive cases and a giant liposarcoma of thigh. Dermatol Surg; 39:463-467

Dr. Deshraj Chawla. "Giant Lipomas: A Report of Two Cases and Brief Review of Literature.."  
IOSR Journal of Dental and Medical Sciences (IOSR-JDMS), vol. 17, no. 11, 2018, pp 15-17.