

Uncovering Buccally Impacted tooth by Periodontal Plastic Surgery –A Case Report

Saswati Mukherjee Das ¹ · Ujjwal Das ²

¹ Assistant Professor, Burdwan Dental College and Hospital, West Bengal, India.

² Assistant Professor, Burdwan Dental College and Hospital, West Bengal, India

Corresponding Author: Saswati Mukherjee Das

Abstract: The aim of this case report was to preserve tissue for future attached gingiva of a buccally impacted left maxillary permanent canine tooth in a 14 years old female patient by apically displaced flap surgery (one type of periodontal plastic surgery). **Case Presentation :** A 14 years old girl presented with chief complaint of previously surgically exposed tooth in the left upper region was again covered within three months of previous surgery. Combined periodontal flap surgery and orthodontic treatment was performed to correct dental impaction and to achieve proper alignment of teeth in dental arch. **Conclusion:** The apically repositioned flap is an effective method of exposing certain unerupted teeth while maintaining the mucogingival complex.

Keywords: Apically displaced flap, Periodontal plastic surgery, Attached gingiva, Orthodontics, Unerupted

Date of Submission: 28-10-2018

Date of acceptance: 14-11-2018

I. Introduction

Within a healthy oral environment teeth are surrounded by a zone of keratinized gingiva. The part of keratinized gingiva, which is known as attached gingiva, is defined as that gingiva extending from the free margin of the gingiva to the mucogingival line minus the pocket or sulcus depth measured with a thin probe in the absence of inflammation. Attached gingiva is considered necessary for a healthy periodontium because it has evolved to withstand the forces of mastication and other oral functions. Therefore, when choosing the method of surgical exposure it is important to ensure maintenance of the mucogingival complex if at all possible. Methods of exposing impacted teeth in order to bring them into the line of the arch include gingivectomy, the apically repositioned flap and closed eruption techniques. Among all of these procedures only the apically repositioned flap allows to maintain the mucogingival complex, mainly the width of attached gingiva. Periodontal plastic surgery is defined as the surgical procedures performed to correct or eliminate anatomic, developmental, or traumatic deformities of the gingiva or alveolar mucosa (3,4). Apically repositioned flap procedure is one type of periodontal plastic surgery.

A tooth is considered “impacted” when it fails to erupt in the dental arch within the expected developmental window. Teeth may become impacted because of adjacent teeth, dense overlying bone, excessive soft tissue, or genetic abnormalities. The third molars are most frequently impacted (20 to 30 %) because they are the last teeth to erupt in the oral cavity, followed by the maxillary canines (85 % with palatal dislocation), mandibular second premolars (0.3 %), and central maxillary incisors (0.1 %) [5-8]. Confirmation that the tooth is labially impacted may be obtained through visualization, digital palpation and radiographic localization.

II. Case Presentation:

A 14 years old girl presented with chief complaint of previously surgically exposed tooth in the left upper region was again covered within three months of previous surgery. (Fig 1, Fig 2 and Fig 3)

Past dental history revealed surgical exposure of left impacted maxillary canine was done three months back and orthodontic bracket was inserted in same appointment in maxillary left canine.

An extraoral examination revealed no significant facial asymmetry.

An intraoral examination showed Plaque Index score 1, Calculus Index score 1 and Gingival Index score 1 and left maxillary deciduous canine was present in the between left permanent lateral incisor and left permanent first premolar. Orthodontic bracket was covered by alveolar mucosa. (Fig 1 and Fig 2) On palpation a bony hard swelling revealed apical to the left maxillary deciduous canine. The width of attached gingiva buccal to the left maxillary deciduous canine was approximately 7 mm. (Fig 11) Orthopantomograph showed impacted left maxillary canine apical to the left first maxillary premolar (Fig 4). Intraoral periapical radiograph showed 23 placed distobuccal to 24 (Fig 5). Routine blood investigations were within normal limit.

Oral hygiene instructions was given on first visit. Scaling and root planing was completed in next two visits. Extraction of 63 was done under local anaesthesia (1:200,000 lidocaine hydrochloride with adrenaline). After 7 days, surgical exposure of 23 by apically displaced partial thickness flap was performed under local anaesthesia and suture given.(Fig 6, Fig 7, Fig 8, Fig 9). Periodontal dressing was given. The medications prescribed were, Amoxicillin (500 mg) thrice a day for 5 days and a combination of ibuprofen (400mg) and paracetamol (325mg) twice daily for 3 days. Post operative instructions were given and she was instructed to report after 24 hours of surgery and then after 7 days. After 7 days, suture was removed and orthodontic traction was applied to erupt the tooth. (Fig 10) The patient is being followed on 5 months, 7 months and 1 year 3 months after surgery. Significant amount of attached gingiva was created apical to the 23. (Fig 12, Fig 13 and Fig 14)

III. Discussion:

In the exposure of impacted teeth it is important to maintain the mucogingival complex to help ensure the healthy long-term periodontal status of the tooth.

To create a satisfactory width of the gingiva for the permanent tooth, the tissue entrapped between the erupting tooth and the deciduous tooth is usually utilized as donor tissue. (9 -10) For successful implementation of this procedure partial thickness flap elevation is main requisite. Thick gingival biotype is another important criteria for partial thickness flap elevation along with surgical skill. It requires little more time than normal gingivectomy procedure. But the end result of this procedure is aesthetically as well as functionally acceptable than any other procedures.

Gingivectomy technique is simple and quick to carry out but sacrifices healthy attached gingiva and may increase the risk of detrimental changes in the periodontal tissues.(11)

In situations where the labially impacted tooth is positioned very high within the buccal sulcus, near to the nasal spine or deep within the alveolus, an apically repositioned flap may be difficult to use. (12) In these clinical situations the surgical method of choice is the closed eruption technique. The disadvantage of this technique is that once the flap has been replaced no direct inspection of the tooth can be made.(13)

IV. Conclusions:

The purpose of this case report was to describe the apical reposition partial thickness flap surgery for exposure of permanent maxillary canine for orthodontic purpose in a 14-year-old girl. The advantage of this procedure over gingivectomy is it can allow preserving tissue for future attached gingiva and there will be no vestibular shortening. Good aesthetic and functional results were achieved within reasonable time period.

References

- [1]. Hall WB. The current status of mucogingival problems and their therapy. *J Periodontol* 1981; **62**: 569.
- [2]. Lawton H, Sandler PJ. The Apically Repositioned Flap in Tooth Exposure. *Dental Update* 1999; July/August: 236
- [3]. American Academy of Periodontology: Proceedings of the World Workshop in Clinical Periodontics July 23-27, Chicago, 1989, American Academy of Periodontology.
- [4]. American Academy of Periodontology: Proceedings of the 1996 World Workshop in Periodontics, Lansdowne, Virginia, July 13-17. *Ann Periodontol* 1(1):1-947, 1996.
- [5]. Chiapasco M, Crescentini P, Garattini G, Meazzini MC. *Manuale illustrato di Chirurgia Orale*. 2005.
- [6]. Gyulai-Gaal S, Mihalyi S, Martonffy K, Suba Z. Etiology and diagnostic of upper canine tooth retention. *Fogorv Sz.* 2010;103(2):49-52.
- [7]. Olive RJ. Orthodontic treatment of palatally impacted maxillary canines. *Aust Orthod J.* 2002;18:64-70
- [8]. Dinoi MT, Lacarbonara M, Dimartino S, Monaco A, Marzo G. Periodontal probing of a impacted tooth recovered through a surgical-orthodontic approach: a case report. *J Med Case Rep.* 2014. doi:10.1186/1752-1947-8-25.
- [9]. Agudio, G., Pini Prato, G., De Paoli, S. & Nevins M. (1985). Mucogingival interceptive therapy. *International Journal of Periodontics and Restorative Dentistry* **5**, 49 – 59.
- [10]. Pini Prato, G.P., Baccetti, T., Magnani, C., Agudio, G. & Cortellini, P (2000b). Mucogingival interceptive surgery of buccally erupted premolars in patients scheduled for orthodontic treatment. I. A seven- year longitudinal study. *Journal of Periodontology* **71**, 172-181.
- [11]. Shiloah J, Koczyk R. Mucogingival considerations in surgical exposure of maxillary impacted canines. *J Dent Child* 1978; **45**: 79-81.
- [12]. Kokich VG, Matthews DP. Surgical and orthodontic management of impacted teeth. *Dent Clin North Am* 1993; **37**: 181-204.
- [13]. Wisth PJ, Norderval K, Boe OE. Comparison of the surgical methods in combined surgical- orthodontic correction of impacted maxillary canines. *Acta Odont Scand* 1986; **34**: 52-57.

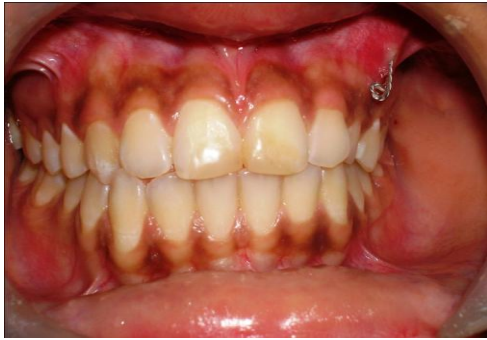

Fig 1 Initial frontal view

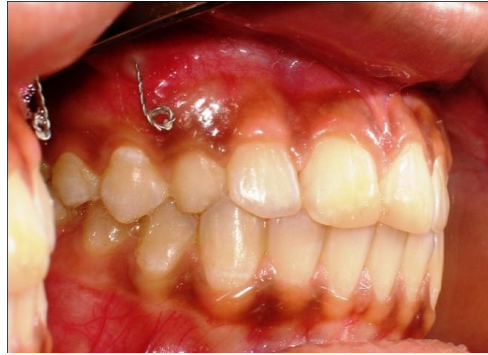

Fig 2 Initial buccal view

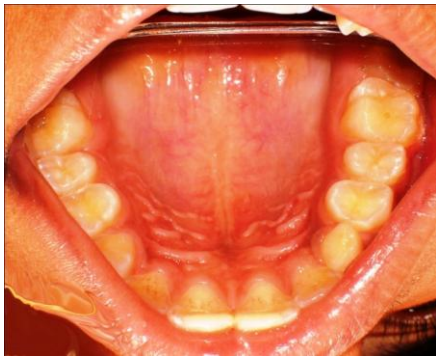

Fig 3. Palatal view

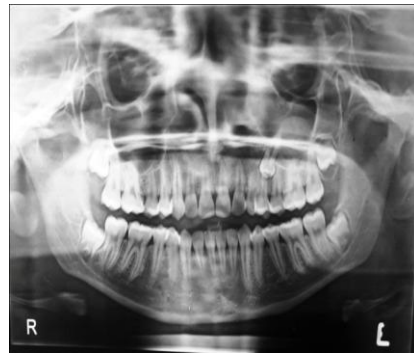

Fig 4. Digital Orthopantomograph

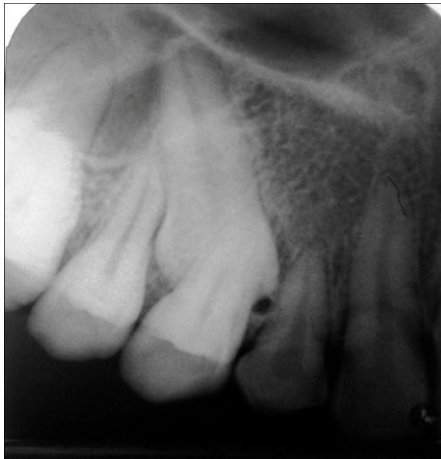

Fig 5 Intraoral periapical radiograph

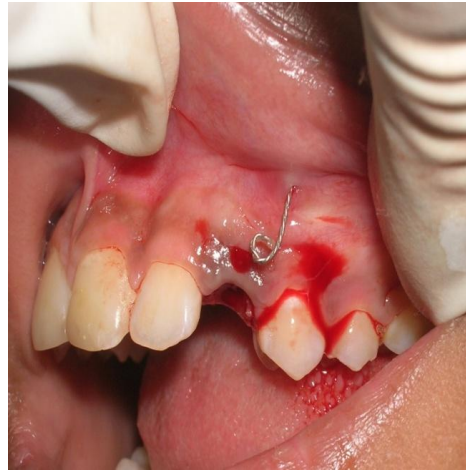


Fig 6 Initial Incision

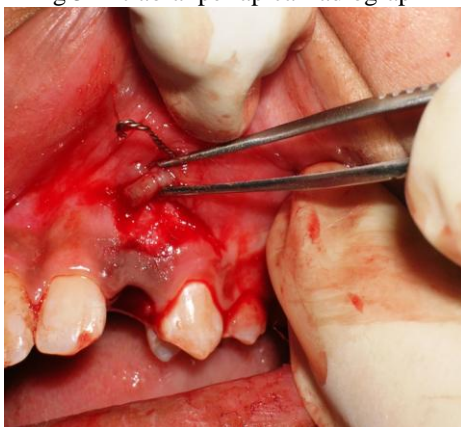

Fig 7 Partial thickness flap elevation

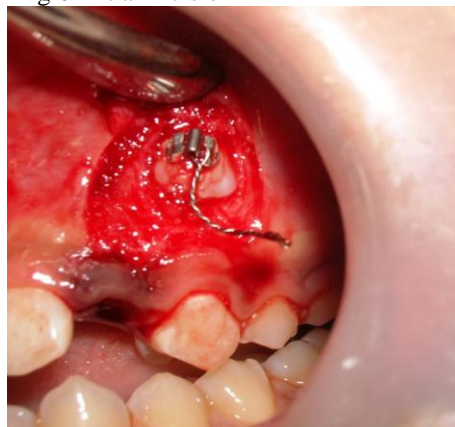


Fig 8 After canine exposure

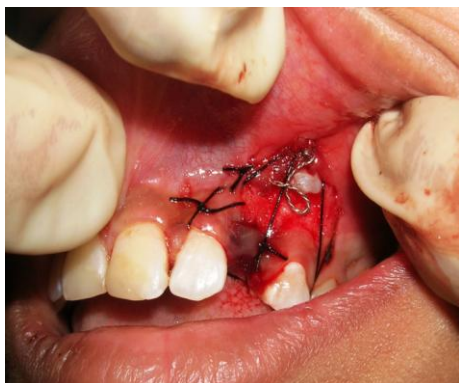

Fig 9 After suturing

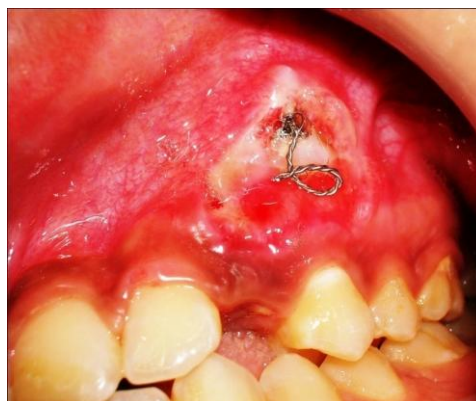

Fig 10 After 7 days of suture removal

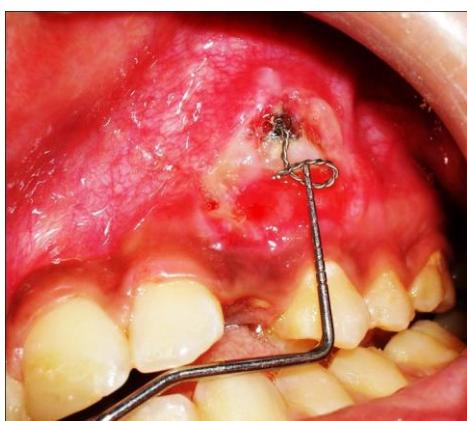

Fig 11 width of keratinized gingival

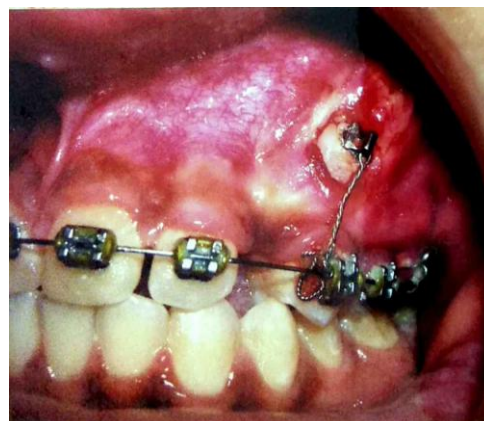

Fig 12 After 5 months

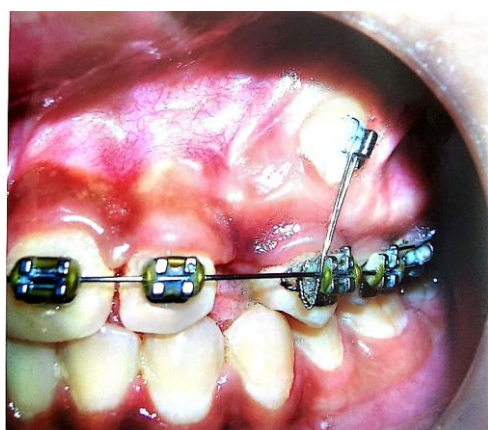


Fig 13 After 7 months of Orthodontic Therapy

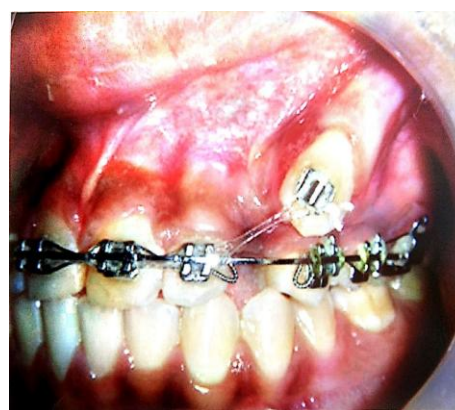

Fig 14 After 1 year and 3 months of Orthodontic Therapy

Saswati Mukherjee Das. "Uncovering Buccally Impacted tooth by Periodontal Plastic Surgery – A Case Report." IOSR Journal of Dental and Medical Sciences (IOSR-JDMS), vol. 17, no. 11, 2018, pp 57-60.