

Severe Human parainfluenza type 2 virus pneumonitis in immunocompetent host; A case series of 10 patients

Vinay tuteja, C.L. nawal, R.S chejara, Aradhanasingh, Rajbeersingh

Corresponding author: Rajbeersingh

Abstract

Background: Human parainfluenza viruses are the major cause for respiratory illness in human and among HPIV type 2 rarely affect an immunocompetent host. A changing pattern of clinical spectrum of this virus type can pose a serious threat in the future.

Patients and Methods: We report 10 patients who were admitted to our institute with extensive involvement of lower respiratory tract and were found to be positive for HPIV type 2 virus during a period of 6 months from February 2018 to August 2018. The diagnosis was confirmed by PCR from throat swab and after exclusion of any immunocompromised state of the patient.

Results: All patients initially presented with fever, severe respiratory difficulty and Positive throat swab PCR for Human parainfluenza virus type 2 strain also all patients were screened for H1N1, scrub typhus and other causes of bilateral pneumonitis which are quite common in the geographical area. Blood investigations showed variable total leukocyte count, elevated liver enzymes (n=7) and chest radiograph showing bilateral infiltrate (n=10), three out of ten required ventilator support and two patients died of this disease who were critically ill.

Conclusions: Human parainfluenza virus type 2 not only involves an immunocompetent host but can be associated with high mortality rate if not managed aggressively.

Key words: HPIV type 2, bilateral pneumonitis.

Date of Submission: 12-10-2018

Date of acceptance: 27-10-2018

I. Introduction:

Human parainfluenzavirus (HPIV) is single-stranded, enveloped RNA viruses related to respiratory syncytial virus (RSV) that belongs to the Paramyxoviridae family. Based on antigenic and genetic characteristics HPIV is broadly divided into four major serotypes.

HPIV is the second most common cause of acute viral lower respiratory tract infections in children¹. In adults, HPIV infections are rare and usually cause only mild upper respiratory infections. However, in an immunocompromised patients (such as patients with haematological malignancies and bone marrow transplant patients, HIV etc), this virus can induce life-threatening lower respiratory tract infections.²⁻³ It is known that HPIV types 1-4 primarily involve paediatric age group and a common cause of laryngotracheobronchitis in young children.⁴ In adults, HPIV2 is a recognized cause of community-acquired pneumonia (CAP) in immunosuppressed patients or transplant recipients mainly⁴.

Very commonly bilateral pneumonitis can be an etiological diagnostic dilemma which requires a battery of tests. Most common differentials include infective (streptococcus, Respiratory syncytial virus, H1N1, scrub typhus etc.) as well as non-infective (Pulmonary edema, Acute respiratory distress syndrome etc.) causes.

We report a case series of 10 cases of severe infection secondary to HPIV-2 who were immunocompetent, had severe respiratory illness and required aggressive management even, intensive care for some of the patients at a certain point of time.

II. Patients And Methods

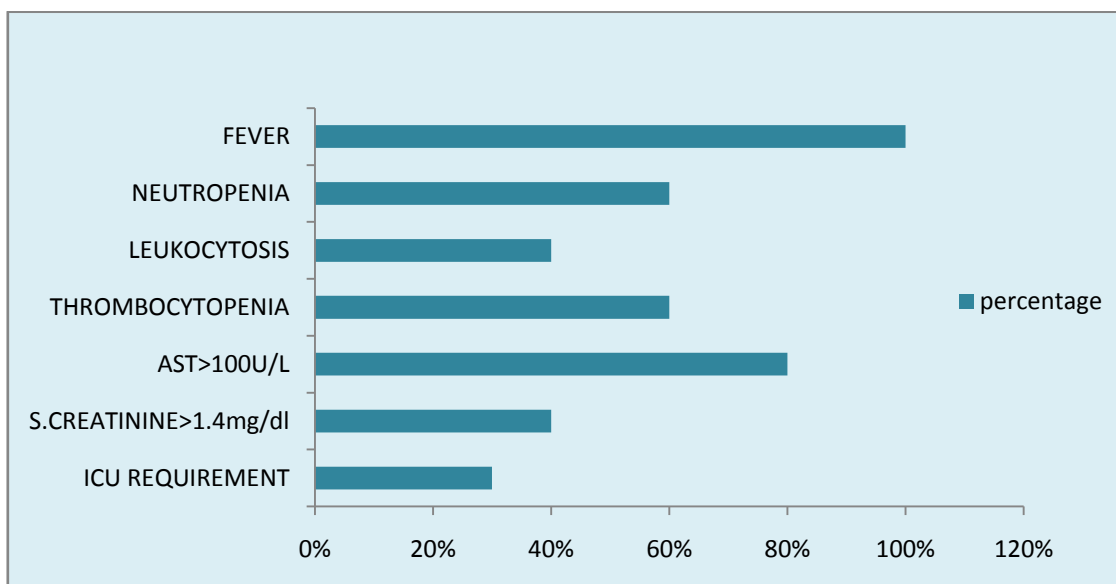
We studied ten cases infected with Human parainfluenza virus type 2, who came to Sawai Man Singh hospital between February 2018 to September 2018. All these patients were of different ages with mean age of 32.7 years and six of them were male and rest were female. The presenting complaints of the patient were similar, that is high grade fever with varying degrees of respiratory distress. However, the outcome of the disease was different in these patients as some patients had a benign course of the disease and others had severe complications leading to death.

All of these patients underwent routine investigation like complete blood count, renal function tests, liver function tests, chest x-rays and also specific tests as PCR for influenza, adenovirus, RSV, scrub typhus IgM antibody to rule out other causes of bilateral pneumonitis and respiratory distress.

The diagnosis was confirmed with PCR for Human parainfluenza virus type 2 from throat swab.

III. Results

All patients initially presented with fever, most being referred cases from primary health clinics after failing to respond to antibiotics and antipyretics. All patients had respiratory distress at presentation (100%) but of varying severity, six had neutropenia (60%) while rest four had leukocytosis. Four had thrombocytopenia (40%) and rest six had normal platelet count. Four of them had raised serum creatinine (40%) and rest six had normal renal function test. Six out of ten had AST levels >100 U/L (60%) while other four had normal serum AST levels. (fig 1)



All of the ten patients had bilateral opacities in chest x-rays. All of the patients were tested for any immunocompromised state that is they were tested for HIV, diabetes mellitus and chronic illnesses. High resolution CT showed bilateral haziness of lung fields in all ten patients but with variable area of involvement. Eight of these patients recovered very well with supportive care but two of these patients developed complications and died despite of all our best efforts. (Table 1)

Patients characteristic:

#	Age in years	Gender	H1N1	HIV	Any chronic disease	Scrub typhus	Outcome
1	28	M	Negative	Negative	None	Negative	Completely recovered
2	23	M	Negative	Negative	None	Negative	Completely recovered
3	46	M	Negative	Negative	Hypertension	Negative	Completely recovered
4	19	F	Negative	Negative	None	Negative	Completely recovered
5	38	M	Negative	Negative	None	Negative	DIED
6	50	M	Negative	Negative	Hypertension	Negative	Completely recovered
7	54	F	Negative	Negative	Old Healed tuberculosis	Negative	DIED
8	16	M	Negative	Negative	None	Negative	Completely recovered
9	20	F	Negative	Negative	None	Negative	Completely recovered
10	33	F	Negative	Negative	None	Negative	Completely recovered

Table 1: Various parameters of the patients infected with HPIV type 2 virus

IV. Discussion:

In our study we collected data from 10 patients who were infected with HPIV type 2 and all of them had severe respiratory illness, which is not so common as described in literature. We came across three critically ill patients out of which two died in the disease process which is very rare with HPIV type 2 infections. HPIV-2 causes all of the typical lower respiratory infections (LRI) syndromes, but in nonimmunocompromised or chronically ill children, croup is the most frequent syndrome brought to medical attention, however in our cases all the patients were not having an obvious immunocompromising disease state. LRI caused by this virus has been reported much less frequently than with HPIV-1 and HPIV-3⁵.

HPIV-2 can cause giant-cell pneumonia in severe combined immunodeficiency syndrome (SCIDS).⁵ Throat swabs, nasopharyngeal swabs and nasal aspiration have all been used successfully to recover HPIV.^{6,7}

These respiratory tract pathogens can infect individuals of any age group. HPIVs are not only a common viral cause of community-acquired pneumonia in the immunocompromised adults⁸ but also are one of the most common viral causes of pediatric hospitalizations, accounting for nearly one-third of lower respiratory infections in children under 5 years.⁸ Various immunocompromising factors (e.g., bone marrow transplantation) and HPIV related illness (e.g., type 3) have been linked to worse outcomes and outbreaks.⁹⁻¹²

Presently, no vaccine or treatment is available for this pathogen.¹³ The treatment is mainly supplementary with respiratory support and aggressive management including ICU care when indicated. In our study three patients required ICU care, out of which two died of the severe respiratory efforts despite best of our efforts.

V. Conclusion

Our study shows that Human parainfluenza virus type 2 which is previously known to cause severe respiratory illness in immunocompromised host, can also affect a previously healthy immunocompetent host and can prove to be associated with high mortality rate, if not managed aggressively. This shows a changing pattern of the disease and can prove to be lethal in near future. These findings require further evaluation and large scale study to look for the definite change in the pattern of the disease.

References:

- [1]. Hall CB. RSV and parainfluenza virus. *N Engl J Med* 2001; 344: 1917–28.
- [2]. Marcolini JA, Suki D et al. Parainfluenza virus in adult leukemic patients. *Eur J Clin Microbiol Infect Dis* 2003; 22: 79–84.
- [3]. Chemaly RF et al. Respiratory viral infections in adults with hematologic malignancies and human stem cell transplantation recipients 2006; 85: 278–87
- [4]. Cunha BA, Perez FM, Stollo S. H1N1: diagnostic dilemmas early in the pandemic. *Scand J Infect Dis.* 2009;41(11-12):900-2.
- [5]. Karp, J. Willis, and C. M. 1974. Parainfluenza virus II and the immunocompromised host. *Am. J. Dis. Child.* 127:592–593.
- [6]. Gardner, S. D. 1969. The isolation of HPIV type 4 subtypes A and B and study of their prevalence. *J. Hyg.* 67:545–550.
- [7]. Glezen, W. P., A. L. Frank 1984. HPIV type 3: seasonality and risk of infection and reinfection in children. *J. Infect. Dis.* 150:851–857
- [8]. Henrickson KJ. Parainfluenza viruses. 2003; 16:242–264.
- [9]. Reed G et al. Epidemiology and clinical variability of HPIV infections in otherwise healthy infants and children.
- [10]. Grattan-Smith et al 1987. Viral supraglottitis. *J. Pediatr.* 110:434–435
- [11]. Sydnor ER, Greer A, Budd AP et al. An outbreak of HPIV 3 infection in hematopoietic stem cell transplantation clinic. *Am J Infect Control* 2012; 40:601–605
- [12]. Chemaly RF, Rathod DB et al. outcomes of parainfluenza virus infections in patients with leukemia or recipients of hematopoietic stem cell transplantation. *Blood* 2012; 119:2738–2745. quiz 969.
- [13]. Ambrose, M. W et al 1991. Evaluation of the immunogenicity and protective efficacy of a candidate HPIV 3 subunit vaccine. *Vaccine* 9:505–511.

Rajbeersingh.. “Severe Human parainfluenza type 2 virus pneumonitis in immunocompetent host; A case series of 10 patients... ” *IOSR Journal of Dental and Medical Sciences (IOSR-JDMS)*, vol. 17, no. 10, 2018, pp 31-33.