

## Zimmermann-Laband syndrome – A rare case report.

Dr. Jeseem M T<sup>1</sup>, Dr. Kannan Vadakkepurayil<sup>2</sup>, Dr. Jithin Jose<sup>3</sup>, Dr. Rashmi K B<sup>4</sup>

<sup>1</sup>(Department of Pedodontics and Preventive Dentistry, Government Dental College Kozhikode, Kerala)

<sup>2</sup>(Department of Pedodontics and Preventive Dentistry, Government Dental College, Kozhikode, Kerala)

<sup>3</sup>(Department of Pedodontics and Preventive Dentistry, Government Dental College, Kozhikode, Kerala)

<sup>4</sup>(Department of Pedodontics and Preventive Dentistry, Government Dental College, Kozhikode, Kerala)

Corresponding Author: Dr. Jeseem M T

**Abstract:** Zimmermann-Laband syndrome is a rare autosomal dominant inherited disease characterized by extensive gingival enlargement and abnormalities of the head, face, hands, feet, nose, and ears. Hypoplastic or absent nails, mild hirsutism, hepato-splenomegaly and mental retardation are seen in some cases. The present paper describes a female patient, aged eight years, with typical features of Zimmermann-Laband syndrome and its dental management.

**Keywords:** Zimmermann-Laband syndrome, gingival fibromatosis.

Date of Submission: 05-10-2018

Date of acceptance: 20-10-2018

### I. Introduction

Gingival overgrowth or enlargement or hyperplasia is referred to as an increase in the number of the cells of the gingiva, resulting in an overgrowth that may partially or totally cover the teeth. The gingival overgrowth in children may be due to hereditary gingival fibromatosis, drug-induced gingival overgrowth (Phenytoin, Carbamazepine, cyclosporine, nifedipine, amlodipine etc.), neurofibromatosis I, leukemic gingival infiltrates, gingival hyperplasia as a manifestation of Hodgkin's lymphoma, sweet-like syndrome and Schinzel-Giedion syndrome(1)(2).

Hereditary gingival fibromatosis is an inherited disease in which the gingival tissue progressively enlarge and may completely cover the occlusal surfaces of the teeth(3). In most cases hereditary gingival fibromatosis is not associated with any systemic diseases; but rarely it may also be associated with some eponymous syndromes like Murray-Puretic-Drescher syndrome (multiple- hyaline tumors), Rutherford syndrome (corneal dystrophy), Jones syndrome (sensorineural hearing loss), Ramon syndrome (hypertrichosis, cherubism, mental and somatic retardation), Cowden syndrome (multiple hamartomas), cross syndrome (hypopigmentation with athetosis) etc(4)(5). One such rare disorder is Zimmermann-Laband syndrome which comes under the category of hereditary gingival fibromatosis and is characterized by gingival fibromatosis, abnormalities of the nose and ears, hyper-extensible joints and hypoplastic changes in the nails or in terminal phalanges of the fingers and toes. Other associated features of this syndrome includes macroglossia, thick lips, speech defects, hirsutism, retinitis pigmentosa, seizures, spina bifida occulta, high foot arch, hepato-splenomegaly and mental retardation(4).

The Zimmermann-Laband syndrome also known as Laband-Zimmermann syndrome or Laband's syndrome was first reported by Zimmermann in the year 1928(6) and later again by Jacoby et al(7) in 1940. Laband et al described the first familial occurrences of this syndrome in 1964(8). Zimmermann-Laband syndrome mostly has an autosomal dominant mode of inheritance and has a variable phenotype(9); however, evidence for autosomal recessive inheritance exists as well. This study reports an isolated case of Zimmermann-Laband syndrome in an eight year old female patient and its dental management.

### II. Case report

An eight year-old girl was reported to the Department of Pedodontics, Govt Dental College Kozhikode, Kerala with a complaint of unerupted teeth and excessive gingival overgrowth in the anterior region of the mouth. Intra-oral examination showed a pale-pink firm enlargement of gingiva involving the maxillary and the mandibular arches and mild marginal gingivitis. The diffuse gingival enlargement involving the buccal and palatal gingiva of 11, 21, 31 and 41 almost prevented its normal eruption (Figure 1A, 1B and 1C).

Extra-oral examination revealed thick ears and lips, bulbous soft nose, thick eyelashes, eyebrows and hair. Cataract of both eyes were also present (Figure 2A and 2B). There was mild male pattern of hair growth in her arms and legs, mal-formed nails with the missing of nails on both thumbs, first and fifth toes of both feet (Figure 3A, 3B and 3C). The radiographs of hands and feet showed hypoplasia of several terminal phalanges

(Figure 4A and 4B). Hyper-extensibility of the metacarpo-phalangeal joint of the thumb of right hand was also noted (Figure 5).

She had a history of congenital heart disease, Patent ductus arteriosus (PDA) with severe pulmonary hypertension and underwent surgery at 9 months of age. Developmental cataract of both eyes was seen at 2 years of age and she underwent surgery at 2 ½ years, and is still undergoing treatment. The patient was referred for an intelligence quotient (IQ) test, and the patient's IQ score was within the normal range. The diagnosis of this case was based on patient history, clinical finding, systemic evaluation, and consultation with a pediatrician.

The treatment procedures was planned which included plaque removal, plaque control and patient education to treat the marginal gingivitis followed by gingivectomy. Scaling and root planning was done at the first visit followed by internal bevel gingivectomy of upper and lower anterior regions (Figure 6A and 6B). The patient was prescribed antibiotics and analgesics along with 0.2% chlorhexidine mouth rinse twice a day post surgically.

The diagnosis of gingival fibromatosis was given after histopathological examination of the excised gingival mass showed hyperplastic ortho-keratinized stratified squamous epithelium with elongated rete ridges. The underlying connective tissue showed densely packed collagen bundles, few blood vessels and lymphocytes (Figure 7).

The patient was recalled periodically for plaque control and no recurrence of gingival enlargement was observed. The results of treatment was better esthetic appearance and the complete eruption of the anterior teeth.

### III. Discussion

Zimmermann-Laband syndrome is an extremely rare genetic disorder that has equal predilection for males and females. The exact pathogenesis of Zimmermann-Laband syndrome is not very clear; however, Alavandar(9) reported that this syndrome has an autosomal dominant trait. Recently, the genes associated with this syndrome has been located on 2p21-p22 (HGF1), 5q13-q22 (HGF2)(10), and the SOS1 gene(11).

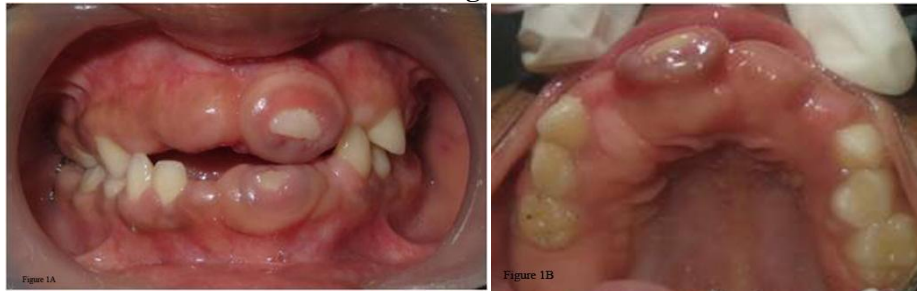Gingival fibromatosis is a typical feature of Zimmermann-Laband syndrome and mostly occurs at birth or within first few months of life and maxilla is more severely affected than mandible(12). The exact pathogenesis for gingival fibromatosis is still not understood; but an increase in proliferation of the gingival fibroblasts as well as increased collagen synthesis can be seen in this disorder. Gingival fibromatosis may be seen as an isolated feature or as part of a genetic syndrome or various systemic conditions. Gingival enlargement can be easily identified, but the associated systemic conditions are not always evident; so dental practitioners should be aware of hidden or invisible and apparently unrelated abnormalities in routine examinations.

A detailed medical history, and systemic evaluation is necessary to differentiate isolated gingival fibromatosis from those associated with various genetic syndromes and other types of acquired generalized gingival enlargement that can occur as a result of inflammation, pregnancy, leukemia, and in response to certain drugs such as phenytoin, diltiazem, cyclosporine, verapamil, and nifedipine. In such cases, the gingiva is usually not as enlarged or as fibrotic as in hereditary gingival fibromatosis(13). The diagnosis of Zimmermann-Laband syndrome may be confirmed based upon a detailed patient history, thorough clinical evaluation, and radiographs. X-ray of hand and foot showing hypoplasia of several terminal phalanges of fingers and toes may also help in identifying this disorder.

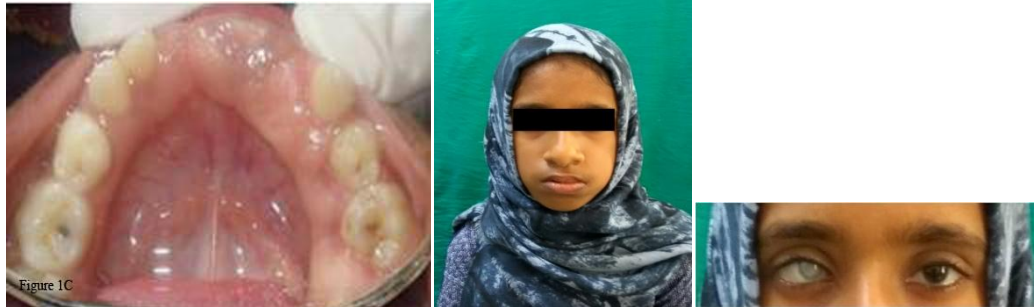The treatment of Zimmermann-Laband syndrome is directed towards the specific symptoms that may appear in each affected individual. Various symptomatic and supportive therapies are available for the treatment of Laband syndrome. Proper oral hygiene measures may decrease the appearance of gum abnormalities and reduce their severity. A surgical treatment is considered when the gingival enlargement results in impairment of esthetics and interferes with normal functioning. A conventional internal bevel gingivectomy is the most appropriate treatment in such cases. The timing of gingivectomy and gingivoplasty for treating gingival fibromatosis is controversial. According to several authors, the ideal time is when all permanent dentition has erupted, because the risk of recurrence is higher before this period. Another school of thought is that gingival growth may worsen during adolescence, due to the influence of sex hormones so surgery should be considered earlier(13). Also delay in surgical treatment may lead to retention of deciduous teeth, alveolar bone resorption, mastication difficulties, impaired esthetics and phonation, and psychological problems(14)(15).

As children with Zimmermann-Laband syndrome may present with abnormal enlargement of the liver or spleen, increased risk for convulsive seizures etc.; a prompt diagnosis is important to ensure appropriate early treatment. Identification of the genetic pathways and mechanisms of Zimmermann-Laband syndrome will be useful in clarifying this disorder and genetic counselling will benefit the affected individuals and their families(16).

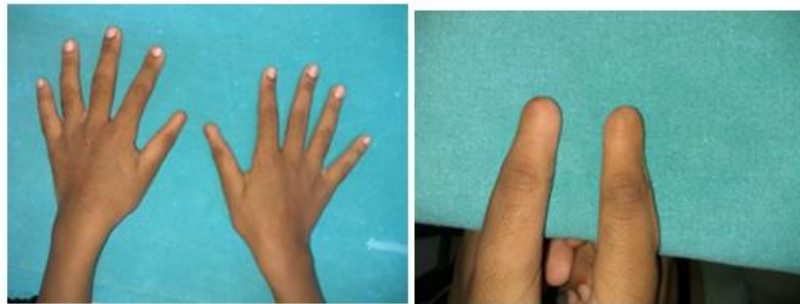**IV. Figures**



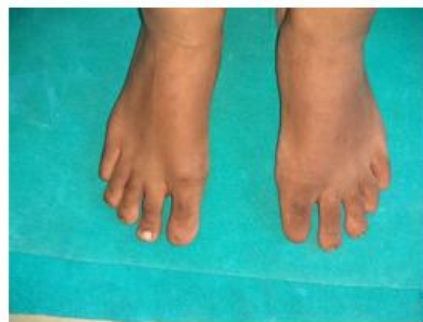**Figure 1A, 1B**



**Figure 1C, 2A, 2B**



**Figure 3A, 3B**



**Figure 3C**

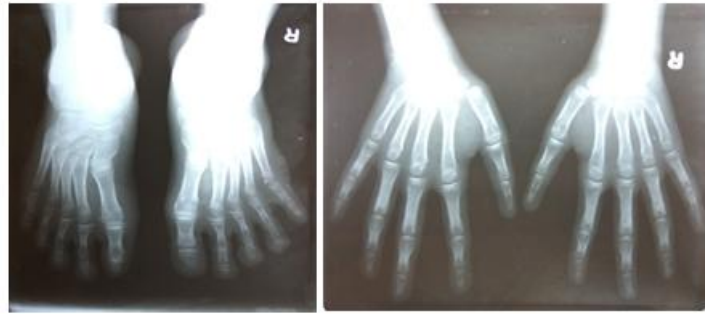

Figure 4A, 4B

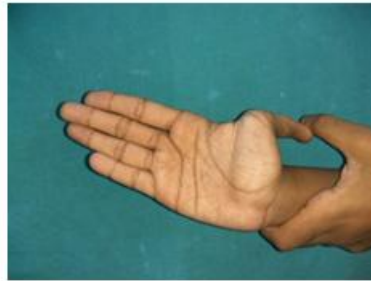

Figure 5

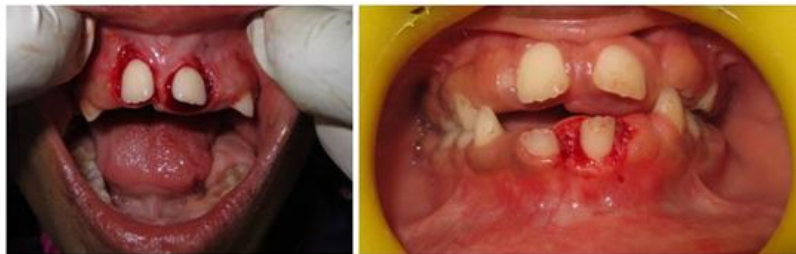


Figure 6A, 6B

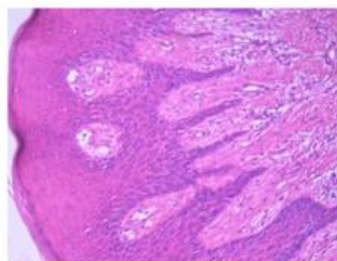


Figure 7

#### **.Figure Legends**

- 1A, 1B, 1C- Intra- oral view showing gingival hyperplasia covering maxillary and mandibular anterior teeth.
- 2A- Extra-oral view showing thick lips and bulbous soft nose.
- 2B- Image showing cataract of eyes.
- 3A, 3B, 3C- Image of fingers and toes showing dysplasia and absence of nails.
- 4A, 4B- Radiographs showing hypoplasia of several terminal phalanges.
- 5- Image showing Hyper-extensibility of the metacarpo-phalangeal joint of the thumb of right hand.
- 6A, 6B- Post-operative view after gingivectomy exposing maxillary and mandibular anterior teeth.
- 7- Histopathological picture of the excised gingival tissue.

#### **V. Conclusion**

Dental practitioners should be aware of the various developmental abnormalities and complications that can occur in patients with gingival fibromatosis as it may indicate the presence of a rare disorder like Zimmermann-Laband syndrome. In summary this syndrome is not a fatal disease; but needs a comprehensive

medical and family history, physical and systemic evaluation that is critical for correct diagnosis, treatment and prevention of complications that can occur in patients.

### References

- [1]. Khoshhal M, Khosropanah H, Vafae F, Moradi Haghgoo J, Torkzaban P, Mahmoodi A. Zimmermann-Laband syndrome in a six-year-old girl: a case report. *Journal of Periodontology & Implant Dentistry*. 2011 Jan 13;2(1):43-6.
- [2]. Doufexi A, Mina M, Ioannidou E. Gingival Overgrowth in Children: Epidemiology, Pathogenesis, and Complications. A Literature Review. *J Periodontol*. 2005 Jan;76(1):3–10.
- [3]. Bakaeen G, Scully C. Hereditary gingival fibromatosis in a family with the Zimmermann Laband syndrome. *J Oral Pathol Med*. 1991 Oct;20(9):457–9.
- [4]. Gorlin R, Cohen m, Hennekam R. *Syndromes of the head and neck*. New York: Oxford University Press; 2001.
- [5]. Witkop JCJ. Heterogeneity in gingival fibromatosis. *Birth Defects Orig Artic Ser*. 1971;7(7):210–21.
- [6]. Zimmermann K. Über anomalien des ektoderms. *Vjschr Zahnheilkd*. 1928;44:419–34.
- [7]. Jacoby NM, Ripman HA, Munden JM. Partial anonychia (recessive) with hypertrophy of the gums and multiple abnormalities of the osseous system: report of a case. *Guys Hosp Rep*. 1940;90:34–40.
- [8]. Laband PF, Habib G, Humphreys GS. Hereditary gingival fibromatosis: Report of an affected family with associated splenomegaly and skeletal and soft-tissue abnormalities. *Oral Surgery, Oral Medicine, Oral Pathology*. 1964 Mar 1;17(3):339-51.
- [9]. Alavandar G. Elephantiasis gingivae. Report of an affected family with associated hepatomegaly, soft tissue & skeletal abnormalities. *J All India Dent Assoc*. 1965 Nov;37(11):349–53.
- [10]. Hart TC, Pallos D, Bozzo L, Almeida OP, Marazita ML, O'Connell JR, et al. Evidence of Genetic Heterogeneity for Hereditary Gingival Fibromatosis. *J Dent Res*. 2000 Oct 8;79(10):1758–64.
- [11]. Hart TC, Zhang Y, Gorry MC, Hart PS, Cooper M, Marazita ML, et al. A mutation in the SOS1 gene causes hereditary gingival fibromatosis type 1. *Am J Hum Genet*. 2002 Apr;70(4):943–54.
- [12]. Il'ina EG, Lur'e I V, Vasiliauskene IP. Analysis of phenotypic variability of Zimmermann-Laband syndrome. *Pediatrics*. 1988;(4):86–8.
- [13]. Coletta RD, Graner E. Hereditary gingival fibromatosis: a systematic review. *J Periodontol*. 2006 May;77(5):753–64.
- [14]. Cuestas-Carnero R, Bornancini CA. Hereditary generalized gingival fibromatosis associated with hypertrichosis: report of five cases in one family. *J Oral Maxillofac Surg*. 1988 May;46(5):415–20.
- [15]. Emerson tg. Hereditary gingival hyperplasia. A family pedigree of four generations. *Oral surg oral med oral pathol*. 1965 Jan;19:1–9.
- [16]. Lin Z, Wang T, Sun G, Huang X. Report of a case of Zimmermann-Laband syndrome with new manifestations. *Int J Oral Maxillofac Surg*. 2010 Sep;39(9):937–41.

Dr. Jeseem M T1. “Zimmermann-Laband syndrome – A rare case report.” *IOSR Journal of Dental and Medical Sciences (IOSR-JDMS)*, vol. 17, no. 10, 2018, pp 04-08.