

An Analysis of destructive surgeries of the eye in a tertiary level teaching hospital

Dr. Dilon Noronha¹, Dr. Sunayana Bhat², Dr. Norman Mendonca,
Dr. Farheen Sana Shakir³

¹(Ophthalmology, Fathermuller Medical college and Hospital, India)

²(Ophthalmology, Fathermuller Medical college and Hospital, India)

³(Ophthalmology, Fathermuller Medical college and Hospital, India)

Corresponding Author: Dr. Dilon Noronha

Abstract:-

Objective: The aim of this study was to determine the frequency and indications for destructive eye surgeries at a Tertiary level teaching Hospital with a view to identifying the preventable indications for which appropriate preventive measures could be recommended.

Patients and Methods: A retrospective, descriptive study of all patients who underwent evisceration, enucleation or exenteration at Fathermuller medical college and hospital, Mangalore from January 2014 to January 2017 was performed. Their outpatient, ward and theatre records were retrieved and reviewed. Information obtained included age, sex, eye affected, duration of symptoms before presentation, visual acuity of affected eye at diagnosis, indication for surgery and type of destructive surgery.

Results: A total of 41 patients had a recommendation for destructive eye surgery, of whom 44% were females and 56% were males. Mean age was 56.48 (SD-20.73; range 4 to 82 years). Children below 16 years accounted for 4.87% of the cases while 58.5% were in their seventh to eighth decade of life. Evisceration was the most performed surgical procedure (87.8%) with the most common indication being Infection (53.5%) followed by trauma (19.5%) and neoplasm (12%).

Conclusion: Ocular trauma, tumour and infection were the most common indications for destructive eye surgery in our centre.

Key Words: Destructive, eye surgeries, indications, tertiary, Enucleation, Evisceration, Exenteration, Neoplasm, trauma

Date of Submission: 04-10-2018

Date of acceptance: 19-10-2018

I. Introduction:

Destructive ocular procedures are usually the ophthalmologist's nightmare, and only recommended as a last resort. This is because of the potential psychological effects of the loss of an eye to the patient and the fact that he as a clinician could not accomplish what he has been trained to do - preservation of vision and improvement of eye health. There are situations however, where such procedures are the only solution to a rather intractable problem. Current evidence shows that destructive ocular procedures are on the decline due to improved diagnosis and treatment with resultant increased globe preservation.^[1,2]

Destructive eye surgeries include Evisceration, Enucleation and Exenteration.

Evisceration involves the removal of the contents of the eyeball, leaving the sclera and the optic nerve intact.

Enucleation is the removal of the whole eyeball and part of the optic nerve.^[3]

In Exenteration, all the contents of the orbit, with or without the eyelids and part of the bony wall, are removed.^[3]

The Indications for destructive eye surgeries are similar globally, but the prevalence of the ocular morbidities necessitating these procedures differs from place to place.^[4] This variation could be a reflection of the pattern of severe ophthalmic diseases in a particular community as well as the level of sophistication in the management of these diseases.^[5]

Several reports from developing countries^[6-11] implicated ocular infections as the most common indication for destructive eye surgeries whereas malignant tumours accounted for most of the indications in developed countries.^[12-15] However, trauma seems to be common to both developing and developed countries.^[5, 16-22] Evisceration and Enucleation could both be performed in relieving pain in painful blind eye, severe ocular infections or in improving cosmetic appearance.^[25,23] However, evisceration should never be performed if a tumour is suspected.^[3] Although inadvertent evisceration of eyes containing uveal melanoma was reported by

Eagle *et al.*^[24] Enucleation is usually the procedure of choice in primary intraocular malignancies with failed conservative treatment as well as ocular conditions in which the nature of intraocular pathology is unknown.^[3] Exenteration is reserved for orbital tumours and intraocular tumours that have spread to the orbit.^[3]

The purpose of the study was to determine the frequency & indications for destructive eye surgeries and to identify the preventable indications for which appropriate preventive measures could be recommended.

II. Materials And Methods:

This was a retrospective, descriptive study of all patients who underwent evisceration, enucleation or exenteration at Father Muller Medical college and Hospital, Kankanady, Mangalore from January 2014 to January 2017. Their outpatient, ward and theatre records were retrieved and reviewed. Relevant information was obtained which included age, sex, eye affected, duration of symptoms before presentation, visual acuity of affected eye at presentation, indication for surgery and type of destructive surgery. Frequency tables of variables were done. Ethical approval was sought and obtained from the Health Research and Ethics Committee of the institute. Data obtained were analysed using the Statistical Package for Social Sciences (SPSS) version 17 (SPSS Inc., Chicago, IL).

III. Results:

Forty one eyes of 41 patients were surgically removed during the period under review. Twenty four (59%) patients had their right eye removed while 17 (41.46%) patients had their left eye removed.

No adult had both eyes removed.

Table 1 shows the age distribution of the 41 patients. There were 23 (56%) males and 18 (44%) females with a male: female ratio of 1.3:1. The mean age was 56.48 (SD-20.73) years with 2 participants being children below age of 15yrs. Children below the age of 16 years accounted for 4.87% of the cases while 48.7% were in their seventh to ninth decade of life being the most commonly affected age group. All the eyes that underwent destructive eye surgeries were blind with 36(87.8%) eyes having a visual acuity of NPL while perception of light and hand movement were recorded in 4 (9.75%) eyes and 1 (2.43%) eye respectively.

Evisceration was the most commonly performed destructive eye surgery done in 36 (87.7%) patients. This was followed by enucleation performed in 5 (12%) patients while exenteration was not performed in any patient.

The various indications for destructive eye surgeries are shown in Table 2. The most common indication was Infection documented in 22 (53.5%) patients. This was followed by trauma seen in 8 (19.5%) and 5 (12%) patients, respectively

Sl no	Age category	Number of patients	%
1	0-15 yrs	2	4.8%
2	15-60 yrs	19	46.5%
3.	>60 yrs	20	48.7%
	Total	41	100

Table 1: Age Distribution of study population

Sl no	Indication	Number	%
1	Infection	22	53.5
2	Trauma	8	19.5
3.	Neoplasms	5	12
4.	Painful blind eye	5	12
5.	Phthisis bulbi	1	3
	Total	41	100

Table 2: Indications for destructive eye surgeries

FIG 1:

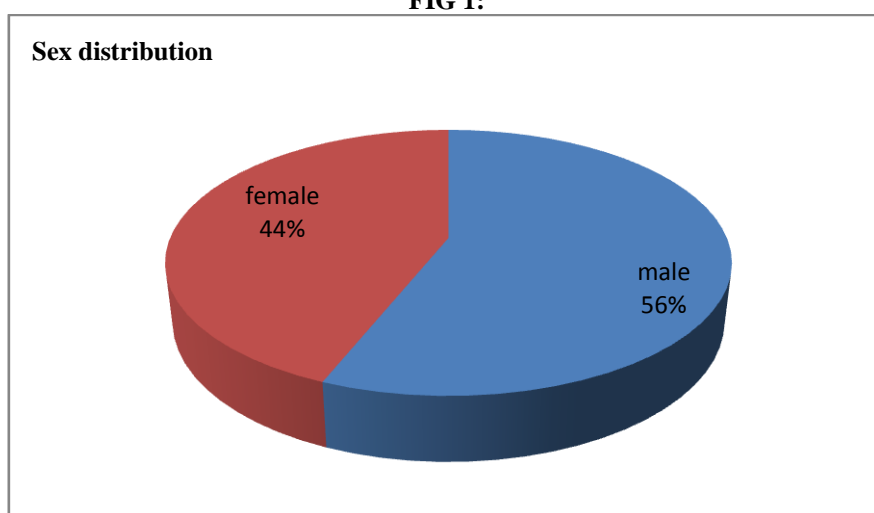
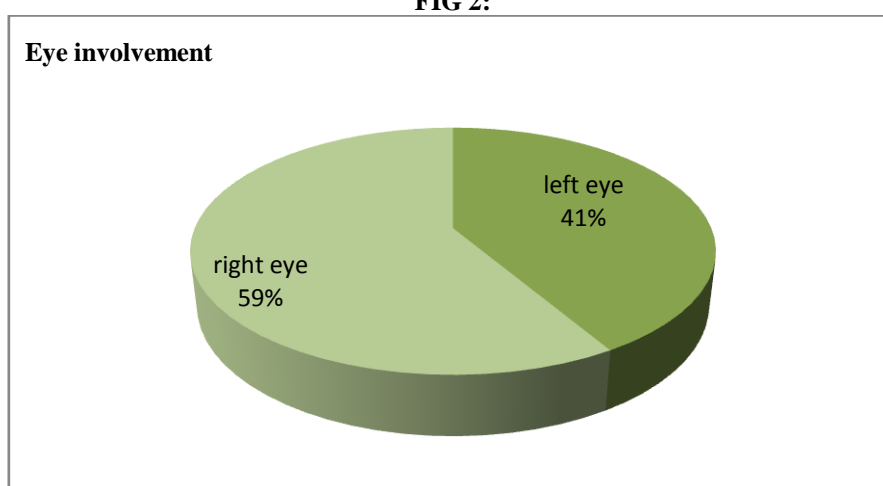


FIG 2:



Demographics of study population:-

IV. Discussion:

The mean age of patients who underwent destructive eye surgeries in this study was 56.48 years. This finding is comparable to the 45.6 years recorded by Otulana and Majekodunmi [26] but higher than the 40.8 years, 43.78 years and 29.69 years documented by Nwosu, [6] Eballé *et al.* [7] and Bodunde *et al.* [16] respectively.

The overall frequency of destructive eye surgeries was 0.18% . This was much lower than the 10.6% and 12.1% reported by Bodunde *et al.* [16] and Otulana and Majekodunmi, [26] respectively and 3.4%, 2.7% and 1.4% documented by Nwosu, [6] Gyasi *et al.* [8] and Pandey, [11] respectively.

The most common indication for destructive eye surgeries was infection. This is consistent with the findings in previous studies from some parts of Nigeria, [6,9] Africa [7,8] and Asia [11] but contrasts with observations from Southwest Nigeria [16,17] and Ethiopia [18] where ocular trauma was documented to be the most common indication. In this study, infection was the leading cause of destructive eye surgery among both males and females and was predominant after the age of 60 years. A majority of the infections were either due to endophthalmitis or panophthalmitis, which is in accord with findings in previous studies. [6- 9,11,26] This may be because individuals in this age group are less economically productive coupled with the non- availability of free health care delivery, probably leading to late presentation more so that close to 60% of these patients presented between 1 week and a month of the onset of symptoms. Therefore, it is imperative for the government to make available free health care services for all and sundry. Alternatively, universal health coverage with equitable, sustainable, compulsory national health insurance should be promoted thereby eradicating out- of- pocket payment for services that encourage catastrophic health expenditure and its attendant health system failure.

Trauma was the second most common indication for destructive eye surgeries and it was predominant among males and peaked between the ages of 20 and 50years. This calls for concern because of the

socioeconomic implication of the affectation of individuals in this age group who are meant to be economically active and productive. In addition, a majority of the circumstances of the trauma sustained were related to road traffic crashes, home, work and assault, which are largely avoidable.

Tumour was the third most common indication for destructive eye surgeries. Choroidal melanoma was the most common indication for Enucleation in our study predominantly seen in the seventh decade of life. This compares favourably with previous reports in the literature. Other common indication for enucleation in the first decade of life was Retinoblastoma. The preponderance of tumour-related eye removal in this age group may not be unconnected with the fact that retinoblastoma is the most common childhood intraocular malignancy typically presenting in the first decade of life coupled with late presentation of the patients, leaving destructive eye surgeries as the only therapeutic option. This calls for concern because retinoblastoma is a treatable malignancy if patients present early with a good prospect of saving the life, the eyeball and even the vision. To this end, awareness campaign on symptoms and signs of retinoblastoma needs to be intensified to ensure early detection and presentation. This can be done through print and mass media, handbills and poster display in public places. Also, incorporation of red reflex assessment especially Bruckner's test into examination routine during immunisation visits of babies is advocated to facilitate early detection of retinoblastoma and other causes of leucocoria. Furthermore, genetic testing of parents and siblings of retinoblastoma patient is advocated to engender early detection and prompt treatment Painful blind eye & phthisis bulbi accounted for 12% and 3% of the cases respectively.

Evisceration was the most commonly performed destructive eye surgery in this study. This is in agreement with previous documentations in the literature.^[5- 11,16,26] The ease with which evisceration is performed compared to enucleation could be a contributory factor. Also, badly damaged eyes, either due to trauma or infection, being the most common indication for evisceration, were responsible for more than half of the eyes removed. Furthermore, the notion that evisceration has the advantages of relative tissue preservation, better mobility of prosthesis, less operation time, lower risk of orbital implant extrusion or transmission of infective materials into cavernous sinus causing intracranial infection in endophthalmitis/panophthalmitis, relative to enucleation could make it a natural preference.^[27]

Enucleation was the second most commonly performed destructive eye surgery. Tumour was found to be the most common reason for the procedure, which is in agreement with the findings of Majekodunmi^[31] in this centre over two decades ago. This is also consistent with observations in previous studies from other developing countries.^[28- 30]

The choice of the procedure seems to be the surgeon's preference. This same view was shared by Zheng and Wu^[21] in a retrospective review of eyes that underwent enucleation or evisceration as a result of trauma.

Finally, orbital implants and good fitting prosthesis is advocated for good cosmetic appearance especially in children who are prone to facial asymmetry as well as reduction of the psychological trauma of losing an eye.

V. Conclusion:

The most common indication for destructive eye surgery in our setting was endophthalmitis/panophthalmitis. Most patients refuse surgery probably due to its likely psychological impact. Educating the population on the dangers of late presentation and the need to avoid self-medication can help reduce the need for destructive eye surgeries. Screening programs should also be created and implemented to detect retinoblastoma early in order to avoid the need for enucleation. Finally, there is need to provide a good fitting prosthesis for patients who underwent destructive eye surgeries to reduce the social outcast effect as well as a careful follow-up of the only eye.

References:

- [1]. Saeed MU, Chang BY, Khandwala M, Shivane AG, Chakrabarty A. Twenty year review of histopathological findings in enucleated/eviscerated eyes *J Clin Pathol* 2006;59(2):153-5.
- [2]. Tahri H, Benatya AD, Chefchaouani CM, El Bakkali M, Berraho A. Enucleations: epidemiologic investigation in Morocco. presentation of 183 cases *Bull Soc Belge Ophtalmol* 2004;(292):31-4.
- [3]. Holdy JB, Chang WJ, Dailey RA, Foster JA. Orbit, eyelids and lacrimal system. In: Basic and Clinical Science Course. San Francisco: American Academy of Ophthalmology; 2010. p. 123-32.
- [4]. Obuchowska I, Mariak Z, Sherkawey N. Clinical indications for enucleation – A review of the literature. *Klin Oczna* 2005;107:159-62.
- [5]. Olatunji FO, Ibrahim FU, Ayanniyi AA, Azonobi R, Tukur RB, Maji DA. Indications for surgical removal of the eyes in a tertiary institution in North Eastern Nigeria. *Ann Afr Surg* 2011;7:20-4.
- [6]. Nwosu SN. Destructive ophthalmic surgical procedures in Onitsha, Nigeria. *Niger Postgrad Med J* 2005;12:53-6.
- [7]. Eballé AO, Dohvoma VA, Koki G, Oumarou A, Bella AL, Mvogo CE. Indications for destructive eye surgeries at the yaounde gynaeco-obstetric and paediatric hospital. *Clin Ophthalmol* 2011;5:561-5.
- [8].

- [9]. Gyasi ME, Amoaku WM, Adjuik M. Causes and incidence of destructive eye procedures in North-eastern Ghana. *Ghana Med J* 2009;43:122-6.
- [10]. Ibang A, Asana U, Nkanga D, Duke R, Etim B, Oworo O. Indications for eye removal in Southern Nigeria. *Int Ophthalmol* 2013;33:355-60.
- [11]. Monsudi KF, Ayanniyi AA, Balarabe AH. Indications for destructive ocular surgeries in Nigeria. *Nepal J Ophthalmol* 2013;5:24-7.
- [12]. Pandey PR. A profile of destructive surgery in Nepal Eye Hospital. *Kathmandu Univ Med J (KUMJ)* 2006;4:65-9.
- [13]. Günalp I, Gündüz K, Ozkan M. Causes of enucleation: A clinicopathological study. *Eur J Ophthalmol* 1997;7:223-8.
- [14]. Scat Y, Liotet S, Bellefqih S. Etiology of enucleations. Apropos of 3,246 cases. *J Fr Ophtalmol* 1996;19:242-7.
- [15]. Setlur VJ, Parikh JG, Rao NA. Changing causes of enucleation over the past 60 years. *Graefes Arch Clin Exp Ophthalmol* 2010;248:593-7.
- [16]. Stiebel H, Sela M, Pe'er J. Changing indications for enucleations in Hadassah University Hospital, 1960-1989. *Ophthalmic Epidemiol* 1995;2:123-7.
- [17]. Bodunde OT, Ajibode HA, Awodein OG. Destructive eye surgeries in Sagamu. *Niger Med Pract* 2005;48:47-9.
- [18]. Adeoye AO, Onakpoya OH. Indication for eye removal in Ile-Ife, Nigeria. *Afr J Med Med Sci* 2007;36:371-5.
- [19]. Haile M, Alemayehu W. Causes of removal of the eye in Ethiopia. *East Afr Med J* 1995;72:735-8.
- [20]. Etebu E, Adio A. Indications for removal of the eye at a tertiary hospital in South-Southern Nigeria. *J Ophthalmol East Cent S Afr* 2013;14:19-22.
- [21]. Cheng GY, Li B, Li LQ, Gao F, Ren RJ, Xu XL, *et al.* Review of 1375 enucleations in the Tongren Eye Centre, Beijing. *Eye (Lond)* 2008;22:1404-9.
- [22]. Zheng C, Wu AY. Enucleation versus evisceration in ocular trauma: A retrospective review and study of current literature. *Orbit* 2013;32:356-61.
- [23]. Obuchowska I, SHERKAWAY N, Elmdhm S, Mariak Z, Stankiewicz A. Clinical indications for enucleation in the material of department of ophthalmology, medical academy in Bialystok in the years 1982-2002. *Klin Oczna* 2005;107:75-9.
- [24]. Shah-Desai SD, Tyers AG, Manners RM. Painful blind eye: Efficacy of enucleation and evisceration in resolving ocular pain. *Br J Ophthalmol* 2000;84:437-8.
- [25]. Eagle RC Jr., Grossniklaus HE, Syed N, Hogan RN, Lloyd WC 3rd, Folberg R. Inadvertent evisceration of eyes containing uveal melanoma. *Arch Ophthalmol* 2009;127:141-5.
- [26]. Migliori ME. Enucleation versus evisceration. *Curr Opin Ophthalmol* 2002;13:298-302.
- [27]. Otulana TO, Majekodunmi O. Indications for destructive ocular surgery at the Olabisi Onabanjo University Teaching Hospital, Sagamu (OOUTH). *Niger J Ophthalmol* 2013;21:22-6.
- [28]. Hansen AB, Petersen C, Heegaard S, Prause JU. Review of 1028 bulbar eviscerations and enucleations. Changes in aetiology and frequency over a 20-year period. *Acta Ophthalmol Scand* 1999;77:331-5.
- [29]. Epee E, Masanganise R. The rate of and indications for enucleations at Sekuru Kaguvi Eye Unit in Harare: A comparative analysis. *Cent Afr J Med* 2003;49:13-5.
- [30]. Vemuganti GK, Jalali S, Honavar SG, Shekar GC. Enucleation in a tertiary eye care centre in India: Prevalence, current indications and clinicopathological correlation. *Eye (Lond)* 2001;15(Pt 6):760-5.
- [31]. Sengupta S, Krishnakumar S, Biswas J, Gopal L, Khetan V. Fifteen-year trends in indications for enucleation from a tertiary care center in South India. *Indian J Ophthalmol* 2012;60:179-82.
- [32]. Majekodunmi S. Causes of enucleation of the eye at Lagos University Teaching Hospital. A study of 101 eyes. *West Afr J Med* 1989;8:288-91.

Dr. Dillon Noronha, "An Analysis of destructive surgeries of the eye in a tertiary level teaching hospital." *IOSR Journal of Dental and Medical Sciences (IOSR-JDMS)*, vol. 17, no. 10, 2018, pp 48-52