

Pheochromocytoma in a child- A case report with review on literature

Shefali Goyal¹, Maulik Sharma², Brijesh Sharma³

Pg Resident^{1,2}, Professor & Head of Department²

Mahatma Gandhi Medical College, Riico, Sitapura, Jaipur, India

Corresponding Author:- Shefali Goyal

Abstract: Pheochromocytoma is a neuroendocrine tumour arising from adrenal glands. It is a catecholamine-secreting tumor of chromaffin cells which is located in the adrenals causing episodic/paroxysmal hypertension. 10 percent of all pheochromocytomas occur in children. **The incidence of pheochromocytoma is 2 to 8 per million people per year.** Hereby presenting a case report on pheochromocytoma in a 11 year old child with review on its literature.

Keywords: Pheochromocytoma, catecholamine, chromaffin cells, adrenals

Date of Submission: 01-10-2018

Date of acceptance: 15-10-2018

I. Introduction

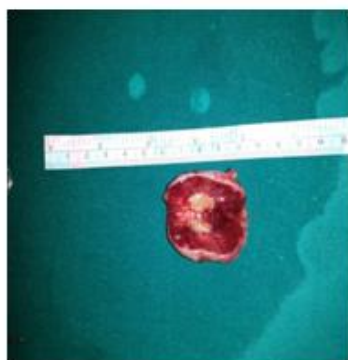
Pheochromocytoma occurs in less than 0.2 percent of patients with hypertension.^{1,2} It is estimated that the annual incidence of pheochromocytoma is approximately 0.8 per 100,000 person-years³. Although pheochromocytomas may occur at any age, they are most common in the fourth to fifth decade and are equally common in men and women⁵. Less than 10% pheochromocytomas occur in children. The term pheochromocytoma was proposed by Pick in 1912⁶ and refers to the Greek words *phaios*, meaning dusky (brown), and *chroma*, which means color, that is colour of the stain that occurs when the tumors are treated with chromium salts.

II. Case report

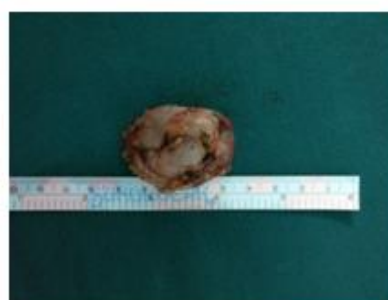
An 11 year old male presented in emergency department with loss of consciousness since three days. His pulse rate was 110/min and blood pressure 220/160 millimeter mercury. Patient was treated in a hospital for same. Afterwards, the patient was referred to us. Patient was hypertensive since 2 years but without any treatment.

Patient underwent endoscopic assisted removal of ICH and septum pellidectomy. Patient's BP was still uncontrolled. CT abdomen was done which revealed Left side Pheochromocytoma for which Laparoscopic Adrenalectomy was done eventually. Even after surgery, blood pressure still fluctuated and the patient was given antihypertensive drugs. Plasma free normetanephrine was 2952 and metanephrine was 110. To rule out multifocal lesion plan for nuclear imaging was taken and patient was referred to AIIMS Delhi for GA68 DOTANOC PET CT and MIBG SPECT CT SCAN.

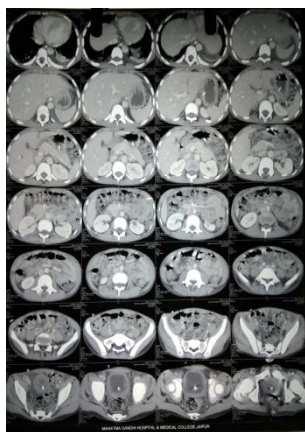
Biopsy suggestive of Pheochromocytoma with PASS score 0.



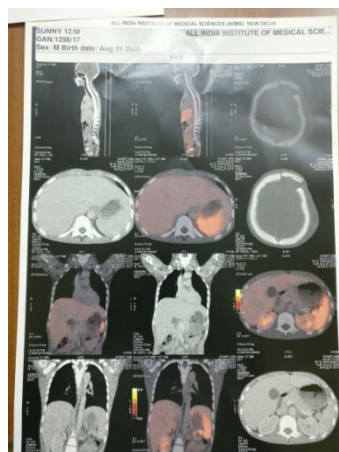
1) Specimen of Adrenal tumor (Cut section)



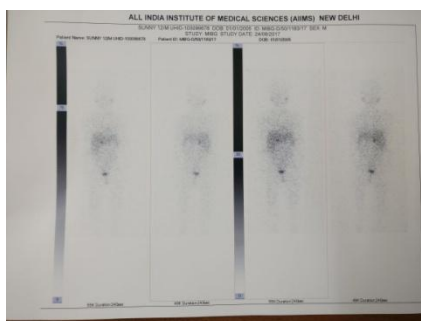
2) Gross specimen of Adrenal tumour



CT image showing left adrenal mass
(isodense round to oval of approx 2x3 cm)

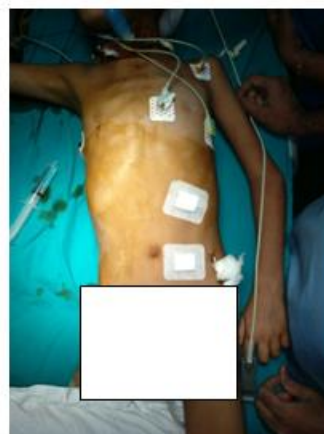
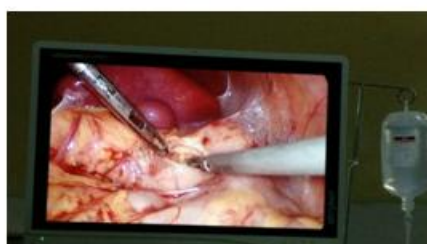
DOTANOC Scan
suggestive of no evidence of SSTR
expressing disease in body



MIBG Scan MIBG scan suggestive of no evidence of MIBG concentrating lesion in body.

Intra op images



III. Result

The post operative recovery was uneventful and patient was discharged on 8th post operative day and resumed his routine activities within 2 weeks.

IV. Discussion

Pheochromocytoma is a rare adrenal gland tumour .It releases catecholamines into circulation producing symptoms such as sustained/labile hypertension.,sweating, palpitation. About 85% of pheochromocytomas arise in chromaffin cells of the adrenal medulla, whereas 18% may be extra-adrenal⁶, arising from paraganglionic chromaffin cells (in association with sympathetic nerves) in the organ of Zuckerkandl, urinary bladder (<1%), chest (<2%), neck (<0.1%), and at the base of the skull; tumors also have occurred in the middle ear and spermatic cord. Extra-adrenal pheochromocytomas are more common in children

(30%) than adults (15%). Why extra-adrenal tumors are more frequently malignant (30–40%) than adrenal pheochromocytomas (10%) is unknown⁷. Pheochromocytoma secrete norepinephrine and epinephrine, dopamine, calcitonin, serotonin, vasoactive intestinal peptide, adrenocorticotropic hormone, neuropeptide Y, atrial natriuretic factor, growth hormone-releasing factor, somatostatin, parathyroid hormone-related peptide. 25-30% Of pheochromocytoma are familial. Presence of pheochromocytoma with medullary thyroid carcinoma and c-cell hyperplasia or neoplasia constitutes multiple endocrine neoplasia type 2a. Pheochromocytoma along with MTC, mucosal neuromas, thickened corneal nerves, alimentary-tract ganglioneuromatosis, and often a marfanoid habitus, but rarely parathyroid disease, constitutes multiple endocrine neoplasia type 2b. Pheochromocytoma can also occur with von Hippel–Lindau (VHL) disease (hemangioblastoma of the central nervous system and retinal angioma), neurofibromatosis type 1, and carotid body tumors. Patient presents with Sustained, labile, or paroxysmal hypertension. Symptoms due to release of excess catecholamines include hypertension, frequently severe hypertensive headaches, generalized sweating, and palpitations. Patients experience severe anxiety and fear of death, tremulousness, chest pain, nausea, vomiting, weakness, fatigue, weight loss, warmth or heat intolerance, dyspnea, hypertension alternating with hypotension, orthostatic hypotension, paresthesias, pallor of the face and upper body

Plasma and 24-h urine metanephrine and normetanephrine are more sensitive than other biochemical tests for making the diagnosis of sporadic and familial pheochromocytoma^{8,9}. Computed tomography (CT) can identify 95% of adrenal pheochromocytomas 1 cm or larger, and it can localize 90% of extra-adrenal abdominal and pelvic tumors larger than 2 cm. Magnetic resonance imaging (MRI) is more reliable and more specific than CT in detecting pheochromocytomas, and signal intensity on T₂-weighted images can be fairly characteristic for pheochromocytomas; only rarely will other benign or malignant tumors resemble pheochromocytomas.^{6,10,11} Uptake of ¹³¹I-metaiodobenzylguanidine (MIBG) occurs in up to 85% of pheochromocytomas, and is highly specific (95–100%)^{24,25}. Recently 6-[¹⁸F]-fluorodopamine ([¹⁸F]DA) positron emission tomography scan was reported superior to ¹³¹I-MIBG scintigraphy in locating metastatic pheochromocytomas.¹⁴ Treatment consists of laparoscopic removal of adrenal and extra-adrenal pheochromocytoma as was our case. If tumour is large, multiple and difficult to remove open transperitoneal surgical exploration of the abdomen is done. Familial pheochromocytoma always must be considered, and following should be ruled out MTC, c-cell hyperplasia, hyperparathyroidism, VHL. If familial disease found then first-degree relatives should be evaluated genetically for pheochromocytoma and coexisting disease. If pheochromocytoma presents with metastasis, it should be resected as much tumor tissue as possible to reduce the amount of catecholamines entering the circulation. Radiotherapy with ¹³¹I-MIBG reduces tumor size and catecholamine secretion. Chemotherapy with cyclophosphamide, vincristine, and dacarbazine is used for aggressive metastatic tumors, Treatment with a combination of ¹³¹I-MIBG and chemotherapy may provide greater therapeutic benefit than either alone.¹⁵ X-ray radiation is employed in bony metastases. Drugs such as α and β -Blockers control hypertension and metyrosine inhibits catecholamine synthesis and reduce symptoms. Occasionally, patients with metastatic pheochromocytoma develop a hypersecretory disorder (due to vasoactive intestinal peptide secretion), with severe diarrhea that may be benefited by somatostatin (given i.v.). Alternatives to surgical resection, chemoradiotherapy include external beam radiation, cryoablation, radiofrequency ablation, and transcatheter embolization of hepatic metastases.^{16,17}

References

- [1]. Stein PP, Black HR. A simplified diagnostic approach to pheochromocytoma. A review of the literature and report of one institution's experience. *Medicine (Baltimore)* 1991; 70:46
- [2]. Pacak K, Linehan WM, Eisenhofer G, et al. Recent advances in genetics, diagnosis, localization, and treatment of pheochromocytoma. *Ann Intern Med* 2001;134:135
- [3]. Beard CM, Sheps SG, Kurland LT, et al. Occurrence of pheochromocytoma in Rochester, Minnesota, 1950 through 1979. *Mayo Clin Proc* 1983;58:802
- [4]. Guerrero MA, Schreinemakers JM, Vriens MR, et al. Clinical spectrum of pheochromocytoma. *J Am Coll Surg* 2009;209:707.
- [5]. Pick L. Das Ganglioma embryonale sympathicum (Sympathoma embryonale), eine typisch bosartige Geschwulstform des sympathischen Nervensystems. *Klin Wochenschr.* 1912;49:16–22
- [6]. Whalen, R.K., Althausen, A.F., and Daniels, G.H. **Extra-adrenal pheochromocytoma.** *J Urol.* 1992; 147: 1–10
- [7]. Manger, W.M. and Gifford, R.W. Jr. **Clinical and Experimental Pheochromocytoma.** Blackwell Science, Cambridge MA; 1996.
- [8]. Manger, W.M. and Eisenhofer, G. **Pheochromocytoma: diagnosis and management update.** *Curr Hypert Rep.* 2004; 6: 477–484
- [9]. Lenders, J.W.M., Pacak, K., Walther, M.M. et al. **Biochemical diagnosis of pheochromocytoma: which test is best?.** *JAMA.* 2002; 287: 1427–1434
- [10]. Fink, I.J., Reinig, J.W., Dwyer, A.J. et al. **MR imaging of pheochromocytomas.** *J Comput Assist Tomogr.* 1985; 9: 454–458
- [11]. Baker, E.M., Spritzer, C., Blinder, R. et al. **Benign adrenal lesions mimicking malignancy on MR imaging: report of two cases.** *Radiology.* 1987; 163: 669–671
- [12]. Sisson, J.C., Frager, M.S., Valk, T.W. et al. **Scintigraphic localization of pheochromocytoma.** *N Engl J Med.* 1981; 305: 12–17
- [13]. Jalil, N.D., Pattou, F.N., Combemale, F. et al. **Effectiveness and limits of preoperative imaging studies for the localizations of pheochromocytomas and paragangliomas: a review of 282 cases.** *Eur J Surg.* 1998; 164: 23–28

- [14]. Illias, I., Yu, J., Carrasquillo, J.A. et al. **Superiority of 6-[¹⁸F]-fluorodopamine positron emission tomography versus [¹³¹I]-metaiodobenzylguanidine scintigraphy in the localization of metastatic pheochromocytoma.** *J Clin Endocrinol Metab.* 2003; 88: 4083–4087
- [15]. Sisson, J.C., Shapiro, B., Shulkin, B.L. et al. **Treatment of malignant pheochromocytomas with ¹³¹I-metaiodobenzylguanidine and chemotherapy.** *Am J Clin Oncol.* 1999; 22: 364–370
- [16]. Takahashi, K., Ashizawa, N., Minami, T. et al. **Malignant pheochromocytoma with multiple hepatic metastases treated by chemotherapy and transcatheter arterial embolization.** *Intern Med.* 1999; 38: 349–354
- [17]. Pacak, K., Fojo, T., Golstein, D.S. et al. **Radiofrequency ablation: a novel approach for treatment of metastatic pheochromocytoma.** *J Natl Cancer Inst.* 2001; 93: 648–649

Shefali Goyal,” “Pheochromocytoma in a child- A case report with review on literature”.” IOSR Journal of Dental and Medical Sciences (IOSR-JDMS), vol. 17, no. 10, 2018, pp 74-77.