

‘ ‘ Effectiveness and Safety of Percutaneous Ethanol Ablation In Thyroid Colloid Cysts’ ’

Dr Rajesh Baghel¹ Dr Ruchi Vaish² Dr Akshara Gupta³

Corresponding Author:- Dr Dinesh Sahu

Abstract

OBJECTIVE –

To evaluate the efficacy, safety & associated complications of percutaneous ethanol ablation (PEA) in the treatment of thyroid colloid cyst.

MATERIAL & METHODS –

USG of the thyroid gland was performed in 30 patients with complaints of thyroid swelling (22 females and 8 males) with 20 complex cysts and 10 pure cysts which underwent USG-guided fine needle aspiration (FNA) and cytology to rule out any malignant etiology .

Sterile Ethanol was injected into the cyst under USG guidance. The amount of ethanol injected was about 50% of the amount of aspirated fluid. The alcohol mixed colloid fluid was aspirated , fresh 100% ethanol was injected , left for 2-3 minutes and again re- aspirated as much as possible . Follow-up USG was done every month for 3 months; ethanol was re-injected when there was no significant reduction in the cyst volume.

RESULT-

Out of 30 patients 25 patients showed significant (>50 %) reduction in cyst volume. 8 (26.6%) patients showed complete resolution of cyst volume (complete responders) . Repeat aspiration done in 7(23.3%) patients who showed less than 20% reduction in cyst volume after 1st follow up. 3 (10%) patients showed failure after repeat ethanol injection. 5 (16.6%) patients showed failure with less than 50 % reduction in cyst volume. No significant adverse effect was noted during the procedure and follow up except for the local pain at the injection site .

CONCLUSSION-

Percutaneous ethanol ablation was found to be safe ,effective and less time consuming OPD based treatment option for thyroid colloid cyst without any significant side effect .

Date of Submission: 01-10-2018

Date of acceptance: 15-10-2018

I. Background

In the evaluation of thyroid nodules, in addition to the clinical and ultrasound findings, fine-needle aspiration (FNA) cytology is important for characterizing and defining treatment. In nodules with cytology suspicious or positive for malignancy, surgical resection is the appropriate treatment. Patients with thyroid colloid cysts usually seek treatment for cosmetic reasons or because of local compressive manifestations, such as dysphagia.[1] .Most cystic lesions of the thyroid are considered to be caused by hemorrhage and subsequent degeneration of preexisting nodules [2]. Pure cysts are associated with a lower probability of malignancy than mixed cysts [3]. Sonographically guided percutaneous ethanol injection, which is an alternative to surgery for the treatment of several benign conditions, is a safe and effective therapeutic tool for the treatment of thyroid colloid cyst . Several authors have reported the efficacy of percutaneous ethanol injection for treating benign thyroid nodules . Treatment of thyroid cysts with PEI was first proposed in 1987 by Edmonds et al[4] and later in 1989 by Rozman et al.[5] . The proposed mechanism of action is as follows: after injection of ethanol into the nodule, which is distributed in tissue by a diffusion mechanism, induces cellular dehydration and protein denaturation, which is followed by coagulation necrosis and reactive fibrosis which result in the obliteration of the cyst [6].

AIMS & OBJECTIVE

To evaluate the efficacy, safety & associated complications of percutaneous ethanol ablation in the treatment of thyroid colloid cysts.

II. Material And Methods

• This prospective study was conducted as collaboration between the department of Radiodiagnosis and department of Surgery . The study period was from July 2016 till Dec 2017. Consecutive patients who had presented to the Surgery department with complaints of goiter were considered.

INCLUSION CRITERIA-

1. Patients would be included of both sex & age groups between 15-65 years, with confirmed case of benign cystic nodules by FNAC.
2. Patient with normal thyroid profile (euthyroid).

• **EXCLUSION CRITERIA-**

1. Malignant thyroid nodules.
2. Pregnant females.
3. Patients not giving consent for participation in the study.

Our study group consisted of total 30 patients out of which 22 women and 8 men (age range, 20– 65 years; mean age, 42.46 years) with 20 complex cysts and 10 pure cysts. A thyroid cyst was defined as a nodule with a cystic component of more than 60%. Most patients ($n = 26$) were concerned about the cosmetic implication of the nodules, and a few patients complained of local discomfort ($n = 3$) and dysphagia ($n = 1$) and expressed fear about malignancy. Thyroid function was evaluated, and assessment of goiter for thyroid nodules was done using USG .

Nodules having two or more high risk features of malignancy on USG (irregular margins, hypoechoic nodules, nodules taller than broader, loss of peripheral halo, microcalcifications, increased central vascularity)^[7] underwent USG-guided fine needle aspiration (FNA) and cytology evaluation. Clinically and biochemically euthyroid patients who on clinical examination and neck USG had thyroid nodules, which were predominantly cystic ($\geq 60\%$ cystic) with at least 2 ml cystic component on USG were included in the study. Patients were excluded if they had 2 or more high risk feature of malignancy on thyroid USG ^[7] or FNA suggestive of malignancy, suspicious, or indeterminate cytology. The study was approved by the institutional ethics committee. The study protocol was explained to all the patients and only those who gave informed written consent were included. The study protocol has been elaborated in [Figure 04].

For sonography, SONOSCAPE MODEL A8 USG machine was used with a 5– 11 MHz linear probe. The volume of a cyst, except a complex cyst, was determined using the following formula: length \times width \times height $\times \pi / 6$. For a complex cyst, volume was calculated as the volume of the cystic component other than solid areas.

Using sonographic guidance, we inserted a 20- to 22-gauge needle into the cystic nodule without placing the patient under local anesthesia . The cysts were aspirated under aseptic conditions using a 22 G (25 mm) needle with a 20 ml syringe in supine position with neck extended. Aspiration of maximal amount of fluid possible was attempted in each patient. In patients with thick fluid not draining with the 22 G needle, a second re-aspiration was attempted using a 20 G or 18 G needle. Sterile 100% ethanol specially manufactured & supplied by Changshu Hongsheng Fine Chemical Co. Ltd. of around 50-100% volume of fluid aspirated was injected into the cyst by changing the syringe with the needle *in situ*. The alcohol mixed colloid fluid was aspiration and fresh 100% ethanol was injected and left for 2-3 minutes and again re- aspirated as much as possible . The patients were reviewed clinically and ultrasonographically followed every month for consecutive 3 months and the side effects of ethanol ablation were evaluated by recording the symptoms of patients.

The effect of the therapy was presented as the volume reduction rate (volume reduction rate [%] = volume decrease [initial volume – final volume after treatment] / initial volume \times 100%), and each case was classified into one of the following four groups: completely ablated cysts (complete responder) , cysts with a 50– 99% reduction in volume (responders), cysts with a 0– 49% reduction in volume (non-responders)., and cysts with an increase in volume (non-responders).

Among non-responders at 1 month, those with $< 20\%$ reduction in cyst volume underwent a second aspiration followed by ethanol injection using the same procedure as mentioned above. Seven patients underwent ethanol ablation twice and the remaining 23 patients underwent the procedure once.

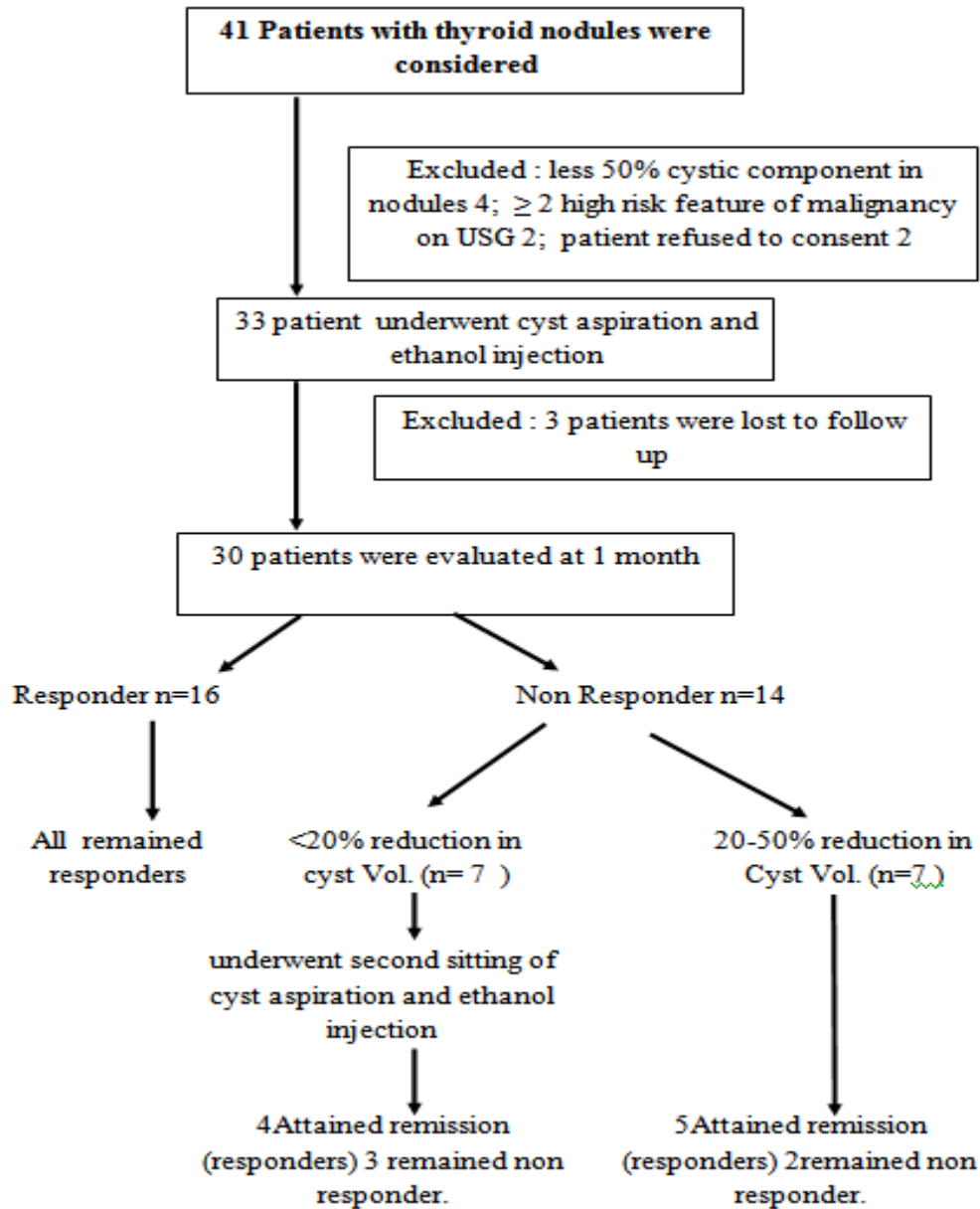


Figure-4: STUDY PROTOCOL

III. Result & Observations

TABLE- 01: VOLUME OF CYST BEFORE THE PROCEDURE

S NO .	VOLUME OF CYST (CC)	NO OF PATIENTS
1	2-10	26
2	11-20	2
3	21-30	1
4	31-40	0
5	41-50	0
6	51-60	0
7	61-70	1

TABLE- 02: COMPARISON OF RESULT

S NO	FINDING	RESULT
1.	Success Result	25/ 30 (83.3%)
2.	FAILURE	
	Failure (1-49% reduction)	4/30

	Failure (0% reduction)	1/ 30
	Total failure	5/30 (16.66%)
3.	Complete resolution	8/30 (26.6%)
4.	Repeat aspiration	7/30 (23.3%)
5.	Failure after repeat aspiration	3/30 (10%)
6.	Mean cyst volume	8.4 +/-11.8
7.	Complete reduction after 1 st follow up	3
8.	Complete reduction after 2 nd follow up	2
9.	Complete reduction after 3 rd follow up	3
10.	Complete reduction after all follow up	8

TABLE – 03: RESULT OF ETHANOL ABLATION OF THYROID COLLOID CYST IN TERM OF MEAN REDUCTION RATE (MRR)

VOLUME CHANGE (%)	PATIENTS		MEAN VOLUME OF CYST (ML)		MEAN REDUCTION RATE (%)	MEAN NO. OF SESSIONS OF ETHANOL INSTILLA-TION
	NO.	%	BEFORE ABLATION	AFTER ABLATION		
100	8	26.66	2.6	0	100	1.0
50-99	17	56.66	8.1	1.2	85.87	1.2
1-49	4	13.33	21	15.7	17.3	1.5
< /0	1	3.33	9	11	0	2
TOTAL	30	100	8.4	3.1	77.57	1.2

(volume reduction rate [%] = volume decrease [initial volume – final volume after treatment] / initial volume *100%).

In our study ,

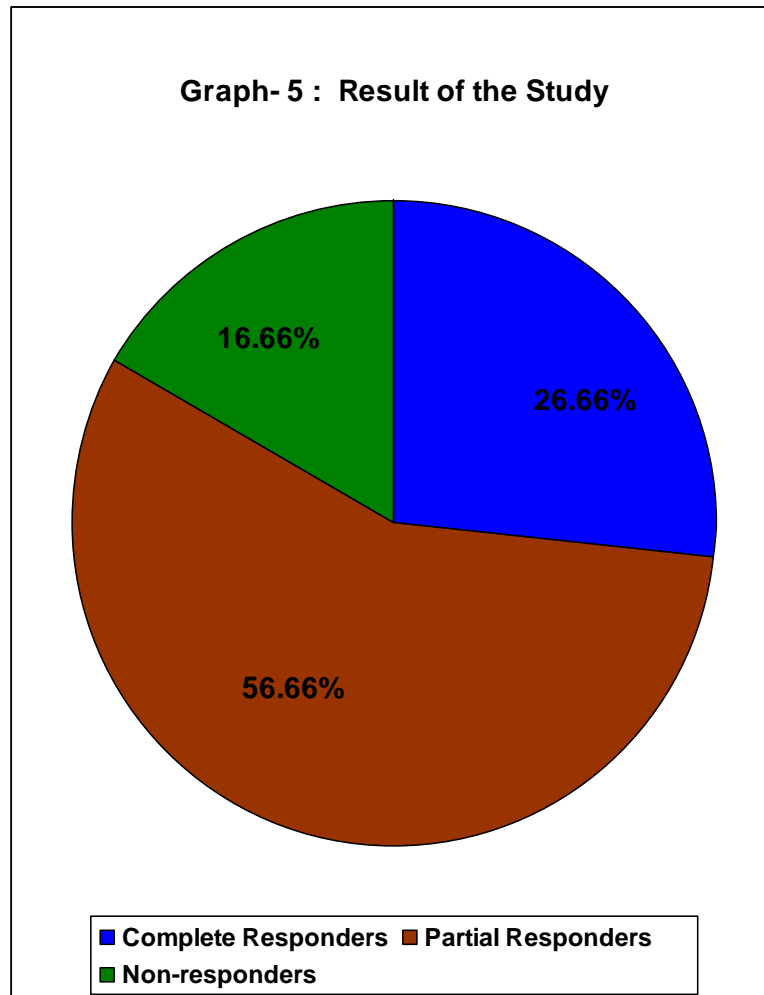
- MRR was found to be 100% in complete responder group on single session of ethanol instillation.
- MRR was found to be 85.87% in partial responder group (50-99% of volume change) on mean 1.2 session of ethanol instillation.
- MRR was found to be 17.3% in partial responder group (1-49% of volume change) on mean 1.5 session of ethanol instillation.
- MRR was found to be 0% in non responder group (0% of volume change) on two session of ethanol instillation

TABLE – 04: COMPLICATION DUE PEI

S.NO	COMPLICATION	NO. OF PATIENTS	PERCENTAGE
1	Mild Pain	4/30	13.3%
2	Moderate Pain	1/30	3.3%
3	Facial Flushing	1/30	3.3%
4	Drunken Sense	1/30	3.3%
5	Headache	1/30	3.3%
6	Mild Dizziness	1/30	3.3%
7	Perithyroid Ethanol Leakage	0/30	0%
8	Intracystic Hemorrhage	0/30	0%

TABLE – 05: RESULT OF THE STUDY

S.NO	OUTPUT	NO. OF PATIENTS	PERCENTAGE
1	Complete Responders	8	26.6%
2	Partial Responders	17	56.6%
3.	Non-responders	5	16.6%



IV. Discussion

¹ .In this study most of the patients were present with complaint of swelling with three patients present with complaint of local discomfort and one patient present with swelling and dysphagia.

Most cystic lesions of the thyroid are considered to be caused by hemorrhage and subsequent degeneration of preexisting nodules ^[2].

Thyroid cysts rarely accompany malignant neoplasia. These cysts present as thyroid carcinoma in an average of 5% of patients, a lower probability than that of solid nodules ^[8]. Pure cysts are associated with a lower probability of malignancy than mixed cysts ^[3]. Malignant thyroid cysts confirmed by fine-needle aspiration biopsy usually require surgical treatment. However, for benign thyroid cysts, percutaneous tetracycline instillation, ethanol ablation, or thyroid hormone suppression therapy can be performed. Among these treatments, percutaneous aspiration has shown a high recurrence rate of up to 58% depending on the size of the cyst. Hence, for the treatment of recurrent cases, methods such as thyroid hormone suppression therapy and sclerosant instillation (sodium tetradecyl sulfate, hydroxy-polyethoxy- dodecan, tetracycline, or ethanol) were performed^[9, 10]. Thyroid hormone suppression therapy was found to have no effect, whereas tetracycline instillation has been shown to be relatively effective. However, in a prospective study, researchers reported that tetracycline did not offer any advantage over isotonic saline in the treatment of thyroid cysts ^[11].

USG-guided PEI was first proposed by Livraghi *et al.*,^[6] in 1990 for autonomously functioning thyroid nodules, which were later extended to management of benign cystic thyroid nodules.

Yasuda *et al.*1992^[2] reported that with ethanol sclerotherapy, the cystic volumes decreased by more than half in 72% of the patients treated for recurrent thyroid cyst after fine needle aspiration biopsy. Cho *et al.* 2000 ^[12] also reported that in 68% of their patients with cystic nodules, the volumes decreased by 50% or more. According to their experience and other published studies on ethanol ablation, success is defined as near-disappearance or marked size reduction (>50%) of cystic lesion. In our study, 25 out of 30 patients (83.3%) showed complete disappearance or >50% reduction in cyst volume at the end of 3 months follow-up. 8 out of

30(26.6%) patients showed complete resolution of cyst after 3 month of follow up which is comparable to 4 out of 15 patients (26.6 %) of study conducted by SR Jayesh *et al* 2009^[13].

In our study 7 out of 30 patients (23.3%) showed < 20% reduction in cyst volume which underwent 2nd setting of cyst aspiration and ethanol injection and re-aspiration which is more as compared to 10 out of 62 patients (15.8%) in study done by Nupur Basu *et al* in 2014^[14].

In addition, the amount of aspirated fluid has an effect on the degree of ethanol ablation, but that was not quantified in our study. For example, ethanol ablation is more effective in pure serous cystic fluid than in gelatinous thick fluid. Further study of this effect is suggested.

Complications of ethanol ablation, such as local pain at the injection site, transient hyperthyroidism, transient hoarseness, hematoma, and dyspnea, have been reported by several investigators^[15-17]. Local pain at the injection site, the most common complication reported by all the investigators, occurs as a result of the leakage of ethanol into the subcutaneous tissue. Transitory hyperthyroidism has been reported by Antonelli *et al.*^[8] and Kobayashi *et al.*^[17]. In our study 5 patients (16.6%) experienced transient local pain due to the leakage of a small amount of alcohol followed by facial flushing, drunken sensation and headache which was observed in one patient. Major complications like intra-cyst hemorrhage and peri-thyroidal ethanol leakage was not observed. However, because a thyroid function test was performed before the ablation but not after the ablation, thyroid function could not be evaluated.

In our series, several points can be mentioned as limitations. First, sample size was small and short duration of follow-up.

Second, although the volume reduction rate was found to increase with an increasing amount of ethanol, we could not determine the effective amount of ethanol relative to the volume of a cyst or the amount of aspirated fluid.

V. Conclusion & Summary

In our study 30 patients of thyroid colloid cysts were taken with 20 complex cysts and 10 pure cysts. Out of 30 patients 25 patients showed significant (>50 %) reduction in cyst volume as compared to previous volume. 8 (26.6%) patients showed complete resolution of cyst volume (complete responder). Repeat aspiration done in 7(23.3%) patients who showed less than 20% reduction in cyst volume after 1st follow up. 3 (10%) patients showed failure after repeat ethanol injection. 5 (16.6%) patients showed failure with less than 50 % reduction in cyst volume. No significant adverse effect was noted during the procedure and follow up except for the local pain at the injection site.

In our study, PEA was not found to be good treatment option in term of complete disappearance of benign cystic thyroid nodules. But for cosmetic purpose, PEA was found to be a good treatment option with significant reduction in cyst volume. PEA is a cost effective, less time consuming, OPD procedure with no special instruments, machines required and with no special post procedural care needed. PEA is a very good treatment option for benign thyroid cystic nodules especially in Indian scenario where majority of the population is below poverty line and where there is overburden of patients.

In conclusion, percutaneous ethanol ablation is an effective non surgical treatment for cystic thyroid nodules rather than in solid nodules. It should be the treatment of choice for those benign cystic thyroid lesions large enough to cause local discomfort, cosmetic problems or anxiety in patients with no significant complications during the procedure and follow up.

References

- [1]. Bennedbæk Finn Noe And Hegedu Laszlo S: Treatment of Recurrent Thyroid Cysts with Ethanol:A Randomized Double-Blind Controlled Trial ; J Clin Endocrinol Metab, December 2003, 88(12):5773– 5777.
- [2]. Yasuda K, Ozaki O, Sugino K, Yamashita T, Toshima K, Ito K. Treatment of cystic lesions of the thyroid by ethanol instillation. World J Surg 1992;16:958– 961.
- [3]. Verde G, Papini E, Pacella CM, et al. Ultrasound guided percutaneous ethanol injection in the treatment of cystic thyroid nodules. Clin Endocrinol 1994;41:719– 724.
- [4]. Edmonds CJ, Telle ZM. Thyroid cysts and their managements. Br Med J 1987;295:529-33.
- [5]. Rozman B, Bence-Zigman Z, Tomic-Brzac H, Skreb F, Pavlinovic Z, Simonovic I. Sclerosation of thyroid cysts by ethanol. Periodicum Biologorum 1989;91:1116-8.
- [6]. Livraghi T, Paracchi A, Ferrari C, Bergenzi M. Treatment of autonomous thyroid nodules with percutaneous ethanol injection: preliminary results. Radiology 1990;175:827– 829.
- [7]. Hong YJ, Son EJ, Kim EK, Kwak JY, Hong SW, Chang HS. Positive predictive values of sonographic features of solid thyroid nodule. Clin Imaging 2010;34:127-33.
- [8]. Antonelli A, Campetelli A, Divito A, Alberti B, Baldi V, Salvioni G. Comparison between ethanol sclerotherapy and emptying with injection of saline in the treatment of thyroid cysts. Clin Investig 1994;72:971– 97416.
- [9]. Sykes D. The solitary thyroid nodule. Br J Surg 1981;68:510– 512.
- [10]. Porenta M, Fettich JJ. Treatment of thyroid cysts by sclerosation. Radiobiol Radiother (Berl) 1985; 26:249– 254.
- [11]. Hegedus L, Hansen JM, Karstrup S, Torp-Pedersen S, Juul N. Tetracycline for sclerosis of thyroid cysts. Arch Intern Med 1988;148:1116– 1118.

- [12]. Cho YS, Lee HK, Ahn IM, et al. Sonographically guided ethanol sclerotherapy for benign thyroid cysts: results in 22 patients. *AJR* 2000; 174:213– 216.
- [13]. Jayesh SR, Mehta Pankaj, Cherian Mathew P, Ilayaraja V, Gupta Prashanth, Venkatesh K. Efficacy and safety of USG-guided ethanol sclerotherapy in cystic thyroid nodules. *Indian J Radiol Imaging / August 2009 / Vol 19 / Issue 3*.
- [14]. Basu et al. Percutaneous ethanol ablation in managing predominantly cystic thyroid nodules: An eastern India perspective. *Indian Journal of Endocrinology and Metabolism / Sep-Oct 2014 / Vol 18 | Issue 5*.
- [15]. Ryan WG, Dwarakanathan A. Minor complication of thyroid cyst sclerosis with tetracycline. *Arch Intern Med* 1986;146:201– 202.
- [16]. Treece GL. Reply to Drs. Ryan and Dwarakanathan (letter). *Arch Intern Med* 1986;146:202.
- [17]. Kobayashi A, Kuma K, Matsuzuka F, Hirai K, Fukata S, Sugawara M. Thyrotoxicosis after needle aspiration of thyroid cyst. *J Clin Endocrinol Med* 1992;75:21– 24.

XXXXXX.” ‘ ‘ Effectiveness and Safety of Percutaneous Ethanol Ablation In Thyroid Colloid Cysts’ .” *IOSR Journal of Dental and Medical Sciences (IOSR-JDMS)*, vol. 17, no. 10, 2018, pp 64-70.