

## Neonatal Intestinal Obstruction

Author: Dr sanjay Sharma, Dr Satish parihar\*, Dr sanjay Raina, Dr Yogesh kumar

---

### **Absract:**

**Background:** Neonatal intestinal obstruction is one of the most common emergencies which presents with symptoms like vomiting, abdominal distension and failure to pass meconium. Early diagnosis with prompt resuscitation and exploration, if required is necessary to minimise resultant morbidity and mortality.

**Aim:** To do a prospective study of the pattern of neonatal intestinal obstruction in jammu region of jammu and Kashmir with emphasis on diagnostic workup, treatment modalities and their outcome.

**Design and Place:** This is a prospective observational study conducted on patients admitted in Post Graduate Department of Surgery, Govt. Medical College, Jammu. This study was conducted from 17<sup>th</sup> January 2016 to 16<sup>th</sup> January 2017.

**Material and Method:** 30 patients were admitted in whom proper diagnostic workup was done. 17 patients operated and the rest managed conservatively.

**Result:** Out of 30 patients, 17 patients were operated and remaining were managed conservatively. 8 patients died out of 30 patients. Out of 22 patients who survived, 3 patients left the hospital without treatment and 1 patient discharged on request. These 4 patients didnot return for follow up. The remaining 18 patients were followed up for a period of 3 to 6 months in whom growth and developmental mile stones were found to be within normal limits.

**Keywords:** Neonatal intestinal obstruction

---

Date Of Submission: 28-09-2018

Date of acceptance: 13-10-2018

---

### I. Introduction

Intestinal obstruction is one of the most common emergencies accounting for about 20% of admissions. In U.K., it is accounted for 23% of total admissions in a neonatal surgical unit. Unlike adults, obstruction of small intestine and colon in a paediatric age group are almost always due to congenital anomalies. Vomiting, abdominal distension and failure to pass meconium are symptoms of neonatal intestinal obstruction. It is a dictum that "any new born who has a yellow vomitus should always be considered as a case of intestinal obstruction unless proved otherwise". Clinical history, plain x-ray abdomen i.e. erect and supine films are sufficient to make diagnosis, ultrasonography may also be helpful to diagnose a condition like duplication of gastrointestinal tract. The purpose of these investigations is to know the cause of intestinal obstruction pre-operatively so that we may chart out a plan for further management. The aim for early diagnosis is to plan for prompt resuscitation and exploration to minimize the resultant morbidity and mortality in high risk neonates. Post operative outcome in these patients is determined by co-morbid factors like (1) delay in diagnosis and operative intervention (2) association of congenital anomalies (3) presence of necrotic bowel at laparotomy (4) low birth weight and young age patients.

### II. Material and methods

A detailed history of illness was recorded at time of admission in all neonates who were suspected to be suffering from intestinal obstruction. The history was asked from member of family who was mainly attending the sick neonate. Main stress in history was laid on following informations :-

- Vomiting, it's frequency , bile stained or otherwise
- history of passage of meconium/stools, it's frequency and color
- history of abdominal distension, jaundice, detailed antenatal history, detailed birth history and history of perinatal events
- gestational age at birth was asked (or calculated) in every case.

**Examination:-** it includes general physical examination, systemic examination and per-rectal examination.

**Investigations:-** the neonates were subjected to routine investigations including hemogram, coagulogram, liver function tests, renal function tests serum electrolytes. Plain abdomen radiograph including erect and supine films were done in all cases. Specific investigations were conducted as per the need.

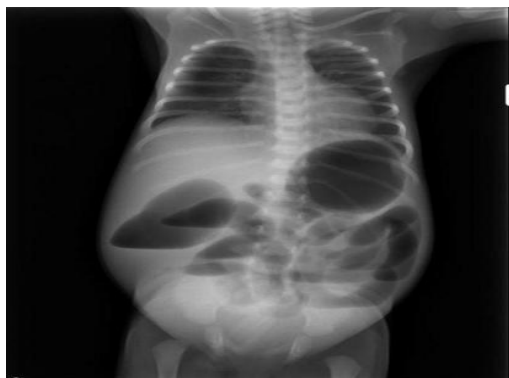
**Pre- Operative Management:-** hypothermia was avoided by keeping baby in warm environment, nasogastric tube was put in every case and nasogastric aspirate was noted for it's color, contents and volume and was replaced with equal amount of lactated Ringer's solution. Vitamin K 1mg was routinely administered as intramuscular injection. Broad spectrum antibiotics in appropriate doses were started pre-operatively.

**Operative procedures:-** out of 30 patients, 17 were operated and remaining patients were treated on the conservative line of management i.e. drip-suction and rectal washouts. In all cases of malrotation of gut and this intestinal atresia, surgery was performed through a right supraumbilical transverse incision. In cases with Hirschsprung's disease, Hartman's procedure was performed with end colostomy. In one patient with total colonic aganglionosis, loop ileostomy and appendectomy (for biopsy) was done. In case of annular pancreas, duodenoduodenostomy. In case of megacysticmicrocolon disease, exploratory laparotomy and colostomy was done.

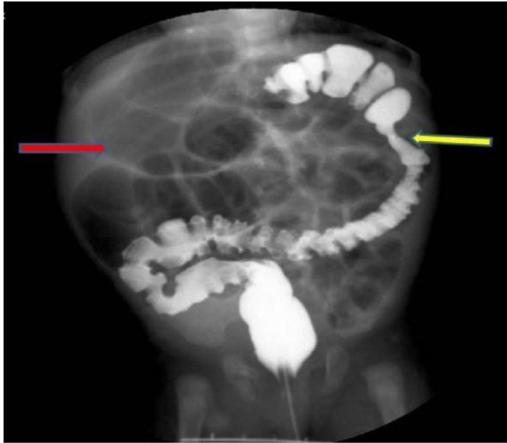
**Post operative care:-** all infants were returned to neonatal cabin and placed in warm humid and well monitored environment. Maintenance fluid were administered at 80-100 ml/kg/day. N/5 or N/4 saline 10% dextrose or isolyte P with 10% dextrose was used with potassium chloride. Losses replaced with equal volume of lactated ringer's solution. Urine output was maintained at 40-50 ml/kg/day. Passage of stool was observed between 3<sup>rd</sup> to 6<sup>th</sup> post operative day and antibiotics were continued for 7-10 days. Infants blood sugar, serum electrolytes and renal functions were monitored. Any complication was recorded and managed accordingly. Oral feeding was gradually started from 4<sup>th</sup> post operative day. After complete wound healing and recovery the patients were discharged and attendants advised for follow up in pediatric surgical OPD.

### III. Observation

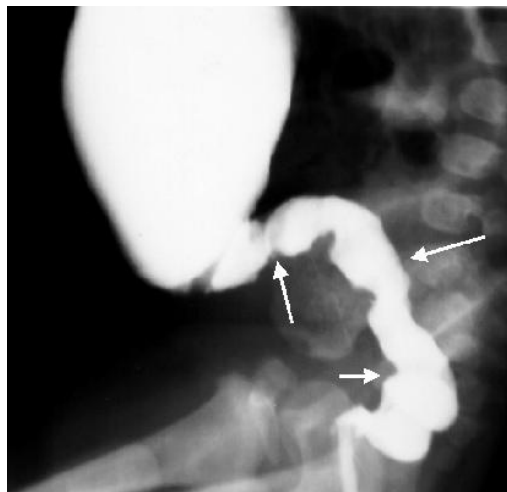
Minimum age at admission was 10 hours and maximum was 30 days. Mean age was 11 days. Out of 30 patients, 18 were males(60%) and 12 were females(40%). Average weight of neonates in our series with minimum weight of 1.75 kg and maximum weight of 4 kg was 2.25 kg. 10 cases(33.3%) had weight less than 2500grams. . Six patients out of 30 patients had associated congenital anomalies like undescended testis in 2 cases, congenital heart diseases, inguinal hernia, prune belly syndrome, polydactyly in case each. Bilious vomiting(15 cases), non/delayed passage of meconium(13 cases) and abdominal distension(2cases) were the main features of clinical presentation. Others features noted were respiratory distress, symptoms and signs of dehydration, jaundice and lethargy. 50% of cases could not pass meconium upto 24 hours after birth. Maternal factors like polyhydraminos were present in 3 cases, fever and drugs(other than iron and folic acid) in 2 cases each, and premature rupture of membranes, diabetes and pre eclampsia in 1 case each. In our series 6 neonates(20%) were premature, 6cases (20%) had jaundice( unconjugated bilirubin) and no positive family history. Malrotation of gut was present in 8 cases(26.7%), intestinal atresia in 6 cases(20%) and hirschsprung's disease in 5 cases(16.7%). Milk inspissation in 3 cases, meconium plug syndrome in 2 cases and 1 each case of small left colon sundrome, annular pancreas, megacystic microcolon disease,septicaemia, duplication cyst of gut and 1 case undiagnosed. Out of 30 cases, 17 were operated and others were managed conservatively i.e. drip suction and rectal washouts. Out of 30 cases 8 died and overall mortality was 26.6%. septicaemia was most common cause of death. Out of 22 patients who survived, 3 patients left hospital without treatment and 1 patient was discharged on request. These 4 patients didnot return for follow up. The remaining 18 patients were followed up for a period of 3 months to 6 months. Growth and development ( mile stones ) as recorded from time to time in the follow up were found within normal limits in all the cases. In three patients, iron deficiency anaemia was diagnosed and treated accordingly. Radiographical imaging shown in following images with signs of obstruction.



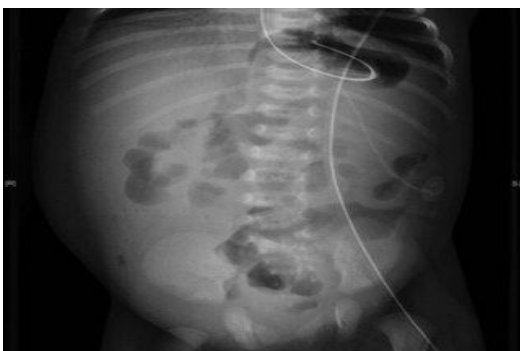Plane x ray abdomen of neonate with ileal artesian



A 2-month-old female exhibited delayed meconium passage and abdominal distension and vomiting at 10 days after birth. Barium enema revealed an arterian at the splenic side of the colon (yellow arrow), and an air shadow at the ileum (red arrow) indicating expansion.



Barium enema: The contrast material outlines a bowel segment without ganglions (arrows), above which prestenotic dilatation is visible.



Plain x ray abdomen of case of duplication cyst.

#### IV. Discussion

In our study age at admission varied from 1 day to 30 days and mean age was 11 days. For malrotation and Hirschsprung's disease mean age was 13.2 days each. For intestinal atresia was 1.95 days. In the experience of western authors Kieszewetter and Smith (1958), 55% of cases presented in the first 7 days of life and an additional 25% occurred in next 3 weeks of life. Total incidence in first 30 days of life was 80%. In another study by Ikeda and Goto(1984), a total 48.7%cases of Hirschsprung's disease were diagnosed in the month of life. Brown, stalewski, Brereton et al. (1991) noted age at admission in intestinal atresia was 1.7 days whereas in

our study was 1.95 days. Nasir, Raham and Kadim(2000) on neonatal intestinal obstruction concluded that there was male predominance which was also seen in our study. In our study 33.3% cases were below 2500 grams and only 3.3% cases were having weight more than 3 kgs. In our study cases of milk inspissations, meconium plug syndrome, small left colon syndrome, megacystic microcolon disease, jejunal atresia and septicaemia with intestinal obstruction were having weight less than 2.5 kgs. Nixon and Tawes(1971) classified babies with weight less than 4 pounds into high risk group with high mortality. Davis, Allan, Favara et al. (1974) described the association of meconium plug syndrome and small left colon syndrome with low birth weight which was also seen in our study. Lewis, Dickson and Swain (1977) described the association of prematurity and low birth weight with milk inspissations which was also seen in our study. One patient in our study with Hirschsprung's disease had polydactyly whereas Ikeda and Goto(1984) noted this anomaly in 6 patients of Hirschsprung's disease. In experience of Potts, Thomas, Gastrin et al (1985) bile stained vomiting was present in all the cases. Wesley and Mahor (1977) found bilious vomiting in 63 patients out of 72. In our study 50 cases had bilious vomiting. The incidence of prematurity in our study was 20% whereas Louw (1967) reported 42% incidence of prematurity associated with jejunoileal atresia. In our study jaundice was present in 20% cases whereas in experience of Touloukian (1993) jaundice occurs in about 40% of babies with proximal atresia and in about 20% of those with distal bowel atresia. In our study malrotation of gut was present in 26.6% cases and gut atresia in 20% cases and Hirschsprung's disease in 16.6%. Santulli and Amoury (1967) found malrotation of gut in 14.2%, gut atresia in 33% and Hirschsprung's disease in 14.2%. Adeyemi (1988) found mortality of 37% whereas in our study it was 26.6%.

## V. Conclusion

We conclude that there is still a room for improvement in the management of intestinal obstruction in a neonate in our set up. Any newborn who has yellow vomitus should always be considered as a case of intestinal obstruction unless proved otherwise and any neonate who fails to pass meconium in first 24 hours of life should be suspected of having intestinal obstruction unless proved otherwise. This fact should always be emphasised upon all the staff at all levels of health institutions attending the neonate, so that there is early referral to a specialised centre dealing with such problems. Discouraging deliveries at home especially by unqualified persons would be another important factor to improve the fate of such children.

## Bibliography

- [1]. Ghory HJ, Sheldon CA. Newborn surgical emergencies of the gastro intestinal tract. *The Surgical Clinics of North America*. 1985; 65:1083-1097.
- [2]. Ikeda K, Goto S. Diagnosis and treatment of Hirschsprung's disease in Japan. *Annals of Surgery*. 1984;199:400-405.
- [3]. Potts SR, Thomas PS, Garstin WIH, et al. The duodenal triangle: A plain film sign of midgut malrotation and volvulus in the neonate. *Clinical Radiology*. 1985;36:47-49.
- [4]. Santulli TV, Amoury RA. Congenital anomalies of gastrointestinal tract. *The Pediatric Clinic of North America*. 1967; 14:29-38.
- [5]. Louw JH, Barnard CN. Congenital intestinal atresia: Observation on its origin. *Lancet*. 1955 ;2:1065-1067.
- [6]. Louw JH. Resection and end to end anastomosis in the management of atresia and stenosis of the small bowel. *Surgery*. 1967; 62:940-954.
- [7]. Brown SP, Stalewski, Breton, et al. Neonatal small bowel atresia, stenosis, and segmental dilatation. *British Journal of Surgery*. 1991; 78:83-86.
- [8]. Kiesewetter WB, Smith J W. Malrotation of midgut in infancy and childhood. *Archives of Surgery*. 1958; 77:483-491.
- [9]. Adeyemi SD. Prognostic factors in neonatal intestinal obstruction: a prospective study of Nigerian newborns with bowel obstruction. *Journal of Pediatric Surgery*. 1988; 23:135-138.
- [10]. Touloukian RJ. Intestinal atresia. *Clinical Perinatology*. 1978; 5:3-12.
- [11]. Touloukian RJ. Diagnosis and treatment of jejunoileal atresia. *World Journal of Surgery*. 1993; 17:310-317.
- [12]. Wesley J R, Mahour GH. Congenital intrinsic duodenal obstruction: A twenty five years review. *Surgery* 1977; 62:716-720.
- [13]. Lewis CT, Dickson JA, Swain VA. Milk bolus obstruction in neonates. *Archives of disease of childhood*. 1977; 52:68.
- [14]. Davis D L, Poynter CWM. Congenital occlusions of the intestines. *Surgery Gynaecology and Obstetrics*. 1922; 34:35-41.
- [15]. Nasir GA, Rahma G and Kadim AH. Neonatal intestinal obstruction. *Eastern Mediterranean Health Journal*. 2000;6: 187-193.
- [16]. Nixon HH, Tawes R. Etiology and treatment of small intestinal atresia: Analysis of a series of 127 jejunoileal atresia and comparison with 62 duodenal atresia. *Surgery*. 1971;69:41-51.

Author: xxxx "Neonatal Intestinal Obstruction" IOSR Journal of Dental and Medical Sciences (IOSR-JDMS), vol. 17, no. 10, 2018, pp 61-64.