

S.R Cephalic Extractor for Delivering Fetal head during LSCS: A Preliminary study.

¹Dr. Samrtha Ram Hemmanur, ²Illa Sai Samyuktha, ³ H S. Shankar Ram.

¹MBBS, DGO, HOD, Senior Consultant, Department of Obstetrics and Gynecology, Sandhyaram Hospital, Katampazhi Puram, Palakkad, Kerala. PIN. 678633

²MBBS, MS (OB&G), Assistant Professor, Department of Obstetrics And Gynecology, GEMS Medical College Hospital, Ragolu, Sreekakulam Dst, Andhra Pradesh, India PIN. 532484.

³MBBS, MS, Mch Urology, Consultant urologist, Sandhyaram Hospital, Katampazhi Puram, Palakkad Dst, Kerala, Pin: 678633- INDIA

Corresponding Author: Dr. H. Samrtha Ram, email: drsamartharam@gmail.com Cell: 9447737327

Abstract

Background: To deliver the head while doing lower segment caesarean section, the current conventional practice is to insert fingers through the uterine wound between the head and the lower uterine segment till fingers reach below the head, and then the head is levered out. This procedure, sometimes results in irregular extension of angles of the wound, which may involve the uterine vessels, resulting in heavy bleeding. Irregular tearing of the uterine wound also leads to difficult suturing. To avoid this, we tried a specially developed instrument called cephalic extractor to deliver the head with success.

Methods: This instrument looks similar to that of a single blade of outlet forceps. Eighteen women with cephalic presentation, and two women with breech presentation, who underwent LSCS were included in this study. Caesarean sections done for fetal distress were excluded. Eleven of these women underwent trial of labor, and in 9 women no trial was given. We used two different methods, 'Direct' and 'Indirect' methods for its application. After opening the uterus by lower segment transverse incision, the instrument was applied and the head or breech was delivered by gentle traction. In case of deeply engaged head, the head was dislodged from pelvis by an assistant pushing it up from vagina, and then the instrument was applied. Lateral extension of the uterine incision wound, soft tissue injuries to mothers and neonates, APGAR scores at 1min and at 5min, and the time taken for the delivery of the baby were recorded in all women.

Results: No irregular tearing of the uterine wound and no soft tissue injuries to mothers or babies were observed. The APGAR scores of all neonates at one min were 9. The time taken for delivery was less than 1min in all women. In 2 women with deep transverse arrest, there was minimal lateral extension of wound.

Conclusion: Application of S.R Cephalic Extractor for delivering the head or breech at lower segment caesarean section is safe, helps for quick delivery of the baby, and avoids irregular tearing of the angles of the wound, which minimizes blood loss and helps for easy closure.

Keywords: S.R Cephalic extractor, Lower segment caesarean section.

Date of Submission: 25-12-2017

Date of acceptance: 13-01-2018

I. Introduction

Caesarean delivery of the baby is the commonest surgical operation done all over the world [1]. Since its inception in the year 1856, this surgical operation has undergone many modifications. The skin incision changed from midline to paramedian to suprapubic transverse incision. Hysterotomy incision changed from fundal midline to lower segment transverse incision. Suture material changed from catgut to vicryl. Wound closure from double layer closure to single layer closure. Peritoneum closure changed from closure to non-closure. In this study we attempted a specially designed cephalic extractor to deliver the presenting part at caesarean section to minimize irregular tearing of the hysterotomy wound, to reduce bleeding, and to facilitate easy closure.

II. Methods

Eighteen women with cephalic presentation, and two women with breech presentation, who underwent LSCS were included in this study. No trial of labor was given in 11 women, and in 9 women trial was given. Caesarean sections done for fetal distress were excluded from study.

2.1 Description of the instrument: It looks similar to that of ‘one half part of the outlet forceps’. It is having an application blade, shaft, and handle. The application blade is an elliptical curved loop. The longest diameter of the loop measures 9cm, and the shortest diameter measures 4cm. Its concave curvature fits on to the convex surface of the fetal head when applied. Its shaft measures 16 cm and the handle measures 8cm (Fig 1).

2.2 Technique of application, Indirect Method (<https://youtu.be/xpyaryz7zYM>):

After opening the lower uterine segment, head should be lifted up a little with left fingers, and then the blade inserted with right hand (Fig 2, A&B). While applying, the concave surface of the blade should face the legs. Maintaining the head elevation with fingers, the blade should be rotated to 180 degrees (C&D). While doing this, the hallow surface of the blade easily slips on to the convex surface of the head. With little manipulation, stable position of the blade can be attained, and then traction should be applied. If the blade slips after dislodging the head from first position due to traction (pull), the blade should be reset in another favorable position, and then traction (pull) should be applied. In a case of deeply engaged head, the head should be dislodged from deep pelvis by pushing it up from vagina by an assistant, and then the instrument can be applied.



Fig1. SR Cephalic extractor with application blade, shaft, and handle.

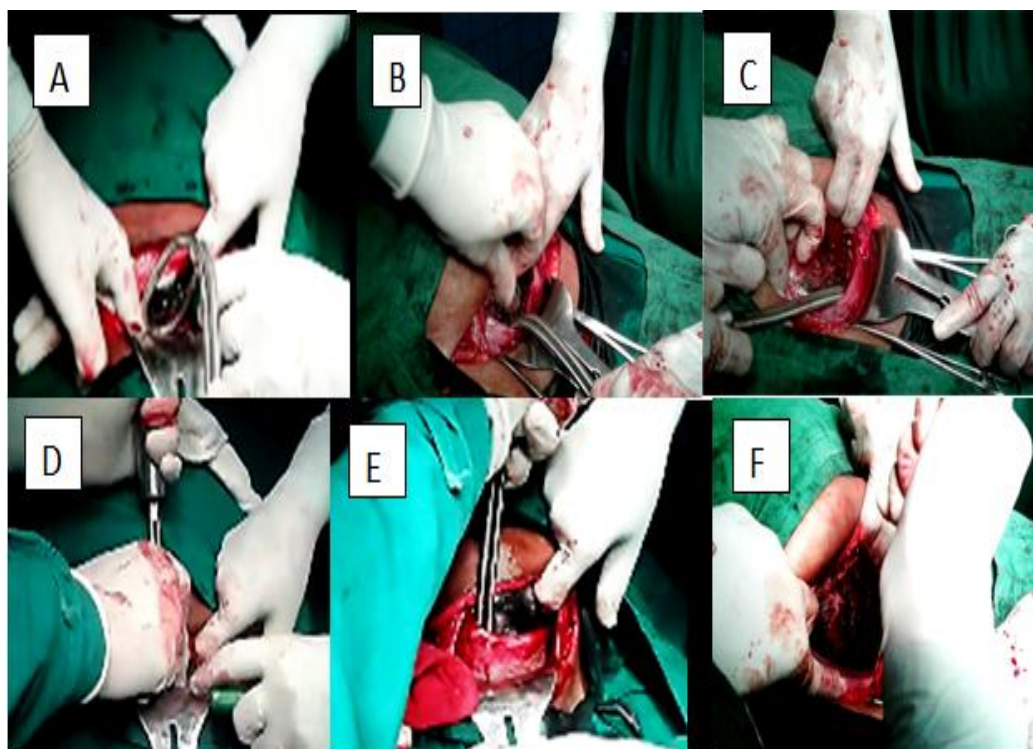


Fig 2 Different stages of ‘Indirect’ method of application of Cephalic extractor (A, B, C, D, E, and F) for delivering the head at lower segment caesarean section.

2.3 Direct Method (<https://youtu.be/1kLBH27AjuI>): In a case of high floating head, and when the gravid uterine size is small, sometimes the instrument can be easily applied by direct method. In this method, the concave surface of the blade should be directly applied on to the convex surface of the head (Fig 3).

2.4 For breech: Cephalic extractor can also be applied on the surface of breech in the similar way and can be delivered by applying traction. Lateral extension of the uterine wound, other maternal soft tissue injuries, soft tissue injuries to neonates, APGAR scores of neonates at 1min and at 5min, and the time taken for the delivery of the baby were recorded in all women. The number of ‘resets and pulls’ were also recorded in every woman. Informed and written consent was obtained from all subjects who participated in this study. This study confines to the standards of declarations of Helsinki.

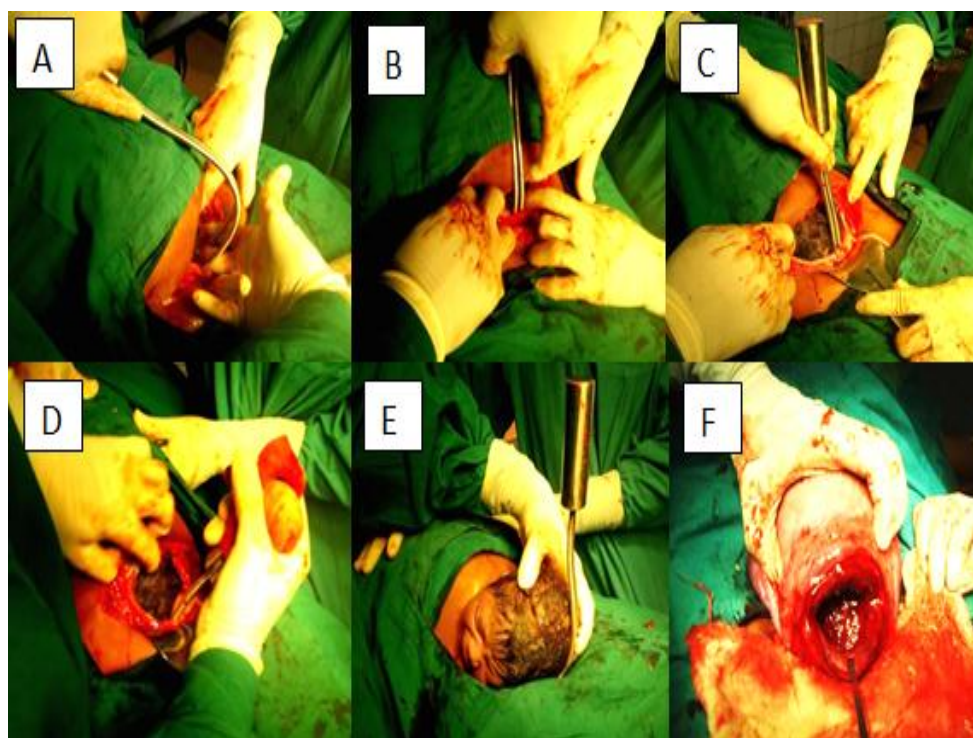


Fig 3: Different stages of ‘Direct’ method of application of Cephalic extractor (A, B, C, D, E) for delivering the head at lower segment caesarean section. F. Fish mouth appearance of the uterine wound after delivery of the baby.

III. Results

Among the 11 women, who underwent LSCS without trial of labor, 7 women had floating head, 2 women had floating breech, and 2 women had fixed head. In 9 women of ‘floating presenting part group’, we applied the instrument by indirect method in 6 women, and by direct method in 3 women. In 2 women, there was bleeding from the uterine wound which stopped after application of traction. Among the 9 women who underwent LSCS after trial of labor, we applied the instrument by indirect method in 7 women. In 2 women there was bleeding from the uterine wound, and we applied the instrument by direct method. The bleeding stopped when traction was applied. In 2 women there was deep transverse arrest, and we applied the instrument by indirect method after dislodging the head from deep pelvis by an assistant. In 13 women, two ‘blade re-settings and pulls’ were needed to deliver the presenting part, and in 5 women, we needed three ‘blade re-setting and pulls’. In 2 women there was no need for resetting of the blade, and the head was delivered by first ‘pull’.

3.1 Maternal outcomes: No irregular tearing of the uterine wound or any injury to soft tissues was observed in all mothers. In only two women there was minor lateral extension of the uterine wound without any undue blood loss. In all women, fish mouth appearance of the wound was observed after the delivery of the baby, and after contraction and retraction of the uterus (Fig 3-F). This helped us to close the uterine wound easily.

3.2 Neonatal outcome: The APGAR scores of all neonates at one min were 9. The time taken for the delivery of the babies was less than 1min in all women. None of the babies sustained any soft tissue injuries.

IV. Discussion

Caesarean section is the commonest surgical operation done all over the world [1]. Modifications for this operation continue to occur to improve the safety for both baby and mother, and also to improve the ease of doing. Delivering the fetal head is one of the important aspects of caesarean section. The current conventional practice is to insert fingers through the uterine wound between the head and the lower segment till fingers reach below the head, and then the head is levered out. Irregular tearing of the wound, lateral extension of wound involving the uterine vessels, heavy bleeding which is difficult to control, difficulty in delivering the floating head, and difficulty in delivering the deeply engaged head from pelvis, are the common problems that are faced [2]. In cases of thinned out and edematous lower segment, inserting fingers results in irregular tears that further leads to difficulty in suturing, and attaining hemostasis. Added component of placenta praevia further poses a real challenge to the obstetrician. Delay in delivering the baby may result in low APGAR scores, neonatal asphyxia and its consequences [3]. Current conventional practice to deliver the floating head at caesarean section is by application of outlet forceps or by Barton's forceps. Both these instruments have two application blades. Blades have to be applied on the biparietal diameter. The outlet forceps when applied during vaginal delivery, the angle of application of traction force is around 160 to 180 degrees. But the angle of traction force required to deliver the head at caesarean section is around 90 to 100 degrees. The application of Barton's forceps is very complex and time consuming. It can be applied only when the head is in transverse position [4]. Both the instruments cannot be used to deliver the breech.

V. Advantages

SR cephalic extractor is a more versatile instrument, and can be applied on floating or fixed head in any position, and also on breech. The angles of traction force that can be applied with this instrument vary from 90 to 100 degrees, which is ideal to deliver the presenting part at caesarean section. This instrument can be applied easily and quickly when compared with outlet forceps, Barton's forceps or vacuum extractor. The delivery time of the baby is less than one minute in our study. This technique avoids inserting fingers in to the uterus to deliver the presenting part. Application of this instrument avoids lateral irregular tears which sometimes lead to injury of uterine vessels. By applying traction with this instrument on presenting part, it helps to control bleeding from the uterine wound. As there is no irregular tearing, or extension of the uterine wound, the uterine wound appears like 'fish mouth' after the delivery of the baby, which helps for easy closure of the wound. This technique avoids pain to the fingers of the obstetrician when compared to manual delivery of the presenting part. As the width of the blade is small (4cm), and as there are no vital structures below the presenting part in the uterine cavity, and as there is enough space, 180 degree rotation of the blade can be easily accomplished without any injury to soft tissues. As the head is not fixed in a fixed frame like in forceps, head slips, but not get injured with this instrument. It is safe, and no instrumental injuries are observed either to the baby or to the mother in our study.

VI. Disadvantages

This instrument is like a single blade of the outlet forceps. As there is no opposite blade, it invariably slips when traction applied. If it slips after dislodging the head from one position, we have to reset the blade in another favorable position and then apply traction. The presenting part can be delivered in two or three 'resettings and pulls'. This instrument cannot be applied on deeply engaged head. But can be applied after dislodging the head from deep pelvis by an assistant pushing the head up from vagina.

VII. Conclusion

Application of S.R Cephalic Extractor for delivering the head or breech at lower segment caesarean section avoids irregular tears of the angles of the wound, helps for easy delivery of the presenting part, easy closure of the uterine wound, and also helps to prevent undue excessive bleeding. As this is a small study, the utility of this instrument has to be further evaluated by randomized controlled or comparative studies with larger sample size.

Conflict of interest: None.

Compliance with ethics.

References

- [1]. Thomas G Weiser, a Alex B Haynes, b George Molina, et.al, Size and distribution of the global volume of surgery in 2012, Bull World Health Organ 2016;94:201–209F | doi: <http://dx.doi.org/10.2471/BLT.15.159293>

- [2]. Kotdawala P.J., Pandya M.J; Difficulty in the Delivery of a Baby During LSCS.(eds) ‘Principles of Critical Care in Obstetrics’ Springer, New Delhi (2016)
- [3]. Janine E. Spain, Methodius Tuuli, Molly J. Stout, Kimberly A. Roehl, Time from Uterine Incision to Delivery and Hypoxic Neonatal Outcome : Amer J Perinatol 2015; 32(05): 497-502
- [4]. 4.John W Larsen Jr MD, Melissa Brunner MD, Sarah Gloria Obican MD; Barton's forceps: An effective aid in cesarean deliveries; Contemporary Obstetrics-Gynecology & Women's Health; September 01, 201

Dr. Samrtha Ram H, SR Cephalic Extractor for Delivering Fetal head duringLSCS: A Preliminary study.”IOSR Journal of Dental and Medical Sciences (IOSR-JDMS), vol. 17, no. 1, 2018, pp. 47-51.