

Bilateral Giant Open-Lip Schizencephaly: A Rare Case Report

*¹Dr Mohammad Hussain ,²Dr NipunGumber ,³Dr Sunil Kumar Agrawal

Department of Radiodiagnosis, Mahatma Gandhi Medical College , Jaipur

*Corresponding author: Dr Mohammad Hussain

Abstract: Schizencephaly is a congenital condition characterized by cerebrospinal fluid-filled clefts that extend from the pia surface of the cerebral hemisphere to the ependymal surface of the ventricle. The margins of the cleft are lined with heterotopic, dysplastic gray matter. Magnetic resonance imaging is the modality of choice for its diagnosis. The condition is present at birth and present early in life. Here we present an adult patient with schizencephaly presenting with first onset seizure.

Keywords: schizencephaly, lateral ventricle, magnetic resonance imaging

Date of Submission: 25-12-2017

Date of acceptance:12-01-2018

I. Introduction

Schizencephaly (split brain) is a gray matter-lined cerebrospinal fluid – filled cleft that extends from the ependymal surface of the brain through the white matter to the pia. It was first described in 1946 by Yakovlev and Wadsworth who coined the name ‘Schizencephaly’ as congenital clefts in the cerebral mantle, in their work on cadavers. Incidence worldwide has been put at 1.5 in 1,000,000 live births and 1:1650 among children suffering from epilepsy. Majority of cases are thought to be sporadic. No gender predilection has been noted Two types are recognized, which have prognostic significance. In type I or closed-lip schizencephaly, the cleft walls are in apposition and type II or open lip schizencephaly, in which the walls are separated. Schizencephaly type II occurs more commonly than type I.¹In either instance the cleft is lined by heterotopic gray matter. The clefts can be unilateral or bilateral, symmetric or asymmetric and can appear anywhere in the brain, although they usually are perisylvian.

II. Case Report

A 23 year old male patient came to neurology department for generalised tonic –clonic seizure. Following this he was referred for MRI scan of the head to our department. MRI brain revealed a large CSF attenuating lesion in bilateral temporo-parietal lobes. Both the lesions show gray matter lined CSF cleft extending from ventricle to the cortical surface. Based on radiological features, diagnosis of bilateral open lip schizencephaly was made.

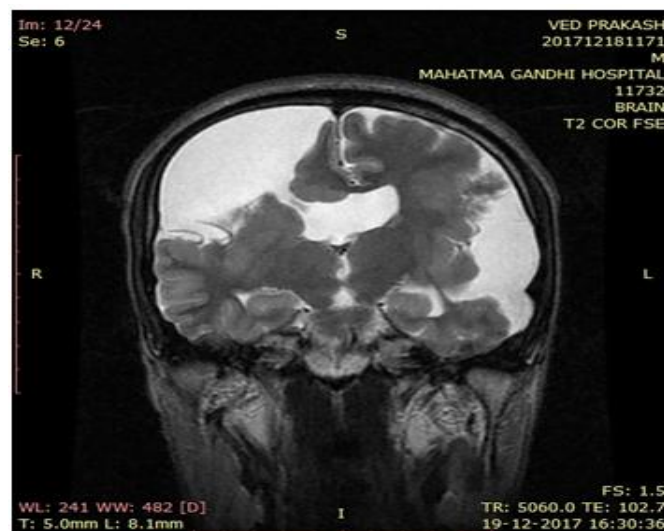

Figure 1 -Magnetic resonance imaging brain coronal section showing large cerebrospinal fluid attenuation gray matter-lined cleft present in both temporo-parietal region.

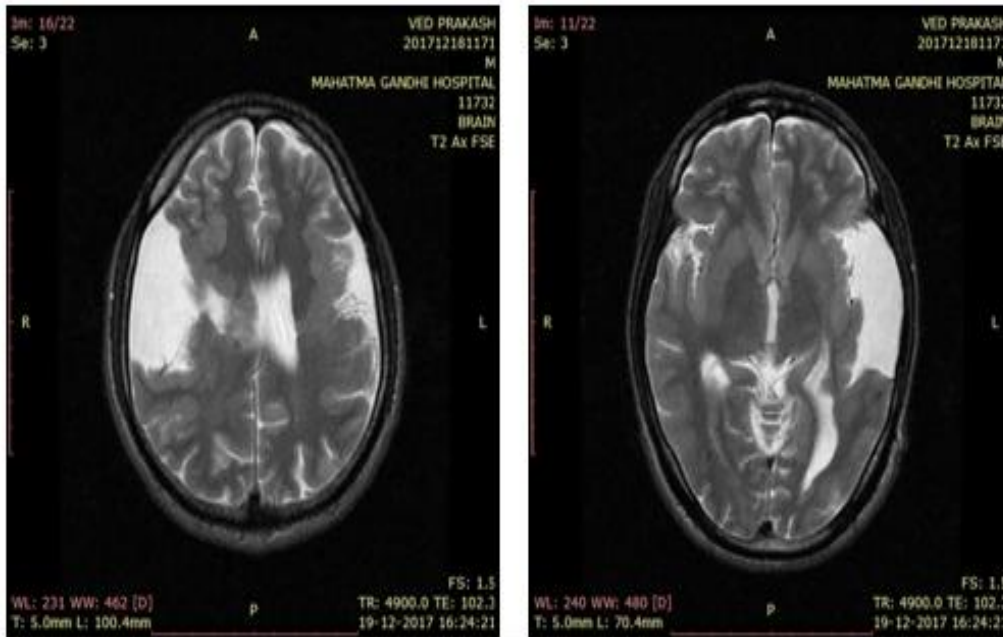


Figure 2&3--Magnetic resonance imaging brain axial section showing large cerebrospinal fluid attenuation gray matter-lined cleft present in both temporo-parietal region

III. Discussion

Several theories have been proposed to explain the etiology of schizencephaly, although none is universally accepted. Exact pathogenesis is not known, but an ischemic episode occurring at the 7th or 8th week of gestation has been hypothesized as an etiological factor. At the 8th week of gestation, neuronal migration starts to form the cerebral cortex from the germinal matrix. These primitive cells begin to migrate along radially oriented glial cells to the cerebral cortical regions. During this period, any insult of vessels in the region of germinal matrix may cause hypoxemia and infarction with arrest of migration of these neuroblasts.^[3] Other factors such as infection, metabolic disorders, and genetic defects also play a role in the development of schizencephaly. Two types are documented. Type I or closed lip where the walls of the clefts are opposed to each other and Type II where the walls are separated from each other. Type II is more common than Type I with 60% of unilateral schizencephaly being of the opened type. The clefts could be bilateral or unilateral, symmetrical or asymmetrical. It can occur anywhere in the brain. It is, however, more common in the parietal and frontal lobes, especially in the region of the Sylvian fissure.^[2] Our patient was presented with Type II bilateral schizencephaly. Presenting symptoms are quite variable and related to the amount of brain parenchymal involvement. In general, patients presented with hemiparesis, seizures, and developmental deficits. The severity of manifestations depends on the size and location of the clefts. Patients may present in infancy, childhood, or adults. Patients with closed-lip schizencephaly typically present with hemiparesis and/or motor delay whereas patients with open-lip schizencephaly usually present with hydrocephalus and/or seizures. Patients with closed-lip schizencephaly are more likely to have mild to moderate neurologic deficit than those with open-lip type. In our case, patient had hydrocephalus, seizures, and left hemiparesis. Holoprosencephaly, arachnoid cyst, hydranencephaly, and porencephaly are included in the differential diagnosis of schizencephaly. Porencephaly also extends from the cortical surface to the ventricular surface but is lined by gliotic white matter, not gray matter.^[4] MRI is the imaging modality of choice^[5] because of its superior differentiation of gray matter and white matter and its ability to image in more than one plane. Identification of gray matter lining the cleft is the pathognomonic finding.^[1] MRI shows the abnormal appearance of the cortical mantle along the cleft and the cortex appearing thicker than normal owing to the presence of polymicrogyria. The contralateral hemisphere may also have developmental abnormalities, such as polymicrogyria and subependymal heterotopias.^[6] Mild hypoplasia of the corpus callosum is commonly seen. The septum pellucidum is absent or nearly completely absent in 70% to 90% of affected patients. Of those with absence of the septum pellucidum, 30-50% will have optic nerve hypoplasia on clinical examination. Therefore, septo-optic dysplasia is, by definition, present in 20-45% of patients with schizencephaly.² Optic atrophy is usually easily recognizable clinically but is often difficult to confirm on imaging. In addition to the brain anomalies, in patients with open lip schizencephaly, CSF pulsations from the lateral ventricles result in pressure effects on the inner table of the skull.

References

- [1]. Bird CR, Gilles FH. Type 1 schizencephaly: CT and neuropathologic findings. *Am J of Neuroradio* 1987;Vol 8,(3):451-4
- [2]. Barkovich AJ, Norman D. MR imaging of schizencephaly. *AJR Am J Roentgenol* 1988;150:1391-6.
- [3]. Sarnat HB. Role of human fetalependyma. *Pediatr Neurol.* 1992;8:163–78
- [4]. Kopyta I, Jamroz E, Marszal E, Kluczevska E. Schizencephaly--clinical and radiological presentation of pediatric patients. *WiaLek.* 2006;59:471–6.
- [5]. Sarnat HB, Curatolo P. *Malformations of the Nervous System.* 1st ed. Edinburgh: Elsevier Publishers, Science Health Division; 2007. p. 235.
- [6]. Gunny RS, Chong WKK. Paediatric Neuroradiology. In: Grainger & Allison`s *Diagnostic Radiology.* 5 th Edition. Volume II. Churchill Livingstone Elsevier, 2008;1660

Dr Mohammad Hussain."Bilateral Giant Open-Lip Schizencephaly: A Rare Case Report."
IOSR Journal of Dental and Medical Sciences (IOSR-JDMS), vol. 17, no. 1, 2018, pp. 12-14.