

Analysis of Results of Closed Unstable Lower Third Tibial Fractures Treated With Interlock Intra-Medullary Nailing

R.Ram Prasad R.P¹, Dr.S.Sundar², PROF .Mohan kumar .M³.

(1,2 ,3)Department of orthopaedics/sriramachandra medical college and hospital, chennai

Abstract: This study aims in evaluating the functional and radiological outcome following intramedullary interlocking nailing (IMIL) in closed lower third tibial fracture. This prospective and retrospective study includes 15 patients of lower third tibial fractures with a mean age of 28.5 years, which have been treated by intramedullary interlocking nailing during the period 2010- 2016. Stable fixation was achieved in 15 patients. At the final follow up, the patients were evaluated functionally and radiologically based on JOHNER AND WRUH'S CRITERIA. The clinical results were excellent -8, good-5, fair-2 with average healing time of 28 weeks. The outcome was satisfactory in all cases and comparable with other larger series. Using intramedullary nailing resulted in good fracture reduction without complications.

Keywords: lower third tibial fractures, imil nailing, mal-alignment

Date of Submission: 26-12-2017

Date of acceptance: 12-01-2018

I. Introduction

The goal of management of a distal metaphyseal tibial fracture is to provide stable fixation with minimal additional soft-tissue injury. Individual case variables, including the extent of soft-tissue injury, should influence the ultimate treatment decision.

Cast treatment of tibial fractures requires prolonged immobilization. Maintaining reduction in a cast is difficult and requires frequent office visits, radiographs, and adjustments. External fixation may lead to diminished ankle motion. Small wire fixators allow early ankle joint mobility, but this treatment method is complicated by pin-tract infections, septic arthritis, mal-alignment, and delayed unions.

Open reduction and internal fixation provides stability, but causes devascularization of the underlying tibia. In addition, the subcutaneous location of plates may lead to symptomatic hardware requiring removal. Newer techniques of minimally invasive submuscular and subcutaneous plate fixation can address several of these issues, and predictable healing and a low rate of soft-tissue complications have been reported.

The role of intramedullary nailing in the treatment of distal metaphyseal fractures has not been well defined. Fixation with intramedullary devices is a technique that is already familiar to most surgeons. It spares the extraosseous blood supply, allows load-sharing, and avoids extensive soft-tissue dissection. Recent changes in intramedullary nail design have extended the spectrum of fractures amenable to this type of fixation.

II. Assessment Of Alignment And Union Of Fractures

The four most important criteria for judging alignment of the tibia are

1. angulation in the anteroposterior and mediolateral planes
2. shortening
3. rotational malalignment
4. displacement.

Fracture union was defined as radiographic evidence of bridging cortical bone on at least three cortices combined with the patient's ability to bear full weight on the extremity

AIM:

This study aims in evaluating the functional and radiological outcome following intramedullary interlocking nailing (IMIL) in closed lower third tibial fractures

III. Materials And Methods

This study was done at the Department of Orthopedic Surgery, Sri Ramachandra Medical College and Research Institute during the course period of JAN 2010 till APRIL 2016. It is a prospective and retrospective study. 49 cases of closed tibial fractures underwent IM nailing out of which 15 were of lower third fractures. Minimum follow up of 6 months to a Maximum of 2 yrs, Average healing time : 23 weeks, JOHNER AND WRUH'S CRITERIA was used for evaluation of final results

Inclusion criteria

- closed unstable lower third tibial fractures

Exclusion criteria

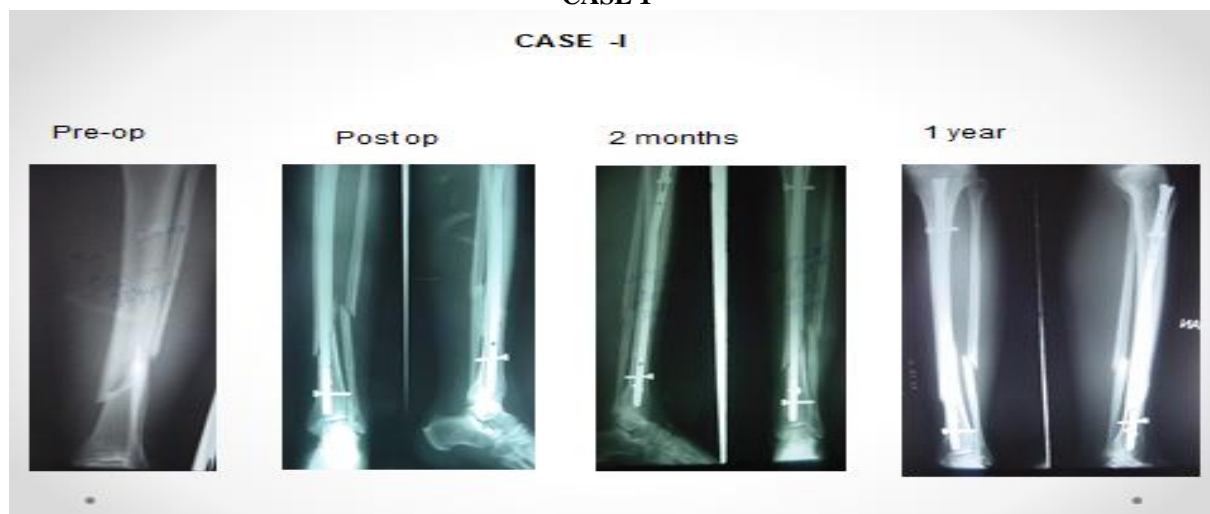- Open Tibial fractures
- Non union of tibial fractures.
- Intra-articular fractures.

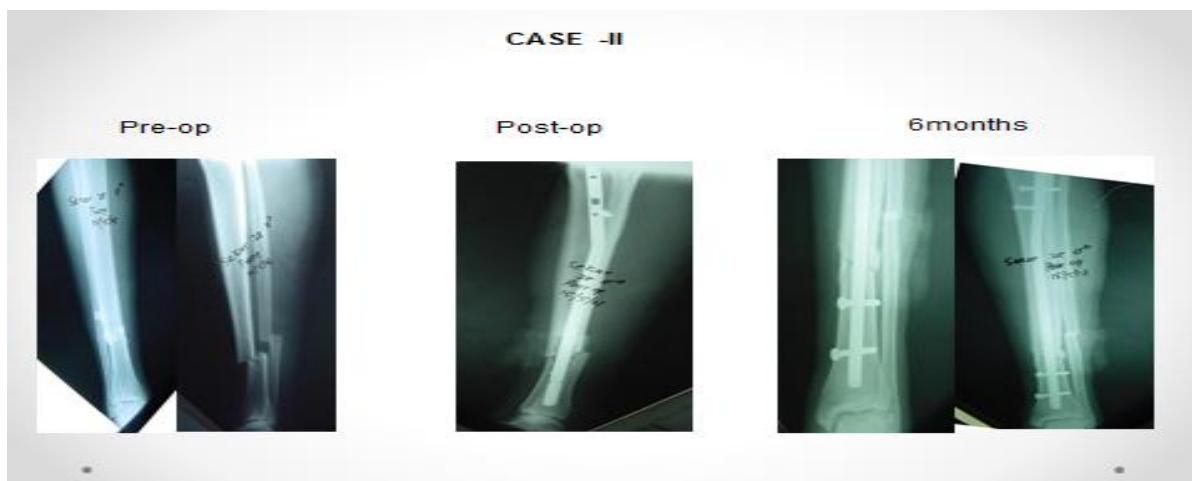JOHNER AND WRUH'S CRITERIA

Criteria	Excellent (%)	Good (%)	Fair (%)	Poor (%)
Nonunion/infection	None	None	None	Yes
Neurovascularinjury	None	Minimal	Moderate	Severe
Deformity				
Varus/valgus	None	2-5	6-10	>10
Pro/recurvatum	0-5	6-10	11-20	>20
Rotation	0-5	6-10	11-20	>20
Shortening	0-5mm	6-10mm	11-20mm	>20mm
Mobility				
Knee	Full	>80	>75	<75
Ankle	Full	>75	>50	<50
Subtalar	>75%	>50	<50	
Pain	None	Occasional	Moderate	Severe
Gait	Normal	Normal	Mild limp	Significant
Activities				
Strenous	Possible	Limited	Severely limited	Impossible

fractures distal to the tibial diaphysis and within 5 cm of the ankle joint may represent a different injury, they have been excluded from reports on intramedullary nailing of tibial shaft fractures . The distal segment of these fractures is more difficult to control with intramedullary implants because of the metaphyseal flare above the plafond. In addition, the poorer soft-tissue coverage in this region is associated with wound complications. The proximity to the ankle joint may amplify the bending moment of the short distal segment and may allow fracture propagation into the ankle joint.

CASE 1





OTHER SIMILAR STUDIES

Freedman, E.L et al in their study showed Intramedullary nailing of the tibia was performed on 145 tibiae (137 patients)

- 133 cases available for radiographic analysis of postoperative tibial alignment.
- 16 (12%) were malaligned
- Malalignment of 5° or more was seen in
 - 58% of proximal third fractures
 - 7% of middle third fractures
 - 8% of distal third fractures hence the low number of patients in or study

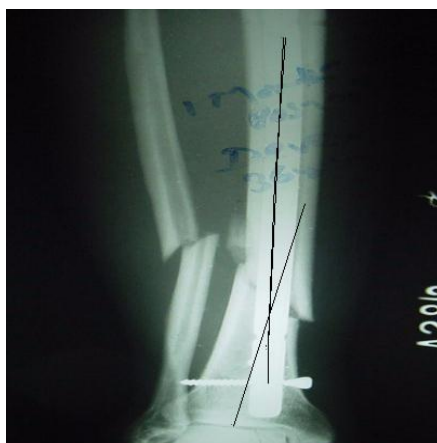
I. **Merchant, T. C. et al** in their study showed Clinical and radiographic outcomes were unaffected by the amount of anterior, posterior, varus, or valgus angulations. Their data suggest that angular deformities of less than 10 to 15 degrees are well tolerated over the long term with respect to the development of osteoarthritis, no patients in our study developed arthritis

IV. Results

Stable fixation was achieved in 15 patients . at the final follow up , the patients were evaluated functionally and radiologically based on JOHNER AND WRUH'S CRITERIA .

- Excellent - 8
- Good - 5
- Fair - 2
- Average healing time : 28 weeks.
- Valgus malunion- 2 (10 degrees).
- Varusmalunion- 1 (5 degrees).
- No nail or screw breakage

Complications



VALGUS DEFORMITY

We concluded that intramedullary nailing is a safe and effective technique for the treatment of distal metaphyseal tibial fractures. It avoids the additional soft-tissue dissection associated with traditional open procedures as well as the complications associated with external fixators. Newer nail designs allow the distal segment to be controlled through placement of multiple distal interlocking screws within a small distance above the tibial plafond. Alignment can be well maintained despite the short distal tibial segment, and a simple articular fracture or fracture extension is not a contraindication to intramedullary fixation.

References

- [1]. Court-Brown CM, McBirnie J: The epidemiology of tibial fractures. *J Bone Joint Surg Br.* 1995, 77: 417-421
- [2]. Alho A, Benterud JG, Hogevoid HE: Comparison of functional bracing and locked intramedullary nailing in the treatment of displaced tibial shaft fractures. *ClinOrthopRelat Res.* 1992
- [3]. Johner R, Wruhs O: Classification of tibial shaft fractures and correlation with results after rigid internal fixation. *ClinOrthopRelat Res.* 1983, 178: 7-25
- [4]. Distal tibia fractures: when is nailing preferred? Mohamed A.A. Mohamed MD , Mohamed Fadel , El-Minia University, El-Minia, Egypt. *Egyptian orthopaedic journal*
- [5]. Radiographic Analysis of Tibial Fracture Malalignment Following Intramedullary Nailing. Freedman, Eric L. MD; Johnson, Eric E. MD. *Clinical Orthopaedics & Related Research*: June 1995
- [6]. Long-term follow-up after fractures of the tibial and fibular shafts. Merchant, T C; Dietz, F R. *Journal of Bone & Joint Surgery - American Volume*: April 1989

R.Ram Prasad R.P"Analysis Of Results Of Closed Unstable Lower Third Tibial Fractures Treated With Interlock Intra-Medullary Nailing." *IOSR Journal of Dental and Medical Sciences (IOSR-JDMS)*, vol. 17, no. 1, 2018, pp. 56-59