

## Comparative Assessment of Success Rate of Indirect Pulp Treatment With 2% Chlorhexidine Gluconate Disinfecting Solution, Calcium Hydroxide And Resin Modified Glass Ionomer Liner In Primary Teeth - A Prospective Study.

Dr.Venkatesh Babu N S<sup>1</sup>, Dr.Kavyashree B S<sup>2</sup>, Dr.Amitha H A<sup>3</sup>

<sup>1</sup>Professor & Head, Department of Paediatric and Preventive Dentistry, Vokkaligara Sangha Dental College and Hospital, Bangalore, Karnataka, India.

<sup>2</sup>Post Graduate Student, Department of Paediatric and Preventive Dentistry, Vokkaligara Sangha Dental College and Hospital, Bangalore, Karnataka, India

<sup>3</sup>Senior lecturer Department of Paediatric and Preventive Dentistry, Vokkaligara Sangha Dental College and Hospital, Bangalore, Karnataka, India.

Corresponding Author: Dr.Venkatesh Babu N S

---

**Abstract:** Indirect pulp treatment (IPT) is a conservative and minimally invasive procedure, advocated more than 200 years ago. The study was done to assess the success rate of 2% chlorhexidine gluconate disinfecting solution (CHX) with calcium hydroxide (Dycal) and with resin modified glass ionomer liner (RMGIC) in IPT of primary molars. 60 primary molar teeth in children between the age 3 to 10 years were selected. Carious lesion approaching the pulp was removed followed by a dentin excavator to remove the caries at a site of "risk for pulp exposure". Teeth were then randomly assigned into two groups. Group 1 with CHX and dycal and Group 2 with CHX and RMGIC consists of 30 primary teeth in each. A final restoration of composite was placed. Children were evaluated at 3, 6, and at 12 month follow up interval. Clinically 97% and 100% of teeth in Group 1 and Group 2 respectively were successful at 3 month follow up interval. Clinical and radiographic evaluation of Group 1 and Group 2 at 6 month interval were 93% and 97% respectively. At 12 month interval clinical and radiographic evaluation of Group 1 and Group 2 were 80% and 97% respectively. 2% CHX with RMGIC is recommended over 2% CHX with dycal for indirect pulp treatment of primary molars.

**Keywords:** Calcium hydroxide, Indirect pulp treatment, Primary teeth, Resin modified glass ionomer liner, 2% chlorhexidine gluconate.

---

Date of Submission: 01 -01-2018

Date of acceptance: 11-01-2018

---

### I. Introduction

Preservation of the primary teeth in the oral cavity until its natural exfoliation time is very essential for normal oral function such as speech, esthetics, phonetics, mastication, facial growth and maintaining the arch integrity [1]. American Academy of Pediatric Dentistry guidelines state that maintaining the tooth integrity and preserving the surrounding tissues remain the key strategies in the treatment of primary teeth which are affected by injury or bacterial contamination. This is achieved through vital pulp therapy where the pulp vitality is maintained by eliminating bacteria from dentin - pulp complex and an environment is established in which tertiary dentinogenesis occur. The most frequently used vital pulp therapy for carious primary teeth is pulpotomy, but now indirect pulp treatment is used as an alternative vital pulp therapy which is potentially preferable and more viable [1]. In Indirect pulp treatment (IPT) a non-remineralizable carious tissue is removed and a thin layer of caries left at the deepest sites of the cavity preparation, where complete caries removal would result in pulp exposure [2]. Then a biocompatible liner is placed which stimulates healing and repair of the dentin pulp complex and the tooth is sealed with restoration that prevents microleakage [1].

Chlorhexidine gluconate is a chemical antiseptic available in the form of oral rinses, dentifrices, varnishes and gels which can be used as an irrigant and intracanal medicament. It has an inhibitory effect on both gram positive and gram negative organisms. Its efficacy is based on interaction between positively charged chlorhexidine molecule and negatively charged phospholipids and lipopolysaccharides of the bacterial cell wall, which changes the osmotic equilibrium of the bacteria. Hence there is an increase in permeability of bacteria to the chlorhexidine molecule results in coagulation and precipitation of cytoplasmic apparatus leading to bacterial cell death [1].

Most of the studies focused on calcium hydroxide, which is used as a liner or a base to cover the remaining carious dentin showed a high degree of success of 76% - 100% [3]. An important role of calcium

hydroxide is its ability to induce hard tissue formation and antibacterial action. Calcium hydroxide acts as a physical barrier by preventing reinfection and interrupt nutrient supply to the remaining bacteria. High pH (12.5) of calcium hydroxide shows destructive effect on bacterial cell membrane and protein structure. The hydroxyl ions from the calcium hydroxide diffuses into the dentin at sufficient concentration, exceeds the buffering ability of dentin and reaches the pH levels that sufficiently destroys bacteria [4].

Resin modified glass ionomer cement acts both as a base and restorative material because of ease in handling, increased mechanical characteristics, reduced microleakage, excellent sealing, antimicrobial activity, fluoride release, acceptable pulpal response, coefficient of thermal expansion similar to the tooth [5]. Studies have been done on calcium hydroxide and resin modified glass ionomer for indirect pulp treatment. Studies reported on comparing 2% chlorhexidine gluconate viscous solution with calcium hydroxide and on comparing resin system with calcium hydroxide for indirect pulp treatment. Till date there is no reported studies on comparing 2% chlorhexidine gluconate disinfecting solution with calcium hydroxide and with resin modified glass ionomer liner in indirect pulp capping. This study was undertaken to assess the success rate of CHX with dycal and with RMGIC in IPT of primary molars.

## II. Method

The present *in vivo* study comprises of 60 primary teeth in the children between the age 3 to 10 years, visiting the Department of Pediatrics and Preventive Dentistry. Institutional ethical clearance was obtained before conducting the study. Signed written informed consent was obtained from parents/caretakers. No history of spontaneous pain or tenderness to palpation or percussion and radiographic evidence of an intact lamina dura are indicated for indirect pulp treatment. Carious primary molars indicated for indirect pulp treatment in the children were randomly selected. Standardized periapical radiographs were taken. Children were treated under local anesthesia and rubber dam isolation. Undermined enamel was removed with the carbide bur (no.245) at high speed with copious air/water spray. Caries was removed completely from the cavosurface margin and the lateral walls of the cavity preparation with a carbide burs at a low speed, followed by a dentin excavator to remove the caries at a site of “risk for pulp exposure”. After then the cavity was washed and dried.

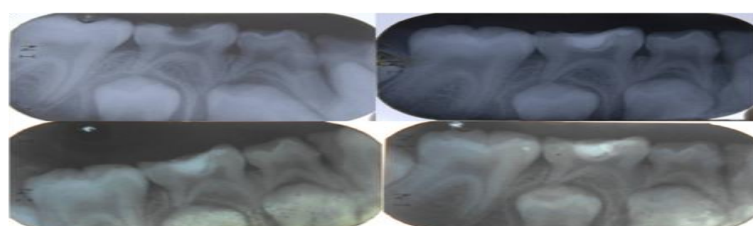
A sable seek caries indicator dye, (Ultradent product) was placed as per manufacturer’s instructions to see whether all infected dentin had been removed from the pulpal floor and washed with water after 15 seconds. The preparation was then air- dried to assess the colour of the dye. Areas stained with dark green indicated infected dentin and therefore removed and the areas stained with light green indicated affected dentin and were not removed. This procedure repeated until the infected dentin is completely removed from pulpal floor. A 2% chlorhexidine gluconate disinfecting solution (ultradent product) was then placed in the cavity floor for 60 seconds according to the manufacturer’s instructions and air dried. Teeth were then randomly assigned into study group and control group. Group 1 consists of 30 primary teeth treated with 2% chlorhexidine gluconate and calcium hydroxide (dycal, Dentsply) (as control group) and Group 2 consists of 30 primary teeth treated with 2% chlorhexidine gluconate and RMGIC (Fuji 2 LC, GC) (as study group). A final restoration of composite (Ivoclar) was placed according to the manufacturer’s instructions.

Children were evaluated clinically at 3 month interval while both clinical and radiographic evaluation at 6 and 12 month interval. Clinical success of the treatment was recorded when there was lack of tooth mobility, absence of pain and sensitivity associated with tooth, no tenderness on percussion or palpation, absence of any swelling of periodontal tissues or abscess of the treated tooth. Radiographically success of the treatment included intact restoration, intact lamina dura, lack of interradicular/periapical radiolucency or internal/external root resorption not related to the normal exfoliation process. Any tooth that presented symptoms or signs of irreversible pulpitis at clinical and/or radiographic evaluation was recorded as treatment failure and were pulpectomized or extracted. Recorded findings are subjected to statistical analysis.

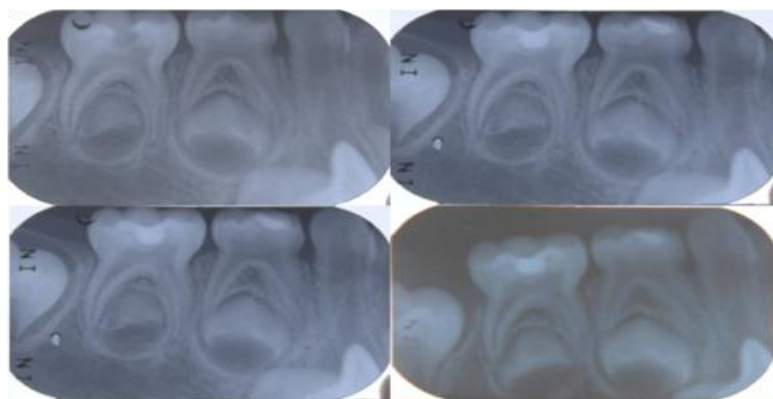
### Statistical analysis:

Chi- square test.

Level of Significance:  $\alpha=0.05$



**Figure 1:** Radiographic evaluation of calcium hydroxide (dycal) restoration (a) pre operative (b) at 3 month interval (c) at 6 month interval (d) at 12 month interval



**Figure 2:** Radiographic evaluation of RMGIC restoration (a) pre operative (b) at 3 month interval (c) at 6 month interval (d) at 12 month interval

### III. Results

Clinically 97% (29) of teeth in Group 1 (Chart 1) and 100% (30) of teeth in Group 2 (Chart 2) were considered successful after 3 month follow up interval. No significant difference was seen between two groups (Table 1, Graph 1). 3% (1) of the teeth in Group 1 was considered as failure. Clinically and radiographically 93% (28) of teeth in Group 1 (Chart 3) and 97% (29) of teeth in Group 2 (Chart 4) were considered successful after 6 month follow up interval. No significant difference was seen between two groups (Table 2,3, Graph 2). 3% (1) of the teeth showed failure in both Group 1 and Group 2. 3% (1) of the teeth in Group 1 was considered as failure since one child with dycal treated tooth did not turn for the follow up. Clinically and radiographically 80% (24) of teeth in Group 1 (Chart 5) and 97% (29) of teeth in Group 2 (Chart 6) were considered successful after 12 month follow up interval. Significant difference was seen between two groups ( $p < 0.05$ ) (Table 4,5, Graph 4). 17% (5) teeth in Group 1 and 3% (1) of the teeth in Group 2 showed failure. 3% (1) of the teeth in Group 1 was considered as failure since one child with dycal treated tooth did not turn for the follow up.

**Table 1.** Clinical evaluation of Group 1 and Group 2 at 3 month interval.

3 month	Group 1		Group 2		Mean	Std Dev	$\chi^2$	P-Value
	N	%	n	%				
success	29	97%	30	100%	0.020	0.129	1.000	0.317
failure	1	3%	0	0%				
Not followed	0	0%	0	0%				
Total	30	100%	30	100%				

No significant difference was observed at 3 months between the material groups ( $P > 0.05$ ).

Chart 1: Percentage distribution of success and failure at 3 months for Group 1.

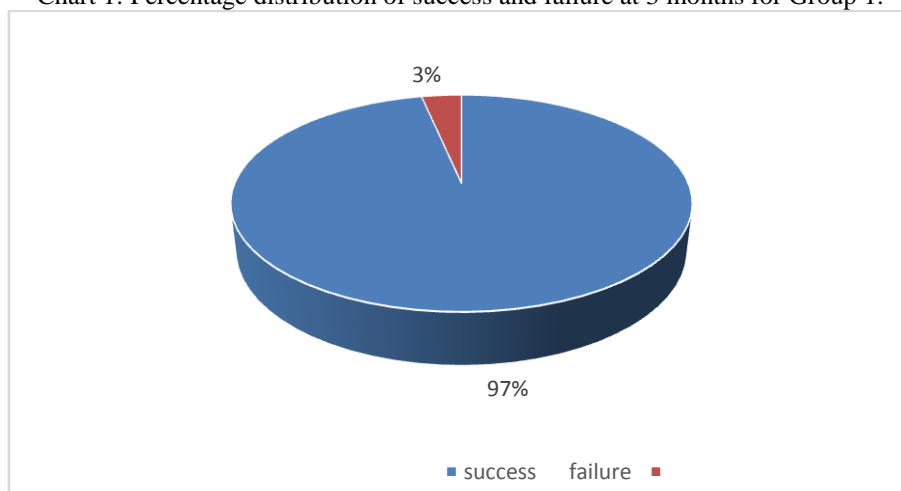
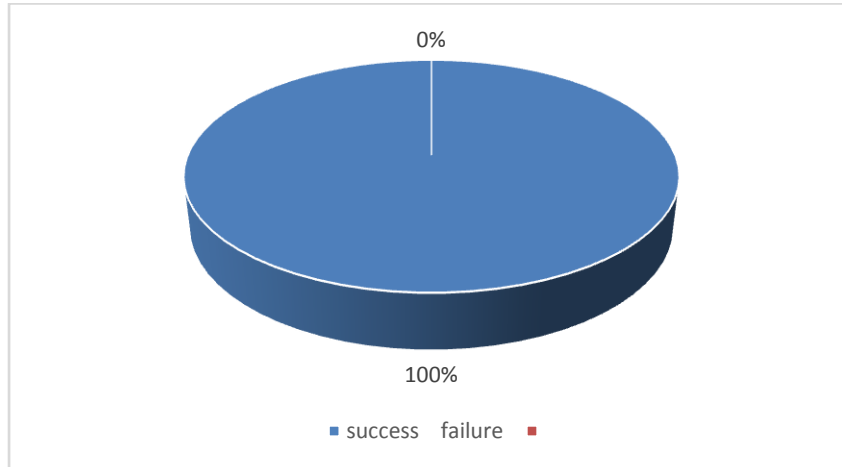
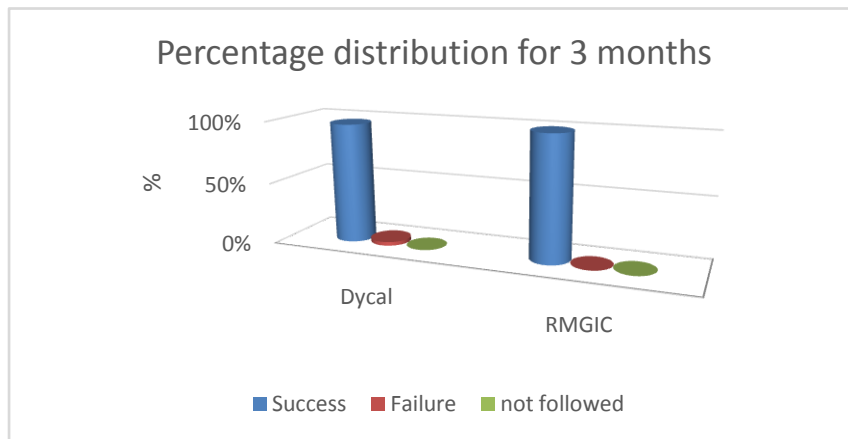


Chart 2: Percentage distribution of success and failure at 3 months for Group 2.



Graph 1. Clinical evaluation of Group 1 and Group 2 at 3 month interval.



**Table 2.** Clinical evaluation of Group 1 and Group 2 at 6 month interval.

6 month 1	Group 1		Group 2		Mean	Std Dev	$\chi^2$	P-Value
	N	%	n	%				
success	28	93%	29	97%	0.070	0.312	0.368	0.544
failure	1	3%	1	3%				
Not followed	1	3%	0	0%				
Total	30	100%	30	100%				

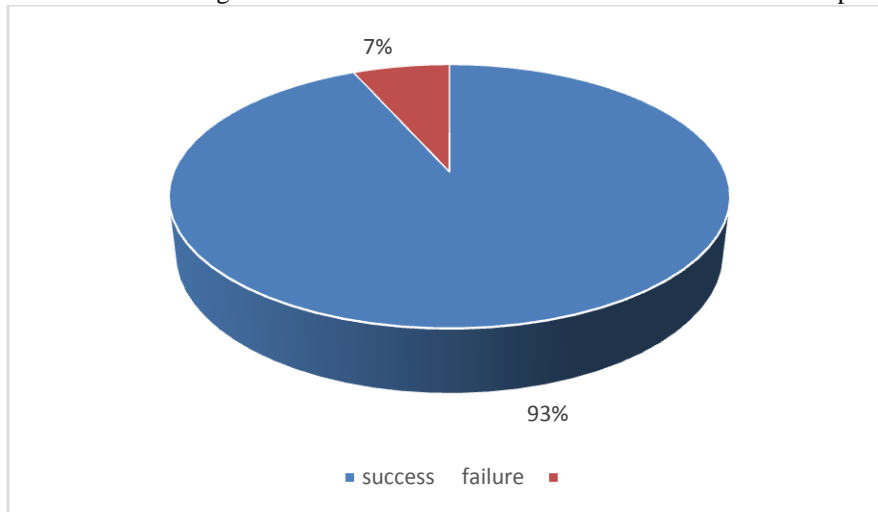
No significant difference was observed at 6 months between the material groups ( $P > 0.05$ ).

**Table 3.** Radiographic evaluation of Group 1 and Group 2 at 6 month interval.

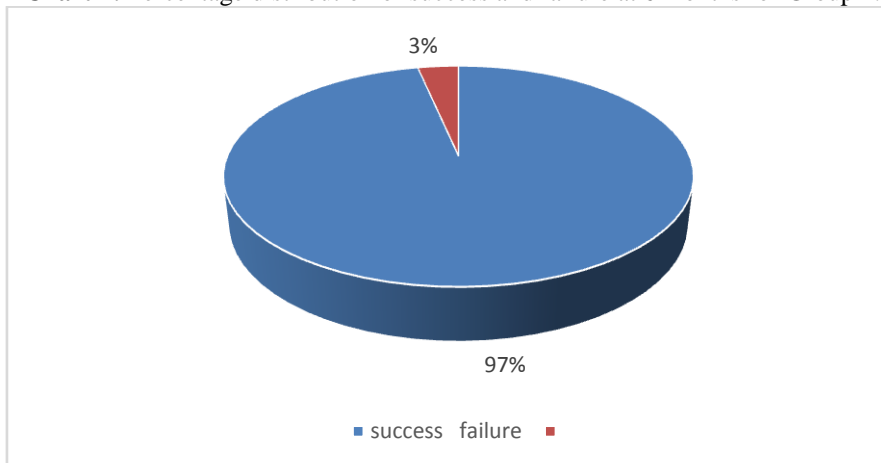
6 month 1	Group 1		Group 2		Mean	Std Dev	$\chi^2$	P-Value
	N	%	n	%				
success	28	93%	29	97%	0.070	0.312	0.368	0.544
failure	1	3%	1	3%				
Not followed	1	3%	0	0%				
Total	30	100%	30	100%				

No significant difference was observed at 6 months between the material groups ( $P > 0.05$ ).

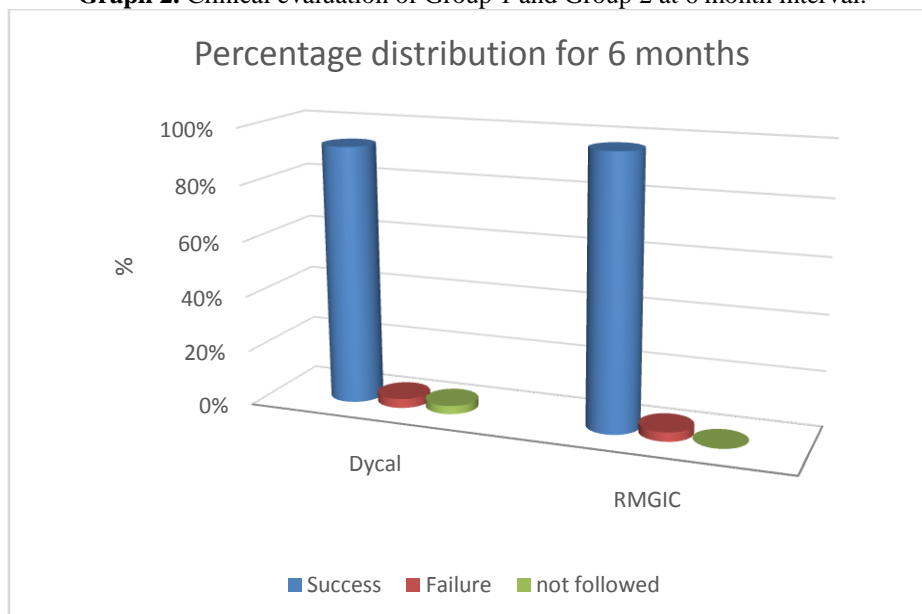
**Chart 3:** Percentage distribution of success and failure at 6 months for Group 1.



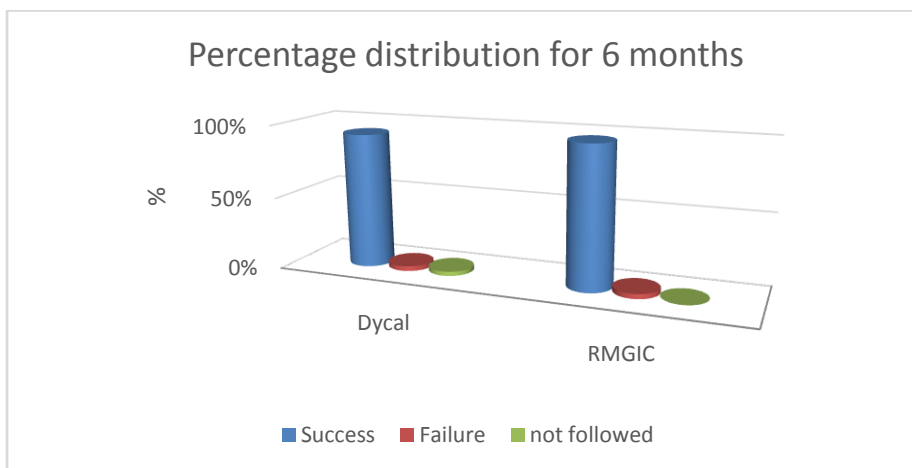
**Chart 4:** Percentage distribution of success and failure at 6 months for Group 2.



**Graph 2.** Clinical evaluation of Group 1 and Group 2 at 6 month interval.



**Graph 3.** Radiographic evaluation of Group 1 and Group 2 at 6 month interval.



**Table 4.** Clinical evaluation of Group 1 and Group 2 at 12 month interval.

12 month 1	Group 1		Group 2		Mean	Std Dev	$\chi^2$	P-Value
	N	%	n	%				
Success	24	80%	29	97%	0.133	0.389	4.0431	0.044*
failure	5	17%	1	3%				
Not followed	1	3%	0	0%				
Total	30	100%	30	100%				

\*Significant difference was observed at 12 months between the material groups(  $p < 0.05$ )

**Table 5.** Radiographic evaluation of Group 1 and Group 2 at 12 month interval.

12 month 1	Group 1		Group 2		Mean	Std Dev	$\chi^2$	P-Value
	N	%	n	%				
Success	24	80%	29	97%	0.133	0.389	4.0431	0.044*
failure	5	17%	1	3%				
Not followed	1	3%	0	0%				
Total	30	100%	30	100%				

\*Significant difference was observed at 12 months between the material groups (  $p < 0.05$ )

**Chart 5:** Percentage distribution of success and failure at 12 months for Group 1.

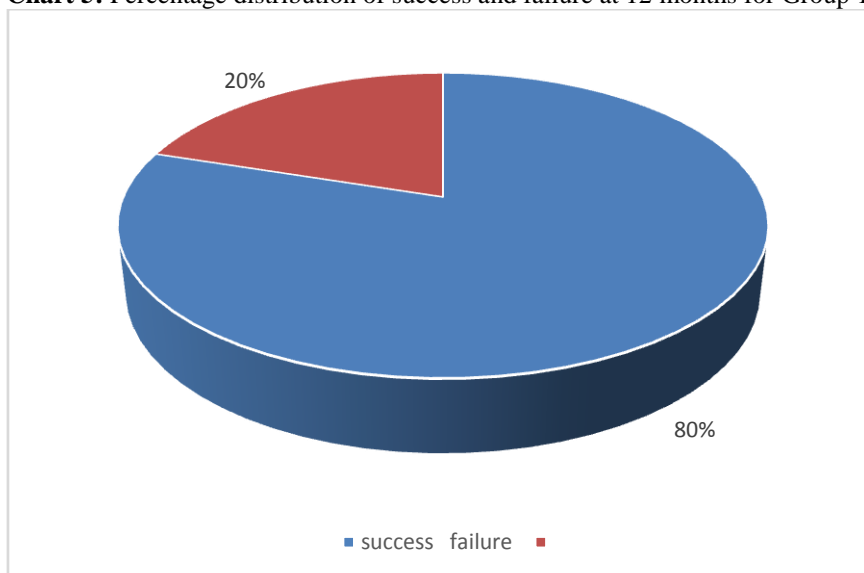
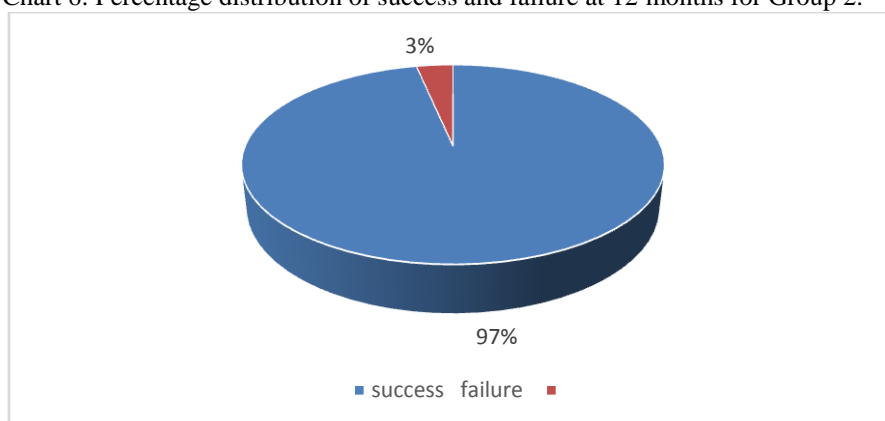
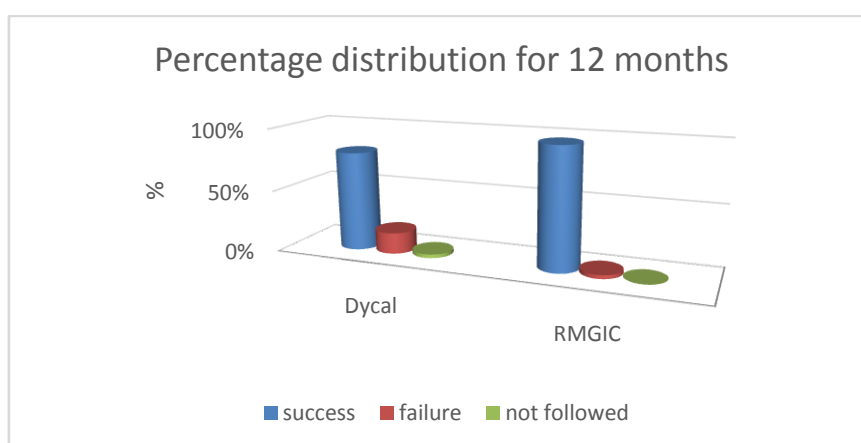


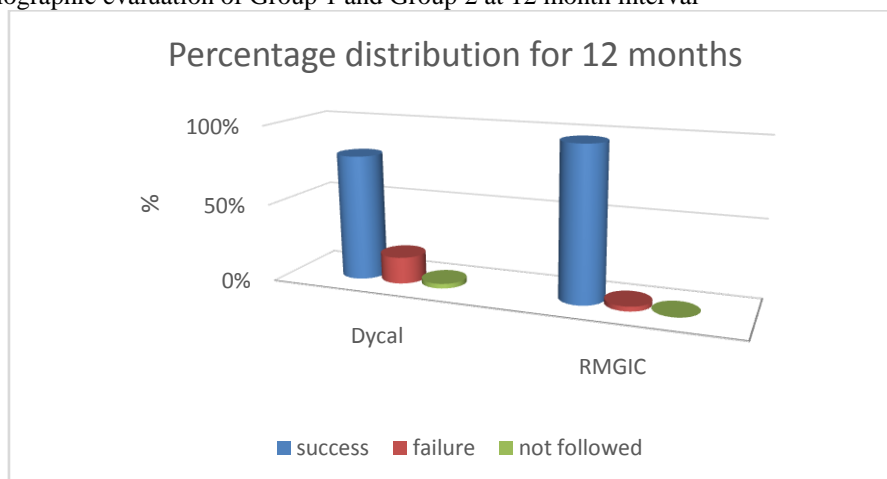
Chart 6: Percentage distribution of success and failure at 12 months for Group 2.



Graph 4. Clinical evaluation of Group 1 and Group 2 at 12 month interval.



Graph 5. Radiographic evaluation of Group 1 and Group 2 at 12 month interval



#### IV. Discussion

Indirect pulp capping has been advocated more than 200 years ago as a conservative and minimally invasive procedure [3]. The objective of this procedure is to maintain the vitality of teeth with reversible pulpal injury[4]. The clinical evaluation of Group 1 at 3 month follow up interval was 97% (29). Gomes et.al showed the combination of 2% chlorhexidine gluconate gel and calcium hydroxide was effective after 1-2 days demonstrating 100% antibacterial action against E.faecalis, and its antibacterial action reduced between 7-15 days [5]. Studies have been done on IPT with calcium hydroxide alone showed a high degrees of success (76%-100%)[2] . Carlos et al reported a qualitative increase in radiopacity of the calcium hydroxide and quantitatively

a statistically significant increase in total mineral content in the samples and concluded that a period of two weeks was sufficient to promote remineralization of carious dentin capped with calcium hydroxide, in vitro [6] .

The clinical evaluation of Group 2 at 3 month follow up interval was 100% (30). Similarly Rosenberg et al reported a 100% success rate of 2% chlorhexidine gluconate solution with a RMGI liner which was evaluated clinically at 3 month follow up interval [1]. Also Aline et al showed that the combination of RMGIC and CHX completely eliminated mutans streptococci after 3 months of IPT, also CHX significantly improved the antibacterial effects of the RMGIC, without affecting the odontoblast like cells and to the mechanical properties [7]. Similarly Luana et al also reported that GIC with CHX showed a best clinical result [8]. The results of these studies were in accordance with the results of our study. In contrast to this , Matilde et al showed a combination of 2% Chlorhexidine gluconate and RMGIC showed a bacterial coronal leakage at 45 days and concluded that the use of GIC without pretreatment of the dentine resulted in a significant delay of bacterial coronal leakage [9].

The present study showed no significant difference between two groups at 3 month follow up interval. 3% (1) was considered as failure in Group1 since the child had pain and sinus opening of the treated tooth and was pulpectomized. As far as it could be ascertained there were no studies in the available literature on comparing 2% chlorhexidine gluconate disinfecting solution with calcium hydroxide and with resin modified glass ionomer liner in indirect pulp capping of primary molars. However there were a few studies done using 2% chlorhexidine gluconate solution either with calcium hydroxide or RMGIC.

At 6 month follow up interval the clinical and radiographic evaluation of Group 1 was 93% (28). A total of 6% (2) failures were seen, with 3% (1) was considered as failure since one child with dycal treated tooth did not turn for the follow up interval. However there were no studies done using 2% chlorhexidine gluconate solution with calcium hydroxide in IPT at 6 month interval period. Studies on calcium hydroxide alone at 6 month follow up interval according to David et al showed that 76% of all deciduous and young permanent teeth with deep carious lesions were clinically and radiographically sound following application of a calcium hydroxide paste over residual caries for a six-month period, followed by complete excavation and restoration by conventional methods [10] .

The clinical and radiographic evaluation of Group 2 at 6 month follow up interval was 97% (29). 3% (1) was considered as failure in Group 2 since there was a loss of restoration. A study conducted by Rosenberg et al reported a ~98% success rate of 2% chlorhexidine gluconate solution with a RMGI liner, which was evaluated clinically and radiographically and one failure was seen at 6 month follow up interval [1]. The results of this study were comparable with the results of our study. The present study showed no significant difference between two groups at 6 month follow up interval.

At 12 month follow up interval clinical and radiographic evaluation of Group 1 was 80% (24) .A total of 20% (6) of the teeth showed failure of which 13% (4) failures were due to the defect in restoration, and were replaced. There were no studies done using 2% chlorhexidine gluconate solution with calcium hydroxide in IPT at 12 month interval period. The clinical and radiographic evaluation of Group 2 at 12 month follow up interval was 97% (29) 3% (1) of the teeth showed failure. Similarly Rosenberg et al reported a ~97% success rate of 2% chlorhexidine gluconate solution with a RMGI liner, which was evaluated clinically and radiographically and one failure was seen at 12 month follow up interval [1]. This was in accordance with our study. A statistically significant difference between two groups with a p value of 0.044 ( $p < 0.05$ ). However a long term follow up study conducted Marchi et.al showed no significant difference between calcium hydroxide and RMGIC used in IPC with regard to microhardness assessment of the remaining dentin with a success rate of 88.8% and 93% respectively after 48 months and concluded that indirect pulp capping in primary teeth arrests the progression of the underlying caries, regardless of the material used as a liner [11]. Other long term follow up studies in IPT using calcium hydroxide was conducted by Casagrande et.al who evaluated no statistical significant difference in clinical and radiographic outcomes of IPT in primary molars after long-term follow up of 60 months between self-etching adhesive system (Clearfil SE Bond) and calcium hydroxide liner (Dycal) groups (82.4% and 73.3% respectively) [12]. A retrospective study conducted by Al-Zayer et.al reported a success of 95% (178/187 teeth), with only 9 failures [3].

Studies on RMGIC conducted by Farooq et.al showed 93% success and 7% of failure in 2-7 years [2]. Kotsanos et al reported a high success rate of 96.5% after a 32-months follow-up [13] suggesting that resin-modified GICs helps to isolate affected dentine from oral bacteria. Gruythuysen et al performed a 3-year survival analysis and reported a survival rate for primary molars was 96% [14]. Though there were a long term follow studies conducted, the success rate reported here are comparable to the results of our studies.



## V. Conclusion

Hence proper pulpal diagnosis, sealing of cavity, and control of caries activity are of paramount importance for a successful treatment. Since there is no pulpal entry in IPT, cases of failure may occur in a short period of time, and these are reflected in terms of clinical and/or radiographic evaluations. 2% chlorhexidine gluconate with resin modified glass ionomer liner is recommended than 2% chlorhexidine gluconate with dycal in indirect pulp treatment of primary molars.

## References

- [1]. Linda Rosenberg, Michael Atar, Marcia Daronch, Amy Honig , Marshall Chey et al, Prospective Study of Indirect Pulp Treatment in Primary Molars Using Resin-modified Glass Ionomer and 2% Chlorhexidine Gluconate: A 12-month Follow-up, *Pediatr Dent* 2013; 35: 13-17.
- [2]. Naila S. Farooq, James A. Coll, Alan Kuwabara, Preston Shelton, Success rates of formocresol pulpotomy and indirect pulp therapy in the treatment of deep dentinal caries in primary teeth, *Pediatr Dent* 2000; 22:278-286.
- [3]. Mohammed A. Al-Zayer, MS Lloyd H. Straffon, MS Robert J. Feigal, Kathleen B. Welch, Indirect pulp treatment of primary posterior teeth: a retrospective study, *Pediatr Dent*. 2003;25:29-36.
- [4]. Caline A. Falster, Fernando B. Araujo, Lloyd H. Straffon, Jacques E. Nor, Indirect pulp treatment: in vivo outcomes of an adhesive resin system vs calcium hydroxide for protection of the dentin-pulp complex, *Pediatr Dent* 2002; 24:241-248.
- [5]. Gomes BP, Souza SF, Ferraz CC, et al, Effectiveness of 2% chlorhexidine gel and calcium hydroxide against enterococcus faecalis in bovine root dentine in vitro, *Int Endod J* 2003;36:267-75.
- [6]. Carlos Alberto Conrado, Remineralization of Carious Dentin.I: In Vitro Microradiographic Study in Human Teeth Capped by Calcium Hydroxide, *Braz Dent J* 2004; 15: 59-62.
- [7]. Aline Rogéria, Freire de Castilho, Cristiane Duque, In vitro and in vivo investigation of the biological and mechanical behaviour of rein-modified glass-ionomer cement containing chlorhexidine, *J dent*.2012;4 :155-163
- [8]. Luana Mafra Marti, Margareth da Mata, Beatriz Ferraz-Santos, Elcilaine Rizzato Azevedo, Elisa Maria Aparecida Giro, Angela Cristina et al, Addition of Chlorhexidine Gluconate to a Glass Ionomer Cement: A Study on Mechanical, Physical and Antibacterial Properties, *Braz Dent J* 2014; 25:33-7
- [9]. Matilde Ruiz, Pilar Baca, Maria-del Mar Pardo-Ridao, Maria-Teresa Arias-Moliz, Carmen-María Ferrer-Luque, Ex vivo study of bacterial coronal leakage in indirect pulp treatment, *Med Oral Patol Oral Cir Bucal*. 2013; 18:19-24.
- [10]. David B. Law, Thompson M. Lewis, The effect of calcium hydroxide on deep carious lesions, *Oral Surgery Oral Medicine Oral Pathology* 1961; 14:1130-1137.
- [11]. Marchi JJ, de Araujo FB, Fröner AM, Straffon LH, Nör JE, Indirect pulp capping in the primary dentition: a 4 year follow-up study, *J Clin Pediatr Dent*. 2006;31:68-71.
- [12]. Casagrande L, Bento LW, Dalpian DM, García-Godoy F, de Araujo FB, Indirect pulp treatment in primary teeth: 4-year results, *Am J Dent*. 2010 ;23:34-8.
- [13]. Kotsanos N, Arizos S, Evaluation of a resin modified glass ionomer serving both as indirect pulp therapy and as restorative material for primary molars, *Eur Arch Paediatr Dent*. 2011;12:170-5.
- [14]. Gruythuysen RJ, van Strijp AJ, Wu MK, Long-term survival of indirect pulp treatment performed in primary and permanent teeth with clinically diagnosed deep carious lesions, *J Endod*. 2010;36:1490-3.

Dr.Venkatesh Babu N S. "Comparative Assessment of Success Rate of Indirect Pulp Treatment With 2% Chlorhexidine Gluconate Disinfecting Solution, Calcium Hydroxide And Resin Modified Glass Ionomer Liner In Primary Teeth - A Prospective Study." *IOSR Journal of Dental and Medical Sciences (IOSR-JDMS)* , vol. 17, no. 01, 2018, pp. 68–77.