

## **Bilateral Infraclavicular Brachial Plexus Block with Subarachnoid Block for Anaesthesia in an Elderly Poly-Traumatized Patient –Case Report**

Fatungase OM<sup>1</sup>, Ogundipe AA<sup>1</sup>, Adebajo AA<sup>2</sup>

1. Department Of Anaesthesia, Olabisi Onabanjo University

2. Department of Orthopedics & Trauma, Olabisi University Teaching Hospital.

Corresponding Author: Fatungase Oluwabunmi M

---

**Abstract:** Multiple regional nerve blocks is an anaesthetic challenge but very useful in some cases. We illustrated doing a combination of dual-guided bilateral infraclavicular blocks and a subarachnoid block in a poly-traumatized elderly patient, we discussed our rationale for the anaesthesia and the pitfalls we avoided. While combination blocks are possible and becoming more frequent, careful considerations should be to avoid risk and minimize systemic local anaesthetic toxicity.

---

Date of Submission: 15-01-2018

Date of acceptance: 03-02-2018

---

### **I. Introduction**

Trauma is a cause of morbidity and mortality in the elderly<sup>1</sup>. They may result from falls or accidents, and lead to injuries involving more than one limb(s) or system(s). Anaesthetic management of such an elderly patient is unique and challenging because of the peculiar anatomic and physiological changes that occur in the elderly, predisposing them to morbidities under general anaesthesia. Regional anaesthesia and peripheral nerve blocks are useful when general anaesthesia is contra-indicated or poses more risk in the elderly who are not unlikely to have co-morbidities which predisposes them to more intra-operative and post-operative incidences.

Combinations of regional blocks can be applied when more than one region of the body is to be operated on. However such combinations will require careful informed decisions, appropriate expertise and proper monitoring in order to avoid or minimize risks and complications.

Thus we present a case of a poly-traumatized elderly man with multiple (upper and lower) limbs injury managed who had a combination of regional anaesthesia to highlight the anaesthetic procedure, technique, monitoring and outcome of surgery.

### **II. Case Report**

A 71-yearold man was brought into the Accident and Emergency section of the Olabisi Onabanjo University Teaching Hospital, Sagamu. Haven been involved in a moving vehicle accident as a pedestrian about 18hours prior to presentation. He was referred from a General Hospital about 50kilometres away. There was history of loss of consciousness since the accident, but no convulsion nor bleeding from the craniofacial orifices was recorded.

Initial physical examination by the casualty officer revealed an unconscious elderly man with glassgow coma scale [GCS] of 11/15, pale, afebrile, and well-hydrated. There were evidences of fractures of both upper limbs, and the right lower limb. A clinical assessment of a poly-traumatized patient with moderate head injury was made.

He was admitted, given intravenous Paracetamol 1g, Intramuscular Diclofenac 75mg and intravenous Dexamethasone 8mg statum and thereafter 8hourly for the first 48 hours. X-rays of the upper and lower limbs taken showed closed bilateral humeral fracture, open fracture of the surgical neck of the right fibula and transverse fracture of the right tibia. The upper limbs were placed in Plaster of Paris [POP] casts and the right lower limb on POP back slab.

The past medical history was insignificant. He had previously been exposed to local anaesthesia 2 years ago for bilateral cataract extraction which was uneventful

When the anaesthetic team reviewed in preparation for manipulative reduction of humoral fractures and external fixation of lower limb fractures, examination revealed a frail elderly man, conscious but confused. He had no signs of raised intracranial pressure, mildly pale [had been transfused with one unit of whole blood during admission, afebrile and well hydrated. Airway examination revealed no missing teeth but scattered dentition.

Respirator rate was 25 breathes/cycle. Chest was clinically clear. Pulse rate was 80 beats per min. The blood pressure could not be measured due to POP cast on both upper limbs. The first and second heart sounds were normal. Abdominal examination revealed no abnormality, other systems were essentially normal. Hemoglobin was 8g/dl, other investigations [electrolytes, urea & creatinine, Urinalysis, Electrocardiography[ECG], and Chest X-ray were within normal limits for patient's age.

The technique of anaesthesia was discussed with relatives, because patient was confused. The risks of general anaesthesia versus the risks of regional anaesthesia were explained to them. They were counseled for and consented to bilateral brachial plexus block for the upper limb surgeries, and sub-arachnoid block for the lower limb surgery.

He was transfused with a pint of whole blood preceding day while on the ward and two units were brought to the theatre. He was fasted for 8 hours.

In the theatre patient was placed supine on the table, with the head resting on a pillow. The upper limb casts were removed and monitors were attached for non invasive blood pressure, heart rate, oxygen saturation, temperature and ECG measurements. Intravenous fluid 500mls of Lactated Ringer's solution was put up.

The procedure was explained to the patient as much as he could understand.

The brachial plexus block was first done on the left side. The injectate was prepared by mixing 20mls of 0.5% plain bupivacaine [200mg] with 10mls of 2% lignocaine in adrenaline [200mg] and 10mls of sterile water, making a total of 40mls.

Aseptic procedure was used. The chest above the nipple line and the axilla was cleaned with chlorhexidine and the 99% alcohol and draped. A high frequency linear probe of 8 to 12MHz (A5, Sonoscape, China) was prepared and covered with a sterile sheath. A 22G stimplex peripheral nerve block needle (B-Braun., USA) was attached to EZstim nerve stimulator (Life Tech Inc, USA). The other probe was attached via an ECG electrode to the upper limb. The vertical infra-clavicular approach was used under ultrasound guidance and nerve stimulator guidance. The initial probe current was set to 2.0A, under direct ultrasound view the needle was directed through the skin, pectoralis muscles and pectoralis fascia just below the lateral third of the clavicle. The needle was directed behind the artery until contraction of the triceps muscle was seen, signifying closeness to lateral cord. The current was lowered whilst advancing the needle until the tip of the needle was close to the plexus and contraction occurred at a current of 0.5A. The 30mls of the prepared drug (injectate) was injected, in aliquots of 5mls each while monitoring the patient for signs of toxicity. Frequent aspirations were done during injection to prevent intravascular injection. The needle was then withdrawn and redirected to lie between the brachial vessels, with contraction of finger flexors seen as closeness to the medial cord. The remaining 10ml was injected as before. The needle was withdrawn. The process was repeated on the right side. The interval between the first and second block was 20 minutes, this timing, though deliberate, and was used so that the plasma level of local anaesthetics would not peak at the same time.

At the end of the procedure on the right side, surgical anaesthesia had been established on the left side. Thus the manipulative reduction was first performed on the left upper limb with the application of POP. Thereafter the right upper limb was similarly fixed.

At the end of the upper limb procedures patient was supported into the sitting position and kept there by assistants. He was preloaded with 500mls of Lactated Ringers solutions. A subarachnoid block was then done at the L4/L5 interspace using 2mls of 0.5% heavy bupivacaine under strict aseptic condition. The patient was put back into supine position with a head up tilt. After the block fixed and the maximum height of the groin (T12 dermatome), the external fixation for the right lower limb was done.

The procedures were well tolerated by the patient with the systolic blood pressure ranging from 150-120mmHg, and diastolic from 100-60mmHg. Pulse rate ranged from 72 to 90 beats per minutes. SpO<sub>2</sub> was between 95% and 97%.

He was given a total of one liter of lactated Ringers solution. And the whole procedure lasted for 190mins.

At the end of surgery he was transferred to the intensive care unit for close monitoring. Analgesia in the upper limbs lasted for about 18 hours. He was discharged to the ward after 24 hours with no critical incidence. He made good recovery and was discharged from the ward ten weeks later.

### **III. Discussion**

Peripheral nerve blocks are very useful substitutes for general anaesthesia when general anaesthesia is contra-indicated or carries a higher risk. The elderly are more sensitive to nerve blocks. Due to a gradual reduction in nerve conduction and associated loss of fat sheath that makes the nerve more susceptible to local anaesthetics<sup>2</sup> [LA]. Nerve blocks last longer in the elderly<sup>2</sup>. The nerve blocks can be administered under anatomical landmark with elicitation of paraesthesia, or guided by ultrasound scan, nerve stimulator or both (dual guidance). This dual guidance increases accuracy and reduces the risk of complications from trauma to nearby structures. Bilateral brachial plexus block are rarely done due to the increased risk of toxicity due to the

dose of the LA, and more risks of complications such as bilateral pneumothorax, bilateral phrenic nerve paralysis, and horner's syndrome<sup>3</sup>.

This elderly man was poly-traumatized with bilateral humeral fractures; right tibia and fibula lower limb fractures and also recovering from mild head injury. Options for the anaesthesia include general anaesthesia and regional techniques. General anaesthesia was more risky in this patient because of the possible rise in intracranial pressure intra-operatively from drugs and maneuvers such as laryngoscopy and intubation. It would also have caused delayed recovery from general anaesthetics, requiring more intense post-operative care. There is also a potential risk of difficult intubation from the dental malocclusion. Postoperative cognitive dysfunction (POCD), confusion and delirium are also common after major surgery in the elderly. Regional anaesthesia has been found to reduce the incidence of POCD in the first postoperative week<sup>4</sup>. No sedation was given to this patient because of the need to monitor the altered mental status.

Literature search shows that bilateral brachial plexus blocks are rare and only used in extreme cases<sup>3</sup>. Reports of its usage have therefore been anecdotal. Chiang and colleagues<sup>5</sup> reported a case of a 36-year old multiple-injured woman, with head injury, and bilateral upper limb fractures, who had bilateral continuous ultrasound guided [USG] infraclavicular brachial plexus block. Initial general anaesthesia had resulted in raised intracranial pressure intra-operatively which led to the surgery being abandoned. Franco et al<sup>3</sup> did bilateral brachial plexus in a 36 year old AIDS patient with multiple upper limb abscesses. They performed supra-clavicular block on the right, and an axillary block on the left with the aid of a nerve stimulator. The left limb had more distally placed lesions amenable to axillary block. BhatPai RV and others<sup>6</sup> also did a similar combination of a supraclavicular and an axillary brachial plexus block in a patient with hypertrophic obstructive cardiomyopathy requiring an emergency upper limb surgeries from trauma. Both blocks were done under the elicitation of paraesthesia alone, but they were done at least two hours apart. This time interval was to allow for dissipation of the bupivacaine used from the system to avoid toxicity. Franco and BhatPai RV avoided doing a bilateral supraclavicular block because of the associated risks of pneumothoraces. However, Vasquez MI et al<sup>7</sup> did a continuous bilateral USG supraclavicular block for a patient with bilateral upper limb fractures who developed severe post operative pain. The blocks were done solely for post operative analgesia. In this case report, the safety of having two infraclavicular blocks was ensured by doing them under ultrasound guidance, since supra-clavicular blocks have more risks than infraclavicular blocks. In a bid to observe the efficacy of low dose bilateral infraclavicular blocks. NavParkash S. Sandhu<sup>8</sup> reported a case series of eight patients who had a bilateral infraclavicular block with low dose lidocaine (20mls on each side) under USG. Some had catheter inserted for continuous pain relief. He did not report any complications. A similar procedure was done by Murat Tekin<sup>9</sup> for bilateral hand surgeries in a 28 year old. He however used 20mls of solution containing levo-bupivacaine and lignocaine in adrenaline. Similarly, bilateral USG infra-clavicular nerve blocks in a 26 year old with bilateral radial fracture were done by Purtuloğlu T, Şenkal S. He concluded that bilateral brachial plexus blockade must only be performed under US guidance, and that infraclavicular route is also preferred because it has high success and low complication rate<sup>10</sup>. We did not find any locally published report of bilateral brachial plexus block and subarachnoid block (SAB) being done simultaneously.

The choice of a bilateral, dual-guided infraclavicular block was preferred for this patient because it was safer<sup>11</sup>. Other options that others may have considered in similar circumstances include a cervical epidural but since a subarachnoid block was scheduled for the lower limb procedure, we would have been risking a complete spinal block. Interscalene and supraclavicular approaches are other options but are more difficult and potentially associated with more risks than infraclavicular, especially if done bilaterally<sup>3</sup>. These risks include bilateral phrenic nerve paralysis with diaphragmatic paralysis, severe hypotension, recurrent laryngeal nerve block, and in the case of supraclavicular block, pneumothoraces. Phrenic nerve paralysis is almost non-existence in infraclavicular blocks<sup>11</sup>.

For the lower limb surgery a subarachnoid block was preferred. Alternatives to this includes a lumbar epidural, femoral or three-in-one blocks. Earlier 200mg of bupivacaine had already been used for the bilateral upper limb blocks, patient's weight was estimated to be 75kg, maximum safe dose of bupivacaine of 3mg/ml was 215mg, leaving us with only a margin of 15mg of bupivacaine to use after the brachial blocks. However some authorities could still have gone higher to 4mg/kg. Epidural or local limb blocks would have required more doses of bupivacaine. It was also possible to perform a unilateral spinal block to reduce the risk of hypotension, but the bilateral upper limb injuries precluded positioning for such in this patient. Therefore a low dose 2mg/kg body weight of heavy bupivacaine was used for the SAB. The dose of bupivacaine was within the safe limit, and the block was adequate for the lower limb procedure.

The use of dual guidance was to reduce to minimum the risk of failed block or other complications to minimum, at the cost of increased time for block performance.

#### IV. Conclusion

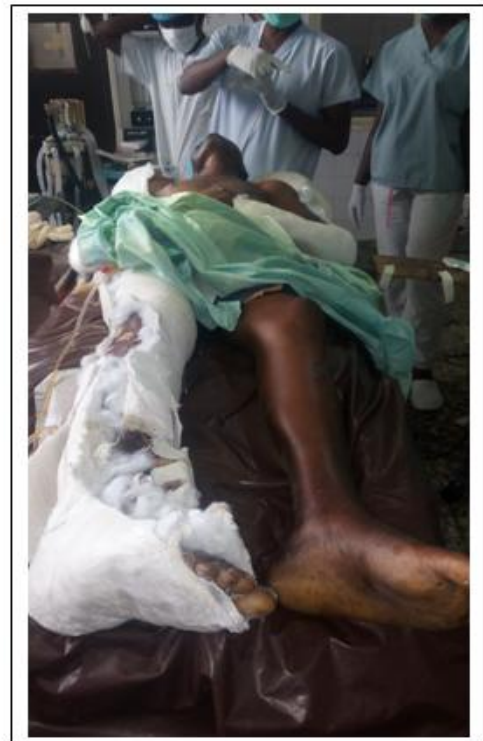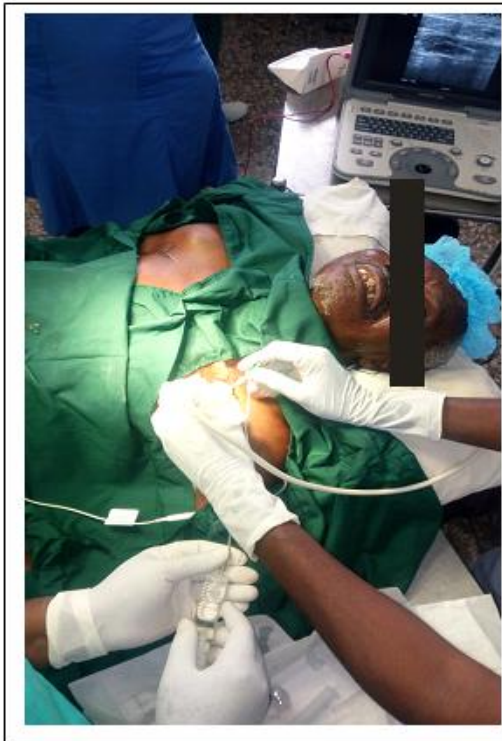A poly-traumatized elderly patient scheduled for surgical manipulations posed some challenges regarding the anaesthetic procedures and techniques to be used. Careful and informed selection of combination of dual-guided bilateral infraclavicular blocks and a subarachnoid block with good monitoring produced a successful anaesthetic and surgical outcome.

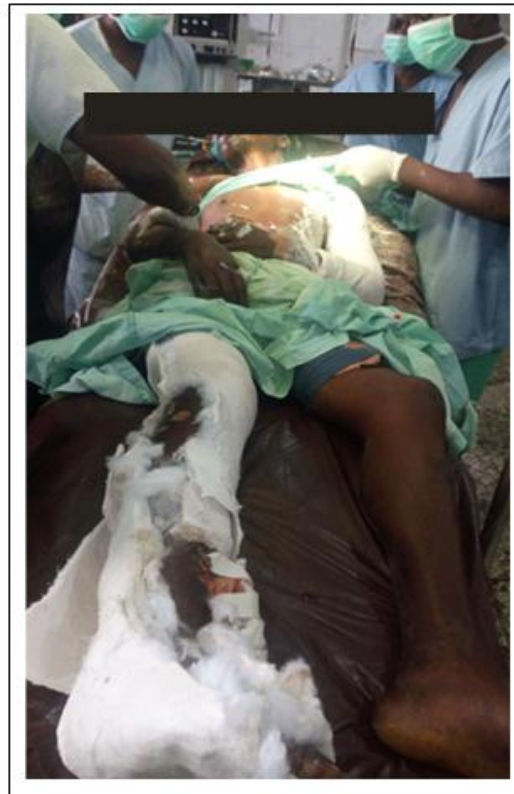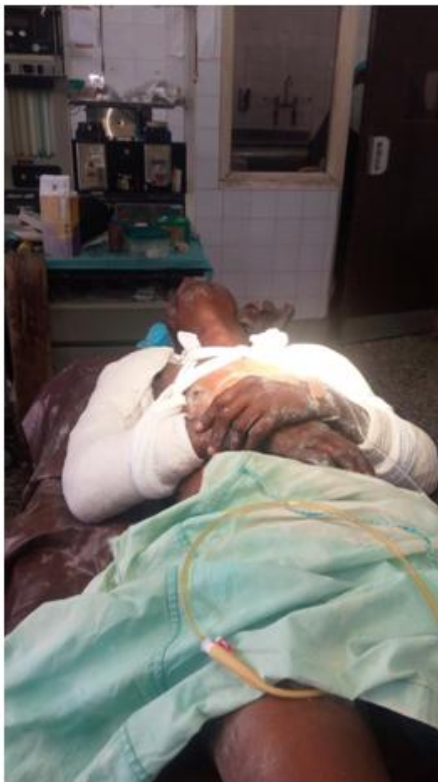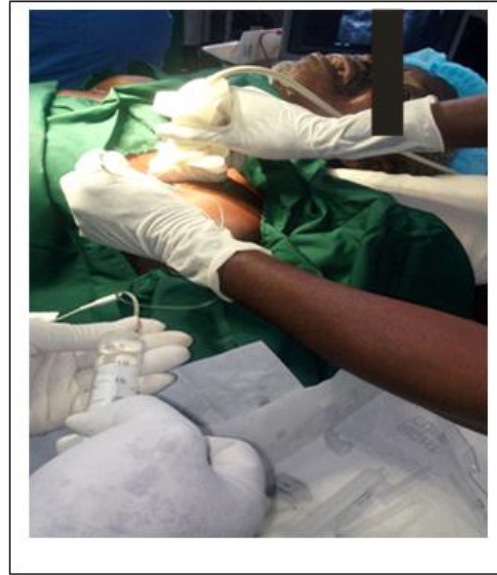
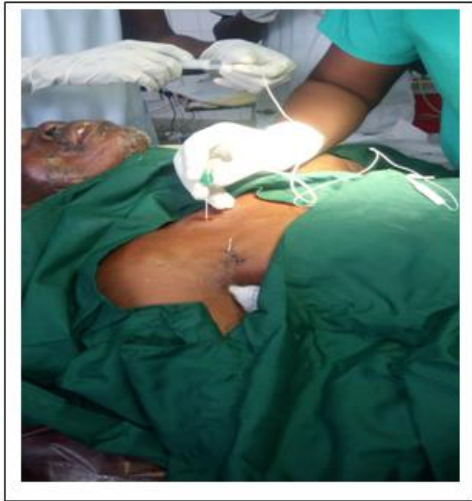#### DECLARATION OF INTERESTS

The authors declare no competing interests.

#### References

- [1]. Thanni LOA and Kehinde OA. Trauma at Nigerian Teaching hospital: pattern and documentation of presentation. *AfrHealth Sci.* 2006; 6(2): 104-107
- [2]. Paqueron X, Boccara G, Bendahou M, Coriat P, Riou B. Brachial Plexus Nerve Block Exhibits Prolonged Duration in the Elderly. *Anesthesiology* 2002; 97:1245–1249
- [3]. Franco C.D, Salahuddin Z, and Rafizad A. Bilateral Brachial Plexus Block. *Anesth Analg* 2004; 98:518 –520
- [4]. Rasmussen LS. Postoperative cognitive dysfunction: incidence and prevention. *Baillieres Best Practice & Research in Clinical Anaesthesiology* 2006; 20: 315–330.
- [5]. Chiang E.P, Dangerfield P, Mehta J.P, Sherman M, Berger J.S. The Crucial Role of Bilateral Infraclavicular Nerve Blocks in the Anesthetic Management of a Trauma Patient. *Open Journal of Anesthesiology*: 2012; 2: 113-116
- [6]. BhatPai RV, Hegde HV, Santhosh M, Roopa S, Deshpande SS, Rao PR. Bilateral brachial plexus blocks in a patient of hypertrophic obstructive cardiomyopathy with hypertensive crisis. *Indian J Anaesth* 2013; 57:72-75
- [7]. Vásquez MI, et al. Bloqueo supraclavicular bilateral con ecografía. *Rev Colomb Anestesiología*. 2012; 40:304–308.
- [8]. Sandhu N.S, Maharlouei B, Patel B, Erkulwater E, Medabalmi P. Simultaneous Bilateral Infraclavicular Brachial Plexus Blocks with Low-dose Lidocaine Using Ultrasound Guidance. *Anesthesiology*. 2006; 104(1):199-201
- [9]. Tekin M, Gürkan Y, Ceylan D.B, Solak M, Toker K. Ultrasound-guided bilateral infraclavicular block: case report. *AGRI* 2010; 22(1):41-43
- [10]. Purtuloğlu T, Şenkal S, Kılıçkaya O, Sızlan A, Kurt E. Ultrasound-Guided Bilateral Infraclavicular Brachial Plexus Blockade for Bilateral Distal Radius Fracture Surgery: Case Report. *J Clin Anal Med* 2015; 6(4): 516-518.
- [11]. Maurer K, EkatoDRAMIS G, Hodler J, Rentsch K, Perschak H, Borgeat A. Bilateral continuous interscalene block of brachial plexus for analgesia after bilateral shoulder arthroplasty. *Anesthesiology*. 2002; 96:762–764





Fatungase OM "Bilateral Infraclavicular Brachial Plexus Block with Subarachnoid Block for Anaesthesia in an Elderly Poly-Traumatized Patient –Case Report."IOSR Journal of Dental and Medical Sciences (IOSR-JDMS), vol. 17, no. 1, 2018, pp. 27-31