

A Rare Primary Tumor of Ischioanal Fossa: Surgical Technique & Review of Literature

Dr Hemendra Kumar¹, Dr Anil Heroor², Dr Arul Vanan³, Dr Yadukrishna⁴

¹(colorectal surgery, fortis hospital, Mumbai; India)

²(onco-surgery, fortis hospital, Mumbai; India)

³(laparoscopic surgery, fortis hospital, Mumbai; India)

⁴(MRCs, fortis hospital, Mumbai, India)

Corresponding author: Dr Hemendra Kumar

Abstract: Primary tumors of the ischioanal fossa are rare. They can be congenital, acquired or neoplastic. Accurate diagnosis often cannot be done preoperatively and imaging studies such as computed tomography and especially magnetic resonance imaging can define the size and anatomical relationships of the lesions. Surgical treatment is challenging because of difficult access of the region which is preferably performed by posterior approach. A 47-year-old female presented with localized swelling and palpable mass on left gluteal area. On per-vagina & per-rectal examination mass felt on left lateral wall & mucosa is not involved. pap smear was negative to malignancy. Patient underwent excision of mass with frozen & primary closure. Neoplasms occurring in the IRF must be treated taking into account the anatomy of the region. The preferable route of access is posterior, and may require partial resection of the sacrum. The definitive diagnosis can only happen with complete resection of the tumor and its subsequent pathological study.

Rarity of this disease and challenging case of surgery due to difficult access of the region prompted us to report this case & review of literature.

Key word: ischioanal fossa (IRF), Primary Tumor, Spindle Cell Tumor

Date of Submission: 15-01-2018

Date of acceptance: 31-01-2018

I. Introduction

Primary tumors of the ischioanal fossa are rare. They can be congenital, and developmental lesions; inflammatory, traumatic, and hemorrhagic conditions; primary tumors; and pathologic processes outside the ischioanal fossa with secondary involvement acquired or neoplastic. Accurate diagnosis often cannot be done preoperatively and imaging studies such as computed tomography and especially magnetic resonance imaging can define the size and anatomical relationships of the lesions. Surgical treatment is challenging because of difficult access of the region which is preferably performed by posterior approach.

II. Case Report

A 47-year-old female presented with localized swelling and palpable mass on left gluteal area. On per-vagina & per-rectal examination mass felt on left lateral wall & mucosa is not involved. pap smear was negative to malignancy. MRI Perineum(Plain + Contrast) suggest a 6.1× 8.0× 4.4 cm a large well defined lobulated enhancing neoplastic mass lesion of spindle cell origin in left perineal region, involving the left ischioanal & ischioanal fossa mass abuts the urethra, vagina & anal canal (fig 1). Patient underwent excision of mass through posterior approach (fig 2) with frozen & primary closure. On histopathology, macroscopically a mass measuring 7.5x5.5x4.5cm (fig 3). External surface is smooth and bosselated. Microscopically shows Cell are arranged in interlacing fascicles. Individual cells show oval & spindle cell. Focal areas of severe nuclear pleomorphism seen. Areas of cystic degeneration and necrosis seen. Impression Spindle cell neoplasm, of smooth muscle origin.

Post surgery day 2 anal tone was normal on per rectal examination. No complain of incontinence. Pt is under regular follow up.

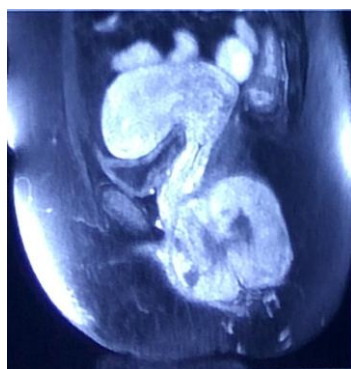


Fig.1

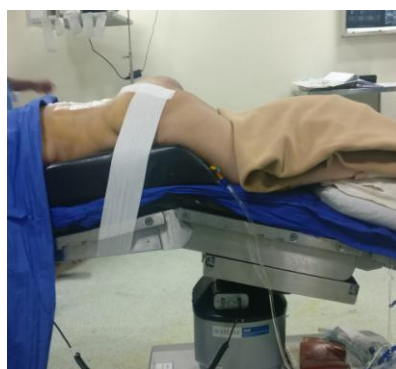

Fig.2

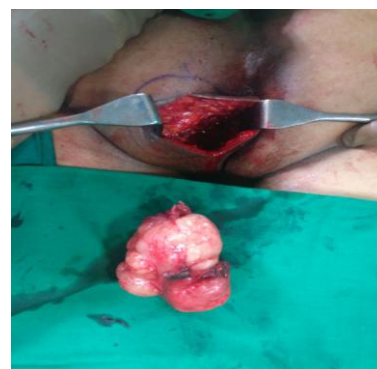

Fig.3

III. Discussion, surgical technique & Literature reviews

The ischiorectal fossa (IRF) is the largest space of the anorectal region. It has a pyramidal shape and both communicate posteriorly through the post anal deep space, between the levator ani and the anococcygeus ligament¹. The IRF contains adipose tissue, nerves, vessels and lymph from the vessels and the pudendal nerves. The IRF relates medially with the rectum, the levator ani and the external anal sphincter, anteriorly with the superficial and deep transverse perineal muscle, lateral margin, the obturator internus, inferiorly by the perineal skin, & Cranially the levator ani separate IRF of the supralelevator space (fig 4).

Primary neoplasms of the ischiorectal fossa (IRF) are uncommon and tumors of this region usually result from invasion of adjacent tumors as prostate, anus, rectum, or pelvic bone tumors. Imaging studies such as computed tomography (CT) and magnetic resonance imaging (MRI) can evaluate the size, location and relationship of the tumor and adjacent structures, but not always is possible to suggest precisely the nature of the lesion.²

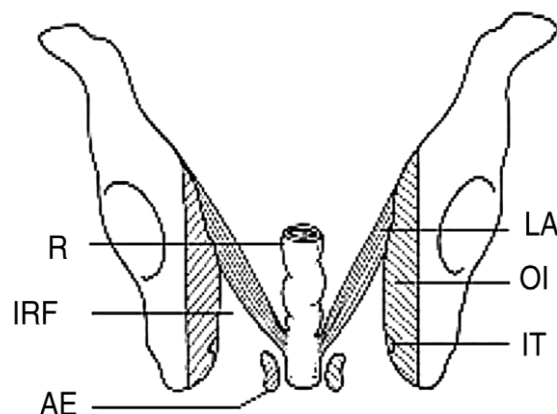


Fig 4. R, rectum; IRF, ischiorectal fossa; AE, anal sphincter; LA, levator ani muscle; OI, obturator internus muscle; IT, ischial tuberosity.

Solitary fibrous tumors (SFT) are rare mesenchymal neoplasms in adults. There is little literature on the SFT and only one report of involvement of the IRF². The importance of recognizing these tumors should be in its differentiation from more aggressive tumors as liposarcomas^{3,4}. Lipomas on CT appear as lesions with signal similar to subcutaneous tissue. Large Septated tumors are indistinguishable from low grade liposarcomas.

DIFFERENTIAL DIAGNOSIS	
CONGENITAL TUMORS	
•	Gardner's duct cysts ,
•	Giant epidermal cyst ,
•	Tailgut cyst
INFLAMMATORY, TRAUMATIC, AND HEMORRHAGIC LESIONS	
•	Fistula in ano ,
•	Extraperitoneal Pelvic Hematoma ,
•	Rectal perforations,
•	surgical procedures,
•	spread from an adjacent cutaneous infection,
•	trauma
NEOPLASMS	
PRIMARY	
•	Aggressive Angiomyxoma ,
•	Lipoma, Plexiform Neurofibroma ,
•	Anal Adenocarcinoma,
•	Squamous Cell Carcinoma,
•	spindal cell tumor
SECONDARY	
•	Prostatic Tumor,
•	Rectal Tumor ,
•	Perineal Hemangiopericytoma ,
•	Bone Tumor

Aggressive angiomyxoma occurs most commonly in young women, affecting soft tissues such as the pelvis, perineum, buttocks, vulva, retroperitoneum and inguinal regions⁵. Secondary involvement of the IRF is common. On CT there is a hypo or iso attenuating sign. They have a gelatinous appearance and are locally invasive. Trichilemmal proliferative tumor (TPT) is a tumor that develops from the outer sheath cells or follicular usually after trauma or inflammation^{3, 6}. This tumor has a slow evolution and occurs in 90% of the time on the scalp, more rarely other sites have been reported (trunk, face, pubic area, vulva). They can be large and malignant transformation is rare^{5,7}. The immunohistochemical study is an aid to diagnosis of malignancy of TPT and the differential diagnosis must be done with Squamous cell carcinoma. CD34, a marker of differentiation of hair is weakly positive in malignant TPT and negative in Squamous cell carcinoma. Malignant histiocytoma can also occur in the IRF and depend on location can be accessed by other routes of as vaginal access. Immunohistochemistry demonstrates that tumor cells are positive for vimentin and negative for cytokeratin, desmin, protein S-100, lobes, c-kit and CD34⁸. Adjuvant treatment with radiotherapy may be necessary⁹.

Spindle-cell sarcomas comprise a group of soft tissue sarcomas that are characterised by the microscopic appearance of spindle-shaped neoplastic cells¹⁰. Radiological investigations may provide a clue to the lineage of the sarcoma and are essential for surgical planning and staging. MRIs are currently the modality of choice for investigation of sarcomas. Due to the rarity and heterogeneous nature of spindle-cell sarcomas, the histological diagnosis of such neoplasms remains a challenge despite advancements in cancer cytogenetic and Immunohistochemistry

The resection of tumors of the IRF is particularly challenging because of the difficulty in accessing through an anterior approach. A posterior approach combined or not with an anterior access is used. Operative technique: "jack knife" or prone position, stretch of buttocks: (1) vertical para-sacral incision and dissection from the subcutaneous tissue to the level of the gluteal muscles (2) identification of the bottom edge of the tumor and the ischial tuberosity, section of the sacrotuberous ligament and release of the tumor from the gluteus maximus or its resection if there is invasion of the muscle; (3) if necessary the lower part of sacrum can be resected but only below S3 level to preserve the root of pudendal nerve; (4) medial and cranial dissection with release of the rectum the anal sphincter and the levator ani from the tumor; (5) closing the wound by plans or sphincter reconstruction and drainage of the region with drain.

Surgical resection remains the mainstay of treatment for soft tissue sarcomas and wide resections with clear margins are the gold standard. Comparatively, surgical resections with positive margins have been shown to increase the risk of local recurrence, metastases, and mortality. A R0 resection is the key to avoid local recurrences, and this is of special interest in malignant tumours or locally aggressive tumours. In addition, the treatment of sarcomas requires utilisation of neoadjuvant and adjuvant therapies for optimal outcomes.

References

- [1]. Miller M, Kulaylat MN, Ferrario T, Karakousis CP. Resection of tumors of the ischiorectal fossa. *J Am Coll Surg.* 2003;196:328–32.
- [2]. Llauger J, Palmer J, Pérez C, Monill J, Ribé J, Moreno A. Normal and pathologic ischiorectal fossa at CT and MR imaging. *Radiographics.* 1998;18:61–82.
- [3]. Satheshkumar T, Saklani AP, Banerjee D, Jones DR. Angiomyofibrosarcoma: a rare ischiorectal fossa swelling. *Hosp Med.* 2003;64:244–5
- [4]. Teoh KH. Malignant peripheral nerve sheath tumour in the ischiorectal fossa. *Colorectal Disease.* 2009;11:533.
- [5]. Ng SSM, Hon SSF, Wong JHM, Lee JFY. Radiology for the surgeon. Soft-tissue case 59. *Can J Surg.* 2006;49:435–6.
- [6]. Yap T, Hamzah L, Oshowo A, Taylor I. Myxoid solitary fibrous tumour of the ischiorectal fossa. *Eur J Surg Oncol.* 2003;29:98–100.
- [7]. Satheshkumar T, Saklani AP, Banerjee D, Jones DR. Angiomyofibrosarcoma: a rare ischiorectal fossa swelling. *Hosp Med.* 2003;64:244–5.
- [8]. Teoh KH. Malignant peripheral nerve sheath tumour in the ischio-rectal fossa. *Colorectal Disease.* 2009;11:533.
- [9]. Makhlof Z, Verola O, Senejoux A, Duval A, Terris B, Balaton A, et al. Tumeur trichilemmale proliférante de la région ischio-rectale. *Ann Pathol.* 2011;31:316–9.
- [10]. Nystrom LM, Reimer NB, Reith JD, Dang L, Zlotecki RA, Scarborough MT, et al. Multidisciplinary management of soft tissue sarcoma. *ScientificWorldJournal* 2013 doi:10.1155/2013/852462.

Dr Hemendra Kumar "A Rare Primary Tumor of Ischiorectal Fossa: Surgical Technique & Review of Literature" *IOSR Journal of Dental and Medical Sciences (IOSR-JDMS)*, vol. 17, no. 1, 2018, pp. 26-29.