

## Torsion of Gravid Horn of Bicornuate Uterus in 3<sup>rd</sup> Trimester – A Case Report

\*<sup>1</sup>Bivarani Goswami, <sup>2</sup>Himleena Gautam

Department of Obstetrics & Gynaecology, Gauhati Medical College & Hospital, India  
Corresponding Author: Himleena Gautam

---

**Abstract:** Uterine torsion is defined as a rotation of more than 45 degrees around the long axis of the uterus. It is an uncommon but potentially life threatening condition. The non-specific clinical course and rarity of this condition makes the diagnosis difficult preoperatively and causes difficulty in effecient management. We present here a case of uterine torsion that presented as 23year old primipara with pain abdomen at 31 weeks with IUFD. When induction of labour failed and patient started developing sepsis, caesarean section was planned which revealed 180degree torsion of gravid right sided horn of bicornuate uterus. Excision of that horn was done following delivery of fetus by posterior wall incision.

**Keywords:** bicornuate uterus, posterior wall incision, uterine torsion

---

Date of Submission: 12 -09-2017

Date of acceptance: 023-09-2017

---

### I. Introduction

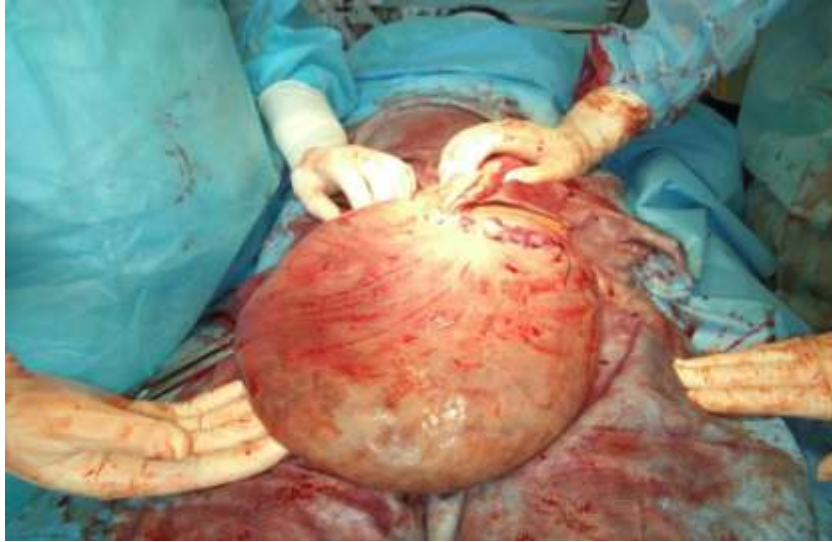
Rotation of the gravid uterus is a common physiological finding and in more than 2/3 cases, it occurs toward right i.e. dextrorotation.[1,2,3] Rotation of the uterus beyond 45degree is pathological uterine torsion and is extremely rare. It is almost always diagnosed during a laparotomy.[4] It was first reported by *Labbe* in 1876[5,6]. Until 1992, only 212 cases have been reported[2]. Wilson et al reported 38 cases in 2006.[7]When the uterus rotates on itself,uterine venous obstruction occurs which causes increased pressure in placental cotyledons leading to abruption and fetal distress. Further obstruction to placental perfusion leads to fetal demise.In this case report we present a case in which the woman in preterm gestation had 180degree torsion of gravid horn of bicornuate uterus which is thought to be the cause of intrauterine fetal demise.

### II. Case report

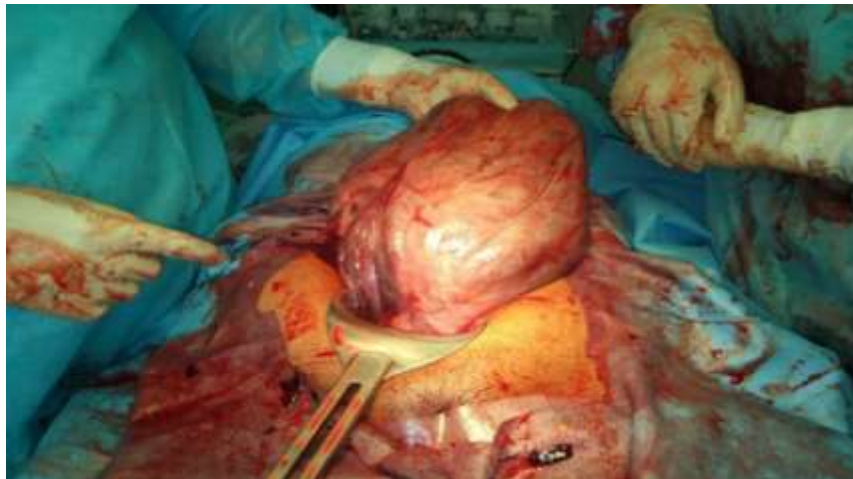A 23 year old primipara, with one previous abortion, was admitted in emergency labour room at Gauhati Medical College and Hospital, Guwahati, Assam, at 31 weeks gestation with complaints of pain abdomen and loss of fetal movements for 4 days. 4 days prior to admission there was sudden severe pain in lower abdomen, non radiating in nature, for about 1 hour following which she complained of loss of fetal movement. There was no history of trauma or fall. The sudden severe pain was followed by a constant dull and diffuse pain over whole abdomen. She was then taken to a nearby private nursing home(Goalpara) where the diagnosis of IUFD with anterior low lying placenta was made. She was tried induction of labour with misoprostol 25ug(2 doses) but it failed. She also received 3units of PRBC due to anemia, and was referred to GMCH later.On examination, pallor and edema were present. Pulse rate was 124/min, BP was 100/70mmHg and respiratory rate was 35/min. She had an indwelling urinary catheter. Abdomen was distended with fundal height of 32weeks. On P/V examination os was closed and cervix long, posterior.

On investigations, Hb was 8.8gm/dl, s.creat was 1.9mg/dl, PT 16.3secs and APTT 44.6secs. USG showed single IUD fetus of 32 weeks of gestation, type 2anterior placenta previa, bilateral hydroureteronephrosis with early renal parenchymal changes and ascitis.Party counseling was done and patient started on broad spectrum injectable antibiotics in consultation with Medicine & Nephrology Department. Intermittent O2 inhalation and furosemide 40mgIV also given. On stabilization she was prepared for laparotomy.Intraopratively ascitic fluid with extensive flimsy adhesions seen. Incision given over the posterior wall of uterus (Fig.1), as uterus was twisted 180degree and a macerated baby was delivered. Placenta was already separated and uterine cavity was filled with about1.5L altered foul smelling blood. Uterus was flabby and highly infected. It was found to be a bicornuate uterus with torsion of the gravid right horn with right sided tubes and ovaries lying on the left side. Uterine detorsion was done (Fig.2) and subsequently excision of the right horn was done after taking proper consent. Fig.3 shows the left horn.She received post operative care in ICU where she was on mechanical ventilation for 2days following which she recovered and was shifted to general ward on 7<sup>th</sup> postoperative day. Her wound was healthy and was discharged on 12<sup>th</sup> day.

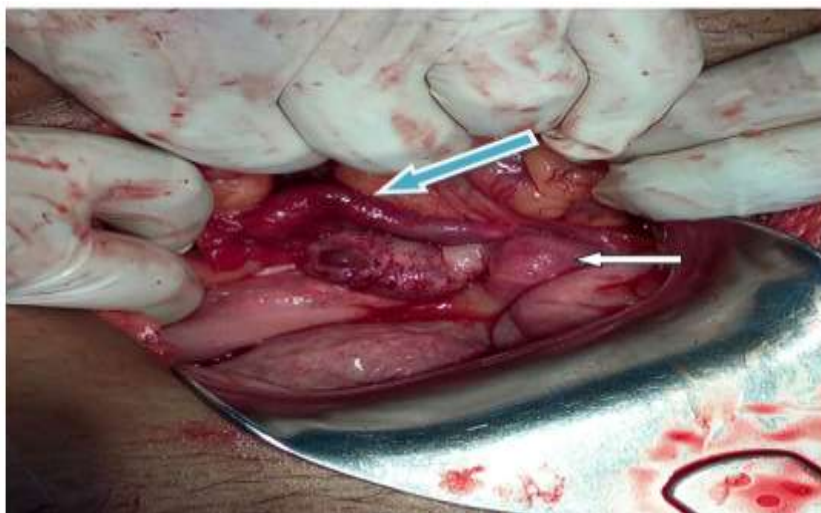
**III. Figures**



**Fig 1 :** incision on the posterior wall of lower uterine segment. Uterus is flabby.



**Fig 2:** detorsion done. Ecchymosed right sided round ligament, fallopian tube and ovarian ligament due to torsion.



**Fig 3 :** left horn of the bicornuate uterus(white arrow) with left sided edematous tube and ovary(blue arrow). right horn removed.

#### IV. Discussion

Uterine torsion is defined as rotation of the uterus of more than 45 degrees on its long axis.[3] It can range from 60–720 degrees.[2,8] This condition can occur in all age groups, all parity and all stages of pregnancy.[2] Etiology is still unclear, although several conditions are associated with it, which includes fetal malpresentations, uterine myoma, uterine malformations, adhesions and adnexal mass. According to Piot et al. [1]31.8% had uterine fibroid, 14.9% uterine anomalies especially bicornuate uterus, 8.4% had pelvic adhesions, 7% had ovarian cysts, 4.6% had abnormal presentation and fetal anomalies, 2.8% abnormalities of spine and pelvis and no causes in the rest of the cases. Salani et al. [9] reported a case where ECV (external cephalic version) caused uterine torsion. Duplantier et al. [10] reported a case of torsion due to maternal trauma. Achanna et al. [11] have reported a case of torsion in uterus didelphys due to abdominal massage during labor by traditional birth attendants. Chundawat et al. [12] also reported a case similar to this report. Robinson and Duvall proposed that certain maternal irregular body movements or posture and positions may help trigger the rotation of uterus with pre existing structural pathology. They found intrinsic pathology is found in 66% cases.[13]

The mechanism of torsion can be explained by structural weakness (developmental or acquired) and angulation in the isthmic region leading to torsion. Most cases present with non specific symptoms, mostly acute abdominal pain and tenderness and diagnosed only at laparotomy. They may present with birth obstruction, vaginal bleeding, abnormal FHR, shock, urinary and intestinal symptoms[14]. In 11% cases it may be asymptomatic.[2] High degree of suspicion is needed to diagnose this condition antenatally. Modification of placental site compared to previous ultrasonography and abnormal position of uterine vessels across uterus on doppler can help in the diagnosis of torsion.[15] An X shaped configuration of the vagina on MRI compared to normal H shaped structure also helps in the diagnosis.[16] This is based upon the fact that vagina is normally seen on MRI as an H-shaped structure, but with torsion of the uterus and upper vagina, the vagina appears as an X shaped structure.

Management comprises an emergency laparotomy and detorsion of the uterus followed by anterior transverse incision. If detorsion is not possible, delivery of the foetus through a posterior low transverse incision is recommended followed by correction of torsion.[4] This should be followed by an elective cesarean section in the consecutive pregnancy as risk of rupture is not known.[3] There are reports of myomectomy and posterior vertical section in some cases[17]. It is important to delineate proper anatomy to prevent injury to major vessels and organs. The routine practice of palpating the round ligaments at the time of caesarean section helps in giving incision at the proper site. In mid trimester uterus can be derotated and pelvic pathology causing torsion like myoma or ovarian cyst be removed. To prevent recurrent torsion some have suggested plication of round ligament [18]. Plication of uterosacrals to prevent recurrent torsion has also been done.[19] There are no reports of maternal death after 1960.[15] Perinatal mortality is around 18%. [3]

#### V. Conclusion

Uterine torsion should be a differential diagnosis in cases presenting with acute abdomen in pregnancy, specially in 3<sup>rd</sup> trimester. There should be high degree of suspicion specially in cases with myoma and Mullerian anomaly. Management is detorsion of the uterus with delivery of the fetus by LSCS. If posterior segment incision given, then elective caesarean section is to be done in next pregnancy. If torsion occurs in bicornuate uterus, the horn can be incised and repaired or excised, whatever is necessary.

#### References

- [1]. D. Piot, M. Gluck, and H. Oxorn, "Torsion of gravid uterus," *The Canadian Medical Association Journal*, vol. 109, no. 10, pp. 1010–1011, 1973.
- [2]. J.G. Jensen, "Uterine torsion in pregnancy," *Acta Obstetrica et Gynecologica Scandinavica*, May, vol. 71, pp. 260–265, 1992.
- [3]. D. Wilson, A. Mahalingham, and S. Ross, "Third trimester uterine torsion: case report," *Journal of Obstetrics and Gynaecology Canada*, vol. 28, no. 6, pp. 531–535, 2006.
- [4]. Albayrak M, Benian A, Ozdemir I, Demiraran Y, Guralp O. Deliberate posterior low transverse incision at caesarean section of a gravid uterus in 180 degrees of torsion: a case report. *J Reprod Med* 2011 Mar-Apr;56(3-4):181-3
- [5]. Jovanovic D, Del Granado A, Stiller A. Torsion of the gravid uterus: a review and a case. *J Reprod Med* 1972; 8(2):81–4.
- [6]. Biswas MK, Summers P, Schultis SA, Herrera EH, Pernoll ML. Torsion of the gravid uterus. A report of two cases. *J Reprod Med* 1990;35(2):194–7.
- [7]. Wilson D et al. Third trimester Uterine torsion. *J Obstet Gynaecol Can*. 2006; 28(6):531-35.
- [8]. Sparic R, Perulov M, Stefanovic A, et al. [Uterine Torsion in term Pregnancy]. *Srp Arh Celok Lek* 2007 Sep-Oct;135(9-10):572-5
- [9]. R. Salani, R. N. Theiler, and M. Lindsay, "Uterine torsion and fetal bradycardia associated with external cephalic version," *Obstetrics and Gynecology*, vol. 108, no. 3, pp. 820–822, sep 2006.
- [10]. N. Duplantier, W. Begnaud, R. Wood, and C. Dabezies, "Torsion of a gravid uterus associated with maternal trauma: a case report," *Journal of Reproductive Medicine for the Obstetrician and Gynecologist*, vol. 47, no. 8, pp. 683–685, 2002.
- [11]. S. Achanna, D. Monga, and M. Suhaimi Hassan, "Case report: torsion of a gravid horn of didelphic uterus," *Journal of Obstetrics and Gynaecology Research*, vol. 22, no. 2, pp. 107–109, 1996.
- [12]. Chundawat RS et al. *Int J Reprod Contracept Obstet Gynecol*. 2016 Jul;5(7):2428-2430
- [13]. Robinson AL, Duvall HM. Torsion of the pregnant uterus. *J Obstet Gynaec Br Commonw* 1931;38:55-84.

- [14]. Dua A, Fishwick K, Deverashetty B. Uterine Torsion in Pregnancy: A Review. *The Internet Journal of Gynecology and Obstetrics* 2006;6(1).
- [15]. Guié P, Adjobi R, N'guessan E, Anongba S, Kouakou F, Boua N, et al. Uterine torsion with maternal death: our experience and literature review. *Clin Exp Obstet Gynecol* 2005;32:245-6
- [16]. Nicholson WK, Coulson CC, McCoy MC, Semelka RC. Pelvic magnetic resonance imaging in the evaluation of uterine torsion.. *Obstet Gynecol* 1995;85:888-90.
- [17]. I. I. Bolaji, N. M. Rafla, and M. J. Mylotte, "Classical caesarean section through the posterior uterine wall," *The Irish Journal of Medical Science*, vol. 161, no. 2, pp. 46–47, 1992.
- [18]. M. A. Pelosi III and M. A. Pelosi, "Managing extreme uterine torsion at term: a case report," *Journal of Reproductive Medicine for the Obstetrician and Gynecologist*, vol. 43, no. 2, pp. 153–157, 1998
- [19]. M. S. Mustafa, F. Shakeel, and B. Sporrang, "Extreme torsion of the pregnant uterus," *Australian and New Zealand Journal of Obstetrics and Gynaecology*, vol. 39, no. 3, pp. 360–363, 1999.