

Cutaneous Horn Over Volar Aspect of Little Finger In A Female- A Case Report Running title

Cutaneous Horn Over Volar Aspect of Little Finger In A Female

¹S.M.Kale(M.S., M.Ch.), ²Surendra B.Patil (M.S., M.Ch.),
^{3*}Shree Harsh (M.S., M.Ch.), ⁴Rahul Nikam (M.B.B.S., M.S.) ,
⁵Dr R.C.Parate (M.B.B.S., M.D.)

1.Ex Professor, Department of Plastic and Maxillofacial Surgery, Government Medical College and Hospital, Nagpur.

2.Associate Professor and Head,, Department of Plastic and Maxillofacial Surgery, Government Medical College and Hospital, Nagpur

3.Senior Resident, Department of Plastic and Maxillofacial Surgery, Government Medical College and Hospital, Nagpur.

4.Senior Resident, Department of Plastic and Maxillofacial Surgery, Government Medical College and Hospital, Nagpur.

5.Ex Professor, Department of Pathology, Government Medical College and Hospital, Nagpur ,
Corrospoding author: *Shree Harsh (M.S., M.Ch.)

Abstract: Cutaneous horns are uncommon protruding lesions from the skin which look like an Animal horn in a small form. They are usually found in sun exposed areas of the body, though cases have been reported of their occurrence in non sun exposed areas as well. We report a case of cutaneous horn on volar aspect of right little finger which to the best of our knowledge is the first reported such case in a female.

Keywords: sebaceous, horn, volar, finger, female

Date of Submission: 01 -09-2017

Date of acceptance: 22-09-2017

I. Background

Cutaneous horn (cornu cutatum) are uncommon skin tumors composed of compacted keratin. They may arise from benign, premalignant and Malignant epidermal lesions. The first reported case was of a Welsh woman in London in 1588. The usual sites of occurrence are the chronically exposed sun damaged areas of the body like exposed areas of the head, dorsal part of hand and forearm. They may also be found on the shoulder, penis, chest and neck¹. It may have a benign or malignant base. Though their occurrence on the volar aspect of fingers have been reported, they are very rare. We report a case of cutaneous horn of the volar aspect of the middle phalynx of right little finger in a young female.

II. Materials And Methods

A 30 year old female patient presented with a growth in the right little finger for 5 years. The swelling gradually increased in size and was not associated with pain or discharge. There was no history of Surgery or trauma to the site. There was no history of similar growth in any family member. There was no history of erythema or swelling at the base of the lesion. Examination revealed a 1.5 x0.5 cm cutaneous horn on volar aspect of middle phalynx of right little finger. It was light brown in colour with a curved conical tip.(Figure 1) Patient was posted for Surgery after routine investigations. Excision of the cutaneous horn was done after ring block along with a margin of 1 millimetre. Specimen was sent for histopathology. Patient was discharged on the day of Surgery. Histopathology was suggestive of sebaceous (cutaneous) horn (Figure 2and 3). Sutures were removed on day 10. (Figure 4)

III. Discussion

Cutaneous horns presents as conical, cylindrical, pointed projections or like horn of animals and vary in dimensions from few millimetres to 25 centimeters. About 30% are found in scalp and face². Their exact etiology is unknown³. They may be associated with keratosis, molluscum contagiosum, bowen's disease, epidermoid carcinoma, malignant melanoma and basal cell carcinoma⁴. They arise most commonly from a seborrheic keratosis lesion¹. More than 60% of the lesions are benign⁵. Cutaneous horns are known to grow for years if left alone. Tenderness, inflammation and infiltration at the base of the horn are signs of malignancy which is more likely to occur in elderly, males, those located in sun exposed areas and those horns with a large base⁶. Height is less than the base in invasive squamous cell carcinomas⁷. They arise from benign lesions in 61.1% of cases, premalignant lesions in 23.2% of cases and malignant lesions in 15.7% of cases⁸. 94% of the lesions with malignant base have squamous cell carcinoma⁷. Benign base may be present in 41 to 60% of the cases⁷. Horns may be single or multiple. The pathologic process responsible for the growth of the horn resides in its base⁸.

Histopathological examination shows hyperkeratosis with parakeratosis. Patients can be treated with simple excision or cauterisation. As these lesion may have premalignant and malignant changes, early excisional biopsy is recommended with histopathological examination to rule out malignancy. Cutaneous horn on volar aspect of hand is very rare. A case of the same was reported in a 45 year male on volar aspect of middle finger⁸. Histopathology of the lesion showed Actinic Keratosis. Another such case has been reported in a 25 year old male with a 2.5x0.5 cm lesion on the tip of index finger. Histopathology revealed hyperkeratosis and parakeratosis⁹. To the best of our knowledge, this is the 1st reported case of a Cutaneous horn in a young female over volar aspect of little finger.

IV. Conclusion

Cutaneous horns are lesions presenting more in the areas of the body exposed to sun. Their occurrence in areas not exposed to sun have been reported. Early diagnosis and excision followed by histopathological examination should be the goal of treatment to identify malignant changes at the earliest, if any. Cutaneous horn over volar aspect of little finger in a female is very rare and is being reported for the very first time to the best of our knowledge.

References

- [1]. Sanjay Saraf. Sebaceous horn: An interesting case. Indian Journal of Dermatology 2007; Volume 52: Issue 1, Pg 59-60
 - [2]. Priyanka Singhal, Rahul Dixit, Shivani Patel, Y.S.Marfatia. What is your diagnosis? Indian Journal Sex Transm Disease 2010, July-Dec;31(2):130-131
 - [3]. Rekha A, Ravi A. Cornu Cutaneum- cutaneous horn on the penis. Indian J Surg 2004;66:296-7
 - [4]. Akan M, Yildirim S, Avici G, Akoz T. Xeoderma pigmentosum with a giant cutaneous horn. Ann Plast Surg 2001;46:665-666
 - [5]. Eray Copcu, Nazan Sivrioglu, Nil Culhaci. Cutaneous horns: are these lesions as innocent as they seem to be? World Journal of Surgical Oncology 2004;2:18 DOI: 10.1186/1477-7819-2-18
 - [6]. Acta Dermatoven, N. F.Fernandes, S.Sinha, W.C.Lambert, R.A.Schwartz. Letter to the editor. Cutaneous horn: a potentially malignant entity, APA Vol 18,2009, No 4
 - [7]. John Pyne, Devendra Sapkota, Jian Cheng Wong. Cutaneous horns: clues to invasive squamous cell carcinoma being present in the horn base. Dematol Pract Concept 2013 April;3(2):3-7
 - [8]. Pragya A Nair, Arvind H Chaudhary, Malay J Mehta. Actinic keratosis underlying cutaneous horn at unusual site- a case report. Ecancermedicalscience 2013 ;7:376. Doi:10.3332/ecancer.2013.376
 - [9]. Leo Francis Tauro, John Joseph S Martis, Sijo K John, Prem Kumar K. Cornu Cutaneum at an unusual site. Indian Journal of Plastic Surgery 2006; Vol39, Issue 1: pg 76-78
- Figure Legends
Figure 1- Pre operative photograph
Figure 2- Hyperkeratosis with pseudoepitheliomatous hyperplasia-4 x Hematoxyline and eosine
Figure 3- Hyperkeratosis with pseudoepitheliomatous hyperplasiawith dysplasia-10 x Hematoxyline and eosine
Figure 4- Post operative photograph

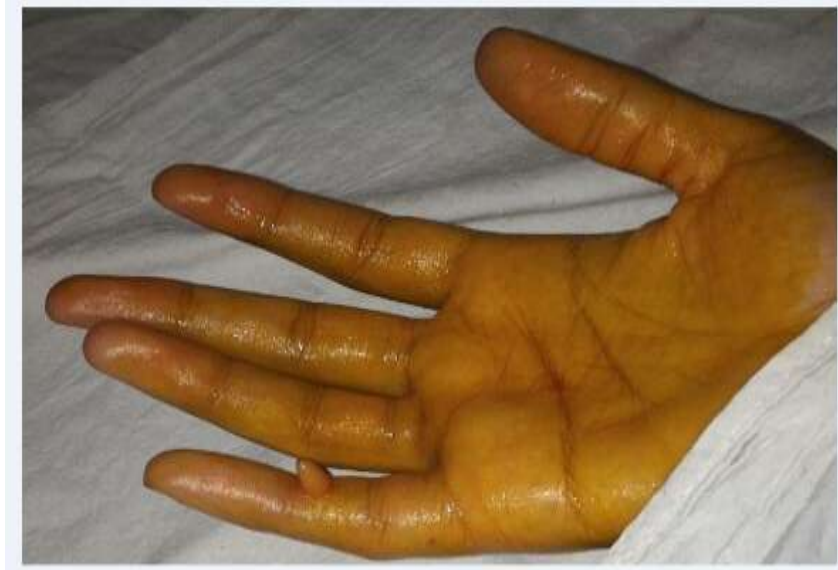

Figure 1

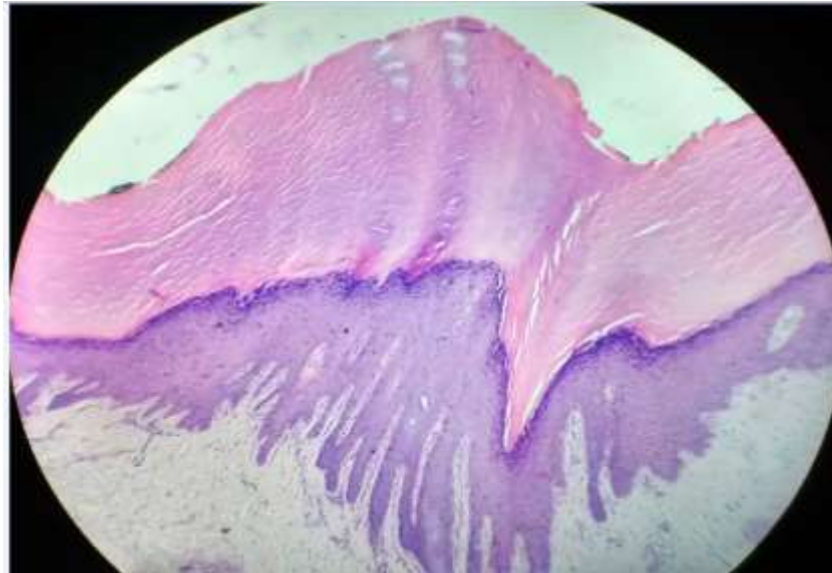


Figure 2

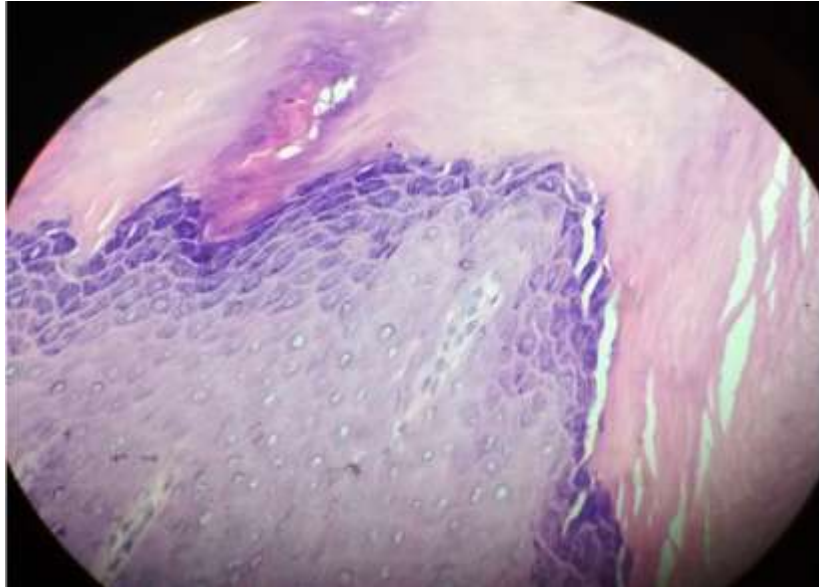


Figure 3

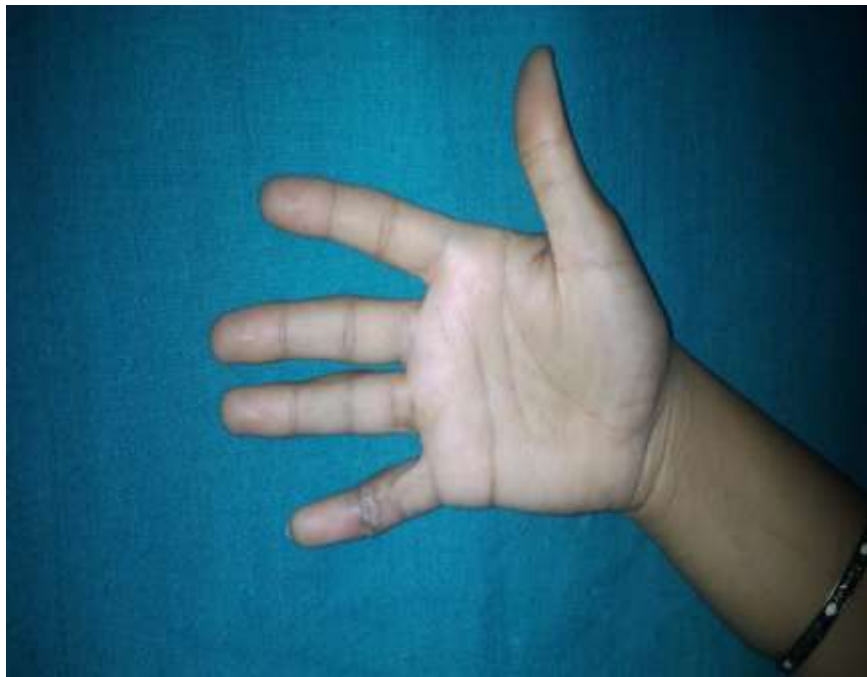

Figure 4

*S.M.Kale(M.S., Mch.). "Cutaneous Horn Over Volar Aspect of Little Finger In A Female- A Case Report Running ." IOSR Journal of Dental and Medical Sciences (IOSR-JDMS) , vol. 16, no. 09, 2017, pp. 94–97.