

## Malo' S Bridge An "All-on-4"/ Diem-2 Immediate Function Concept

\*Dr. Deepika Baniwal

Punjab Government Dental College and Hospital, Amritsar, Punjab.BDS, MDS.

Corresponding Author: \*Dr. Deepika Baniwal

---

**Abstract:** The Malo's clinical ceramic bridge is the most aesthetically advanced form of fixed prosthodontic rehabilitation for the fully edentulous patients. This prosthesis is the epitome of biomedical engineering combined with Computer aided design/ computer assisted machine CAD/CAM technology. The bridge is initially constructed as a removable occlusal screw retained superstructure on four titanium implants placed according to the All-on-4 concept. The approach is to rehabilitate the fully edentulous jaw by placing only four titanium implants in each jaw, 2 anterior implants placed axially and 2 posterior implants placed distally tilted within the mandibular parasymphiseal region in case of mandible, through a quick and minimally invasive procedure using All-on-4 surgical protocol. These implants were immediately loaded with a full fixed acrylic prosthesis within 2 hours of surgery and after 3-4 months when the healing and osseointegration phase has reached it is replaced by a bridge of more stronger and durable material. The implant acts as a foundation for Malo's bridge which allows for the placement for a fixed set of teeth, in all similar to natural teeth. The final result is a fixed (non-removable) natural looking dentition.

**Keywords:** Malo's bridge, Branemark system, All-on-4 implants, Marius bridge.

---

Date of Submission: 06 -09-2017

Date of acceptance: 20-09-2017

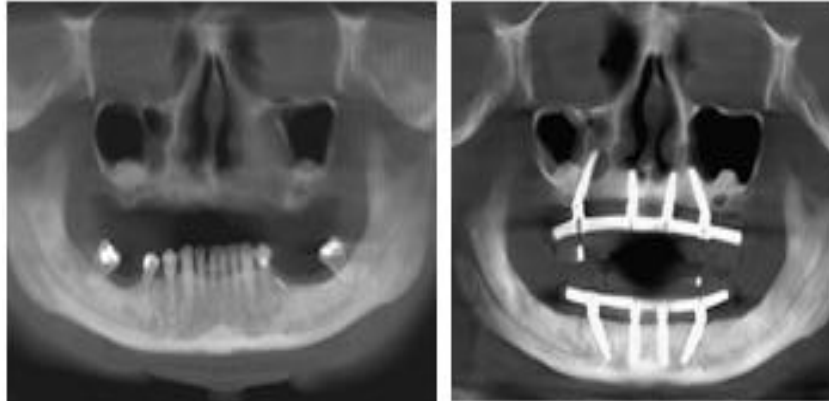
---

### I. Introduction

In 1993, Dr Paulo Malo (A Portuguese Dentist, President of Maloclinic Health and Wellness) performed the pilot study to establish All-on-4 concept. The design of the "All-on-4" immediate function concept (Malo implant bridge) with Branemark system implant was developed in 2003 by Malo and colleagues. In their study, the high cumulative implant and prostheses survival rates indicate that the "All-on-Four" immediate-function concept with Brånemark System implants used in completely edentulous mandibles is a viable concept (Malo et al., 2003). The "All-on-4" concept is based on the principle that four implants, a combination of two straight anterior and two tilted posterior, placed within the premaxilla (Malo et al., 2005) or anterior mandible, would provide enough support to maintain a full-arch fixed prosthesis (Babbush et al., 2011). All-on-4/"DIEM 2 concept" involves placing the four implants in both maxilla and the mandible and immediately loading them on the say day of the surgery. It has been developed to maximize the use of available bone and allows immediate function (Thumati et al., 2017). Many long term studies and published data on the all on four concept reported cumulative survival rates between 92.2% and 100% (Babbush et al., 2011). Tilted implants were suggested to be useful in the treatment of edentulous arches because they avoided the bone augmentation procedures, anatomical structures and in order to reduce cantilever length there by reducing the stress and providing better stress distribution (Cavalli et al., 2012).

(Graves et al., 2011) studied the use of tilted implants in maxilla using All-on 4 concept and found them as a predictable alternative to extensive bone grafting and sinus augmentation in maxilla. They also concluded that Implants placed off-axis usually require angle-corrected abutments. Furthermore, (Koutouzis and Wennstrom., 2007) also compared the bone levels of fixed partial dentures restored on implants at 5 years that used both axial and non axial placed implants, and concluded that implant inclination had no effect on peri-implant bone loss. (Butura et al., 2011) studied the use of distal-angled implants for the support of fixed hybrid prosthesis as a viable alternative to grafting and nerve lateralization. Further work by (Krekmanov and Aparicio ., 2000-2002) also showed that tilted implants did not exhibit advanced or extreme bone loss nor did they demonstrate significant bone stress when compared with cantilevers on vertically placed implants. Factors that appear to have led to success in this study were careful implant site preparation including tapping, the use of relatively low torque-producing implants, and preparation of an All-on-Four shelf to provide inter restorative space and establish optimum implant sites. Similar successes have been duplicated by other authors; however, most would advocate the use of additional 2 maxillary implants for patients when encountered with certain risk factors (ie, poor bone quality, opposing natural dentition, and men with parafunctional habits (Butura et al., 2011; Dym., 2015).

New technologies based on 3D evaluation of patients for dental implants, has opened new avenues to clinicians for accurate and predictable diagnosis, planning, and treatment planning. CT-guided implant surgery facilitates the placement of dental implants into an ideal position according to a restoratively driven treatment plan (Spector., 2008). The final tooth position is determined first. The ideal implant position is then planned, and the implant is then placed into that position with precision (Orentlicher 2011 and Ganz 2015).



**Figure 1.** Preoperative panorex indicating a failing dentition  
**Figure 2.** Postoperative panorex with All-on-Four implants in place.

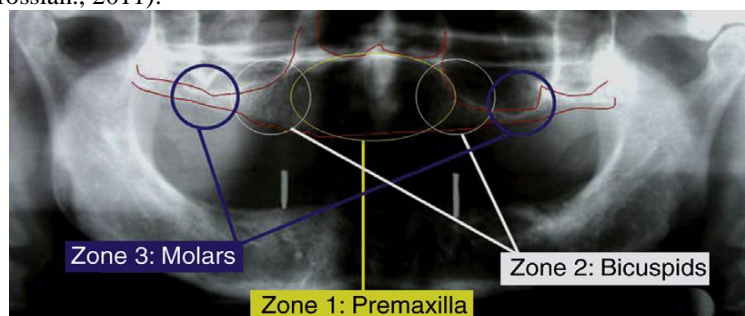
#### **Advantages Of Malo's Bridge**

Malo's bridge has high success rate and it eliminates need for bone grafting which is invasive, costly and uncomfortable for patient. Procedure is well tolerated and of shorter duration. All in a single day procedure is feasible, not only the surgery but also the placement of teeth with immediate function. Traditional techniques often involve multiple surgeries and can take over a year to complete. The bridge is hygienic, easy to maintain and clean. Typically about half the cost of alternative techniques which require bone grafting and the placement of more than four implants. Implants follow a dense bone structure. Longer implants can be placed by tilting them posteriorly that also helps in improving anchorage. Tilting improves A-P spread of implants resulting in more stable prosthesis. A-P spread enhances load distribution for prosthesis. Shorten cantilever (maximum of 7 mm for maxilla and 1.5–2.0 mm A-P spread for mandible) reduces prosthetic fracture/instability and marginal bone height stability. Marginal bone height of implants is maintained with rigid prosthesis. Tilted implants have similar success rate as traditional implants when splinted together (Chan and Holmes 2015).

#### **"ALL-ON-4" VARIATIONS**

##### **All-on-4: zygoma implants and quad zygoma**

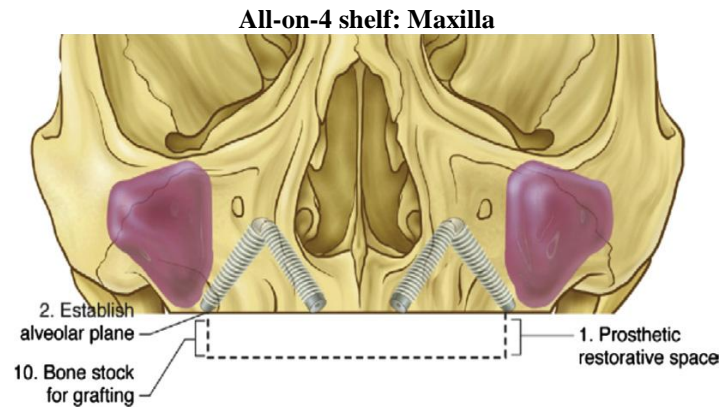
Branemark initially developed zygoma implants for 3 primary reasons as his treatment modality for (1) maxillary defect with post cancer (CA) resection, (2) trauma, (3) severe maxillary atrophy. The concept of the zygoma implants is to use available bone at a distant site when locally insufficient. The apex of the implant gets engaged to the body of the zygoma, transversing the maxillary sinus and emerging from the first molar position at a 45° angle (Parel., 2011). (Bedrossian., 2008) categorizes the maxilla into 3 zones radiographically: zone 1 = premaxilla, zone 2 = premolar and zone 3 = molar. The zygoma implants are indicated where there is insufficient bone in the premolar and molar regions, leaving only the anterior premaxilla available. The implant configuration will be 2 axial implants in the anterior position and 2 zygoma implants in the posterior region. If there is absolutely no available bone in the maxilla, the Quad Zygoma uses 4 zygomatic implants to support full-arch prosthesis (Bedrossian., 2011).



**Figure 3** The zones of the maxilla.

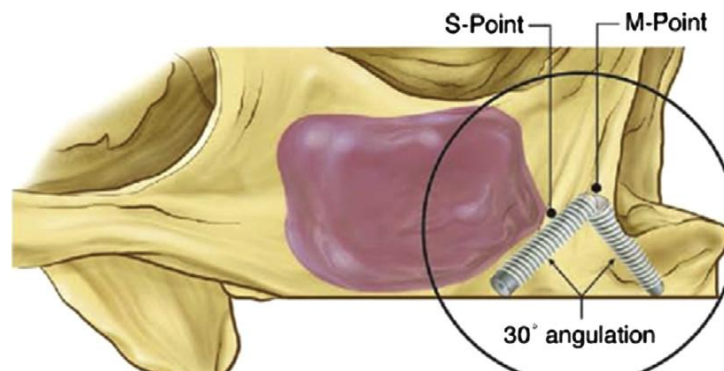
**All-on-4 "V-4"**

(Jensen and Adams., 2009) described 2 case reports of an "All-on-4" concept called "V-4" and how these implants are primarily placed in such a formation in the anterior mandible. All-on-4 "V-4" is indicated for patients with severe mandibular atrophy typically with 5 to 7 mm of remaining native bone (Cawood & Howell 1988- Class IV-V). These 4 implants are placed at a 30° angle all directed towards the symphysis where the bone mass remained to help support a full-arch prosthesis.



**Figure 4.** All-on-4 Shelf; Maxilla. Bone leveling of the alveolus creates a new alveolar plane that functions as a "shelf" on which to place dental implants. The All-on-4 technique must take advantage of available bone, which is best observed using the All-on-4 Shelf approach, for which angled implants and compensating angled abutments are placed.

The All-on-4 Shelf: Maxilla can be a treatment option for mild, moderate, and severe maxillary resorption cases whereby the alveolus topography is re-created by bony reduction, allowing implants to be placed strategically within the premaxilla in an "M" configuration when viewed from the frontal aspect. The reduction of thin crestal bone helps uncover thicker basal bone. Moreover, it allows for proper interocclusal distance of 22 mm required for the final prosthesis. The anterior and posterior implants converge apically in a 30° angulation using the native bone for maximal anchorage. The posterior site "S point" denotes the most anterior point of the anterior wall of maxillary sinus, and the "M point" denotes the maximum bone available at the pyriform rim just above the nasal floor. The divergence of these implants toward the alveolus ridge helps increase the A-P spread for better prosthetic load distribution. The only contraindication for the All-on-4 Shelf: Maxilla is if there is an indistinction between the nasal fossa and the maxillary sinus, making it 1 continuous cavity in which zygomatic implants can be the alternative treatment option (Jensen et al., 2010).



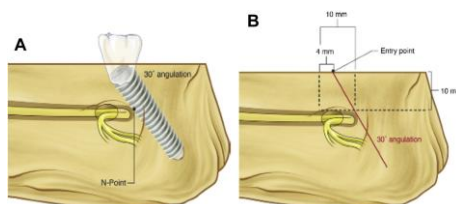
**Figure 5.** When the shelf is well away from the sinus, the most anterior sinus deflection (S point) is identified using a lateral antrostomy burr hole. The space from this point to the shelf is measured. This same distance posterior of the S point perpendicular should be the entrance location of the posterior implant site (when placed at 30°) to avoid the sinus.

**All-on-4 shelf: Mandible**

Flat alveolus ridge and proper interarch space, a minimum of 20 mm, are required for the mandibular arch. The implant configuration is identical to Malo's "All-on-4" design, with 2 exceptions in regards to the posterior implants. First, the 1:1 ratio represents the available bone height from alveolar bone to mental nerve (N point) and the number of millimeters of distance gained by tilting the posterior implant in a 30° angle.

The second key point is that the posterior implant can be positioned behind the mental foramen when sufficient bone is present, unspecified by the authors, above the inferior alveolar nerve via a transalveolus fashion from buccal to lingual with engagement to the lingual cortex for better A-P spread (Jensen et al., 2011).

All on 4 shelf establishes prosthetic restorative space, a level alveolar plane and uniform implant levels. It establishes alveolar width for implant diameter selection. Bone reduction makes basal bone accessible for implant fixation. It helps to establish arch form, implant distribution, and antero-posterior spread. It identifies optimal implant sites and secondary implant sites. It exposes lingual plate width and lingual concavity. Moreover, it facilitate posterior implant placement with respect to the nerve and provides bone stock for secondary bone grafting



**Figure 6.** (A) The most anterior deflection of the intraosseous nerve is termed Npoint. (B). A 10-mm vertical height measured from N point to the All-on-4 shelf allows for a 10-mm distalization on the shelf when an implant is placed at 30°. This usually allows for an increased anterior posterior spread of implants of 1 full bicuspid tooth.

### All-on-4 transsinus technique

(Jensen et al., 2012) described an alternative surgical technique to zygomatic implants using a combination of sinus floor grafting bone morphogenetic protein (BMP)-2 with simultaneous transsinus implant placement and immediate function with either atrophic maxilla, post-All-on-4 Shelf: Maxilla horizontal bone reduction, or pneumatized sinus traversing the canine/lateral and sometimes the central incisor region. These implants are placed in an “M” configuration with engagement to the “M point,” where the pyriform rim has good-quality bone. Jensen and colleagues used 15 mm to 18 mm length implants torqued to 35 Ncm with abutment insertion at 15 Ncm for immediate load criteria.

(Nobel Biocare “All-on-4” Procedures & Products Manual 2007) explained some inclusion criteria for “all-on-4”

1. No severe parafunctional habits.
2. Standard mouth opening (40 mm)
3. Edentulous maxilla with minimum bone width of 5 mm and minimum bone height of 10 mm within the premaxilla.
4. Edentulous mandible with minimum bone width of 5 mm and minimum bone height of 8 mm within the intraforamen region.
5. Minimal 10 mm implant length for maxilla.
6. Tilt implant at 45° maximally to reduce cantilever.
7. If angulation is 30° or more, it is necessary to splint the tilted implants.
8. For posterior tilted implants, plan the distal screw access hole to be located at the occlusal surface of the first molar, second premolar, or first premolar.
9. Can accommodate 10 to 12 teeth as a fixed prosthesis with a maximum 1 to 2 teeth cantilever in final prosthesis.
10. If planned extraction cases, clean sites thoroughly and place implants in between extraction sites.

### Contraindications

1. Immunocompromised patients.
2. Patients who have received radiation treatment to jaws.
3. Patients on biphosphonate therapy (Scherer., 2014)

### Patient Workup

“All-on-4” workup consists of clinical evaluations, radiographic evaluations, and laboratory analysis of mounted models with duplicate clear denture for composite defect detection. This clear denture is also used clinically to aid in future prosthetic selection. Clinical evaluation includes assessment of VDO, Composite defect detection (hard and soft tissue loss), Smile line, Lip support and A-P tooth position of maxilla, Alveolus ridge plateau, Occlusion and Sufficient keratinized tissue. Vertical dimension of occlusion (VDO) is one of the most important factors to verify and can be confirmed with the patient’s existing denture or natural dentition if full-mouth edentulation is planned. An interim prosthesis can be fabricated by the laboratory technician or by

computer-aided design (CAD)/ computer-aided manufacturing (CAM) technology with the correct VDO before immediate load (Bedrossian., 2011).

In Radiographic Evaluation Cone-beam computed tomography (CT) has been commercially available to allow clinicians to see the maxilla and mandible in a 3-dimensional view (height, width, and volume). It also shows the quality of bone expressed in Hounsfield Units (HU). A study by (Parel and Phillips 2011) suggested bone quality less than 100 HU units reflects poor quality bone and will result in high failure rates. Virtual implant planning could be performed by using the "prosthetic driven approach." The prosthesis, abutment, and implants can be designed to ensure proper emergence of the implant to prosthetic interface. Moreover, these implants can be seen in multiple views (ie, axial and sagittal) for bony support. For guided surgery cases, this information can be transferred to the laboratory technician for surgical guide fabrication (Ganz., 2015). Cone-beam computed tomography (CBCT) has become a helpful tool in assessing the stability of the dental implant site and further studies are necessary to determine the actual role of CBCT in detecting early implant failure (Yepes., 2015).

After completing the above evaluations, a denture wax-up in proper VDO should be mounted in an articulator. To further evaluate the composite defect, the patient's denture should be duplicated in a Lang duplicator with clear resin. This clear denture should be resealed either in the patient's mouth or on the cast and the extent of hard and soft tissue loss determined. The amount of tissue loss would allow the restorative clinician to select the type of prosthesis to restore. If tooth-only defect is present, then standard ceramo-metal restoration is indicated.

There are 2 basic options that clinicians can offer patients when both hard and soft tissue deficiencies are identified. Fixed-hybrid (profile prosthesis) would be suited when the transitional line is not visible during high smile line, whereas fixed-removable prosthesis (Marius Bridge) would be good for visible ridges during high smile line assessment because the flange can extend into the vestibule and mask the transition line (Bedrossian., 2011).

#### **Impression Technique For Provisional Prosthesis Fabrication Day Of Surgery (2–3 Hours After Surgery)**

1. Confirm implant torque to greater than 35 Ncm.
2. Place multiunit abutments on implants as previously described.
3. Suture flaps closed.
4. Place the impression copings closed tray onto the multiunit abutments.
5. Take an impression and send to laboratory.
6. Place protective healing caps on abutments while provisional is being made.
7. Provisional prosthesis is torqued to 15 Ncm.
8. Seal access hole.
9. Bilateral Group Function Occlusion with one tooth cantilever maximum.
10. Soft diet recommended.

#### **Prosthetic procedure: "all-on-4"**

Provisional Prosthesis Conversion with Existing Mandibular Denture for Immediate Load

1. Confirm implant torque to greater than 35 Ncm.
2. Take a bite registration.
3. Place 30<sup>0</sup> or 17<sup>0</sup> multiunit abutments at posterior sites and place 0<sup>0</sup> or 17<sup>0</sup> multiunit abutments at the anterior sites so they emerge toward the occlusal surface of the denture.
4. Confirm seating with a radiograph and then torque the posterior abutments to 15 Ncm and 30 Ncm for the anterior abutments.
5. Place a protective healing cap on these abutments and suture the surgical site with resorbable sutures (ie, 3-0 or 4-0 chromic gut).
6. Index the denture with impression material (ie, polyvinylsiloxane [PVS]).
7. Create adequate space with an acrylic bur in the denture where index markings are present.
8. Remove the protective healing cap and place temporary coping (multiunit) onto the multiunit abutments.
9. Adequate clearance is needed for temporary coping (multiunit) and denture.
10. Recheck occlusion to be coincident before luting with acrylic.
11. Lute the temporary coping (multiunit) with acrylic material.
12. Lute the tissue-baring surface of the denture to the temporary coping (multiunit) with acrylic.
13. Reduce excess temporary coping (multiunit) flush with denture level.
14. Provisional prosthesis is inserted with prosthesis screws at 15 Ncm.
15. Seal access hole with material (ie, thread seal tape and cavitec or PVS).



16. Bilateral group function occlusion with one-tooth cantilever maximum.
17. Soft diet recommended.

Alternatively, if a provisional is not available after completion of the surgical procedure, mucoperiosteal flaps are sutured and multiunit abutments are placed and torque to the same specifications. Next, place the impression copings closed tray onto the multiunit abutments and take an impression using either polyether or PVS material. Both open-tray and closed-tray techniques are acceptable. The impression is removed, inspected, and sent to the dental laboratory for soft tissue model and fabrication of provisional prosthesis. Protective healing caps are placed over the multiunit abutments while the provisional is being fabricated. A full-arch interim acrylic prosthesis is placed and secured with prosthetic screws torqued to 15 Ncm; this is completed within 2 to 3 hours of surgery (Nobel Biocare "All-on-4" Concept manual for conventional and guided surgery 2012).

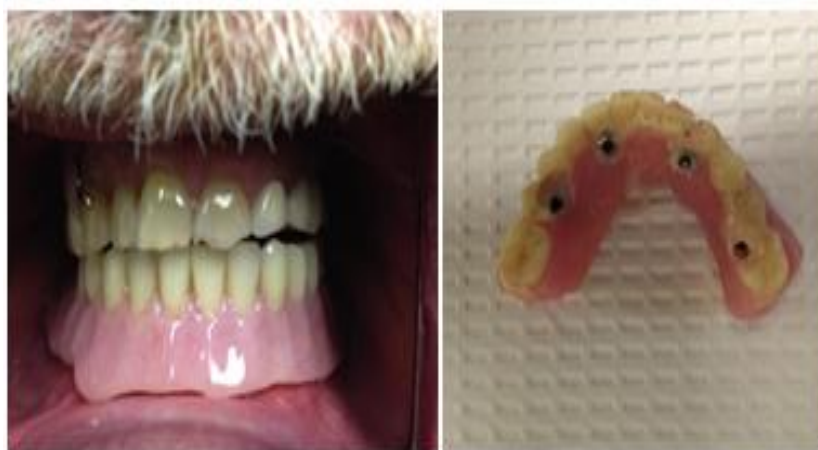

Figure 7. Provisional prosthesis is inserted with prosthesis screws at 15 Ncm.

Figure 8. Bilateral group function occlusion with one-tooth cantilever max.

#### **Final Prosthetic Options: "All-On-4" (4 To 6 Months After Initial Implant Placement)**

If there is no composite defect and tooth only loss is identified, then a ceramometal restoration is indicated. The clinician can offer 2 fundamental prosthetic options to their patients based on degree of composite defect and the visibility of the alveolar ridge during high smile assessment. Fixed-hybrid (profile prosthesis) is suitable for a nonvisible alveolar ridge, although a fixed-removable prosthesis (Marius Bridge) is warranted when the ridge is visible. Nobel Biocare has 3 lines of Nobel Procera Implant Bridges with titanium and Zirconia framework available as their fixed-hybrid option. The Basic option is a titanium implant bridge with acrylic teeth and gingival made from acrylic material. Their Medium option is a titanium implant bridge veneered with composite teeth, porcelain, or E-Max crowns. Last, the Premium option is a bridge with either individualized Nobel Procera's alumina or zirconia crowns, each cemented to NobelProcera's framework.

Canine and anterior guidance are incorporated into this final occlusion and the prosthetic-mucosal surface places slight pressure against soft tissue. Fixed-removable restoration is an acrylic prosthesis that can accommodate the following type of bars: Dolder, Hader, Round, Paris, and or Free Form Milled Bar to the final prosthesis as an overdenture option. There are many different attachments clinicians can choose based on level of comfort (ie, locators, balls, clips). Bilateral group function is incorporated into the final occlusion and the final prosthesis should have at least 12 teeth for proper esthetics and function (Nobel Biocare "All-on-4" Concept manual for conventional and guided surgery 2012).

Final prosthesis fabrication can commence after 4 to 6 months of healing. The provisional prosthesis is removed, and implant stability and abutment torque need to be reconfirmed to be equivalent to immediate function specifications. Replace the provisional prosthesis in the patient's mouth and take a bite registration. After which, remove the provisional prosthesis and place multiunit laboratory analogs to the denture and mount it against a counter model on an articulator and a putty index is performed on the prosthesis that provides information to the laboratory technician the length of the future resin pattern framework. This resin pattern is fabricated in the laboratory in multiple sections that are transferred to the patient's mouth and luted with more autopolymerizing resin to ensure an accurate fit.

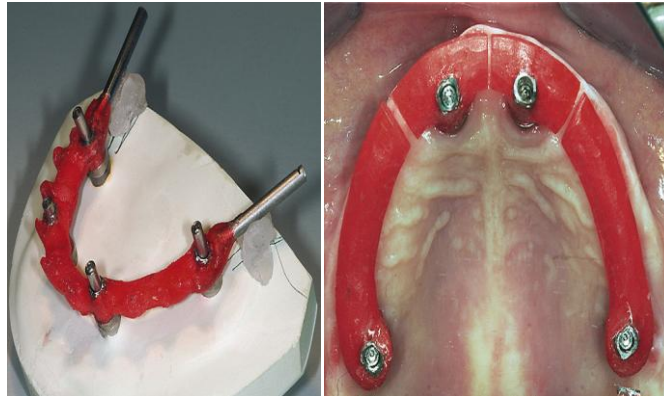


Figure 9. Resin pattern gets scanned and framework is made by CAD/CAM technology Figure 10. Transfer the resin pattern to patient's mouth and lute the sections together with resin.

The completed pattern gets transferred back onto the cast and a framework is fabricated with CAD/CAM technology and returned to the patient's mouth for try-in.

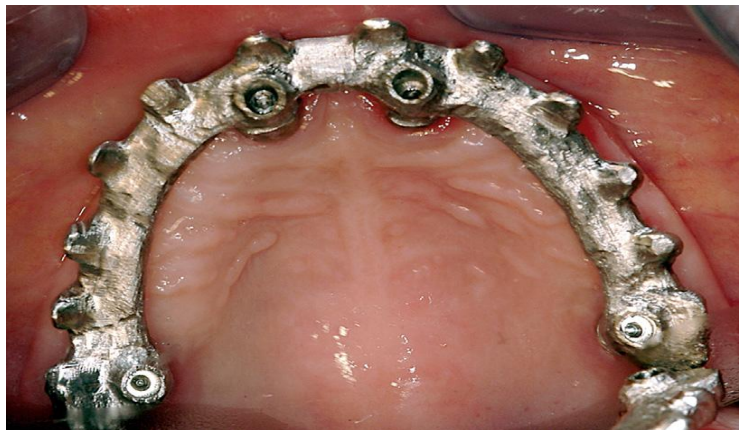


Figure 11. Try-in framework (passive fit) in patient's mouth.

A passive fit is paramount to ensure accuracy and not to translate undue strain onto the implants. Soft tissue index is performed and sent back to the laboratory for a set up. This relationship of soft tissue and the tissue-bearing surface of the future prosthesis is determined so an intimate adaptation can be fabricated from this index. Wax try-in is performed with framework, and the final prosthesis is seated in the patient's mouth.

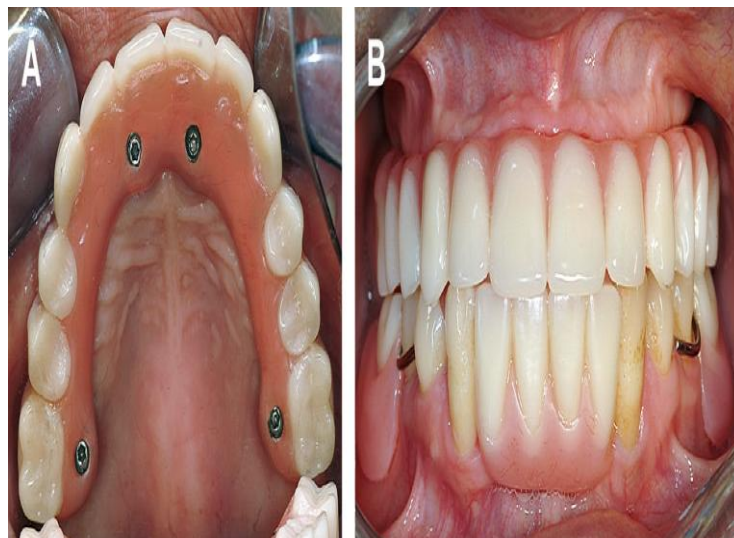


Figure 12. (A, B) Final delivery of prosthesis

The All-on-4 treatment concept using biohorizon tapered internal LaserLok Implant system with reverse buttress self-cutting threads for increased initial stability study demonstrates that as long as the principles of ALL-ON-4 Treatment Concept are observed, an alternative Implant System can be used with great success (Chu., 2010).

The outcome and special characteristics of immediate implant rehabilitation using the All-on-Four treatment concept in completely or potentially completely edentulous Chinese patients using 2 implant systems *Branemark* and *Nobel Speedy groovy* has been studied. The implants were placed in fresh extraction sites and healed sites. Implants were immediately loaded with a fixed full-arch provisional prosthesis and no significant difference between their survival rates (Di et al., 2013). All-on-4 concept implantation for mandibular rehabilitation with a fixed detachable dental prosthesis in an edentulous patient with Parkinson Disease using a minimally invasive technique after a 1 year follow-up, showed no complications and improved patient's mastication ability and life quality (Liu et al., 2015)

## II. Conclusion

Multiple studies by various independent authors have shown the "All-on-4" technique has similar success rates as compared with the well-studied traditional vertical implants owing to thbiomechanics. The "All-on-4" can be a viable option the clinician can offer to their edentulous patients who seek full-arch rehabilitation even with planned extraction cases. Atrophic jaws that normally would require traditional bone grafting before implant placement will increase treatment time, costs, and morbidity associated with these grafting procedures. Furthermore, the ability to reduce length of treatment will have a positive psyche so, patients can return back to normal form and function.

## References

- [1]. Babbush, CA, Kutsko, GT & Brokloff, J 2011 'The All-on-Four Immediate function treatment concept with NobelActive Implants: A Retrospective study', JOI, vol-4, pp 431-445.
- [2]. Butura, CC, Galindo, DF & Jensen, OT 2011, 'Mandibular All-on-Four Therapy using angled implants: A three year clinical study of 857 implants in 219 jaws', Dent Clin N Am 55, pp 795-811.
- [3]. Chu, PK 2010, 'A case study: The All-on-4 treatment concept using biohorizon tapered internal implants', Clinical and Practical Oral Implantology- vol -1 no. 3, pp 28-36
- [4]. Di, P, Lin, Y, Li, JH, L, Lu o, J, Q, LX, Chen, B & Cui, HY 2013, 'The All-on-Four Implant Therapy protocol in the management of edentulous Chinese patients', Int J Prosthodont; 26: pp 509-516.
- [5]. Dym, H April 2015 'Implant Procedures for the General Dentist', Elsevier, Volume 59, Number 2, pp 421-470.
- [6]. Graves, S, Mahler, BA, Javid, B, Armellini, D & Jensen, OT 2011, 'Maxillary All-on-Four Therapy using angled implants: A 16-month clinical study of 1110 implants in 276 jaws', Dent Clin N Am 55, pp 779-794.
- [7]. Jensen, OT, Adams, MW, Cottam, JR, Parel, SM & Phillips, WR 2011, 'The All-on-4 Shelf: Mandible', J Oral Maxillofac Surg 69; pp 175-181.
- [8]. Koutouzis T, Wennstrom JL. Bone level changes at axial- and non-axialpositioned implants supporting fixed partial dentures. A 5-year retrospective longitudinal study. Clin Oral Implants Res 2007;18(5):585-90.
- [9]. Krekmanov L. Placement of posterior mandibular and maxillary implants in patients with severe bone deficiency: a clinical report of procedure. Int J Oral Maxillofac Implants 2000;15(5):722-30.
- [10]. Aparicio C, Perales P, Ranger B. Tilted implants as an alternative to maxillary sinus grafting: a clinical, radiologic, and periosteal study. Clin Implant Dent Relat Res 2001;3:39-49.
- [11]. Aparicio C, Arevalo X, Ouzzani W, et al. A retrospective clinical and radiographic evaluation of tilted implants used in the treatment of the severely resorbed edentulous maxilla. Appl Osseointegration Res 2002;3:17-21.
- [12]. Ganz SD. Three-Dimensional Imaging and Guided Surgery for Dental Implants. Dent Clin N Am 59 (2015) 265-290.
- [13]. Orentlicher G. Guided Surgery for Implant Therapy. Dent Clin N Am 55 (2011) 715-744.
- [14]. Parel S. Chapter 23: the evolution of the angled implants. In: Babbush C, Hahn J, Krauser J, et al, editors. Dental implants, the arts and science. 2nd edition. Maryland Heights (MO): Saunders an imprint of Elsevier; 2011. p. 370-88.
- [15]. Bedrossian E. Chapter 15: graftless solution for atrophic maxilla. In: Babbush C, Hahn J, Krauser J, et al, editors. Dental implants, the arts and science. 2nd edition. Maryland Heights (MO): Saunders an imprint of Elsevier; 2011. p. 251-9.
- [16]. Bedrossian E, Sullivan RM, Fortin Y, et al. Fixedprosthetic
- [17]. implant restoration of the edentulous maxilla: a systematic pretreatment evaluation method. J Oral Maxillofac Surg 2008;66(1):112-22
- [18]. Jensen OT, Adams MW. All-on-4 treatment of highly atrophic mandible with mandibular V-4: report of 2 cases. J Oral Maxillofac Surg 2009;67:1503-9.
- [19]. Jensen OT, Adams M, Cottam J, et al. The All-on-4: shelf. J Oral Maxillofac Surg 2010;68:2520-7.
- [20]. Jensen OT, Adams M, Cottam J, et al. The All on 4 shelf: mandible. J Oral Maxillofac Surg 2011;69:175-81.
- [21]. Jensen OT, Cottam J, Ringeman J, et al. Trans-sinus dental implants, bone morphogenic protein 2, and immediate function for all-on-4 treatment of severe maxillary atrophy. J Oral Maxillofac Surg 2012;70:141-6.
- [22]. Nobel Biocare "All-on-4" Procedures & Products Manuel 2007.
- [23]. Parel S, Phillips W. A risk assessment treatment planning protocol for the four implant immediate loaded maxilla: a preliminary findings. J Prosthet Dent 2011; 106:359-66.
- [24]. Parel S. Chapter 23: the evolution of the angled implants. In: Babbush C, Hahn J, Krauser J, et al, editors. Dental implants, the arts and science. 2nd edition. Maryland Heights (MO): Saunders an imprint of Elsevier; 2011. p. 370-88.
- [25]. Nobel Biocare "All-on-4" Concept manual for conventional and guided surgery 2012.
- [26]. Malo P, De Araujo Nobre M, Lopes A, et al. "All-on-4" immediate function concept for completely edentulous maxillae: a clinical report on the medium (3 years) and long-term (5 years) outcomes. Clin Implant Dent Relat Res 2011;14(Suppl 1): e139-50.



- [27]. Nobel Biocare product catalog 2013/2014.
- [28]. Babbush C, Rosenlicht J. Chapter 14; inferior alveolar nerve lateralization and mental neurovascular distalization. In: Babbush C, Hahn J, Krauser J, et al, editors. Dental implants, the arts and science, second edition. Maryland Heights (MO): Elsevier 2011. p. 237.
- [29]. Babbush C, Kanawarti A, Brokloft J. A new approach to the All-on-Four treatment concept using narrow platform NobelActive implants. *J Oral Implantol* 2013; 39(3):314–25.
- [30]. Malo, P, Rangert, B & Nobre, M 2003, ' All-on-Four' Immediate function concept with branemark system implants for completely edentulous mandibles: A retrospective study' *Clinical Implant Dentistry and Related Research*, vol-5, supplement 1, pp 2-9.
- [31]. Liu, FC, Su, WC, You, CH, Wu, AYJ 2015, 'All-on-4 concept implantation for mandibular rehabilitation of an edentulous patient with Parkinson disease: A clinical report' *J Prosthet Dent* ;114:745-750
- [32]. Cavalli N, Barbaro B, Spasari D, Azzola F, Ciatti A, Francetti L 2012. Tilted implants for full arch rehabilitations in completely edentulous maxilla: A retrospective study. *Int J Dent*:180379.
- [33]. Thumati P, ReddyM , Mahantshetty M , Manwani R 2015" All-On-4/DIEM 2" A concept to rehabilitate completely resorbed edentulous arches *Journal of Dental Implants*;Vol 5;Issue 1.
- [34]. Scherer MD 2014. Presurgical Implant-Site Assessment and Restoratively Driven Digital Planning, *Dent Clin N Am* 58 ;561–595

\*Dr. Deepika Bainiwal. "Malo' S Bridge An "All-on-4"/ Diem-2 Immediate Function Concept."  
*IOSR Journal of Dental and Medical Sciences (IOSR-JDMS)* 16.9 (2017): 67-75