

Two Case Reports of Fracture And Bypassing Separated Instrumens in The Root Canal

Mohammed Rashed Nabi ALDOSKI

Assist.Lec BDS, Msc Conservative Dentistry , College Of Dentistry , Department Of Conservative And Prosthodontics , University Of Duhok, Kurdistan Region , Iraq

Abstract: Separation of an endodontic instrument in the root canal is a common mishap that may occur during endodontic treatment. It may have a potential impact on the outcome of the treatment as it hinders cleaning and shaping of the root canal. Removal of the separated instrument is often advised but factors like poor access and visibility to the separated instrument makes it difficult and also the amount of dentin to be removed is more. As an alternative removal, bypassing technique is very effective and conservative. This article describes the management of two patients with separated instrument in the root canal, by successfully bypassing those separated instrument.

Keywords: Bypassing, cold lateral condensation, fine file, obturation, separated instrument.

I. Introduction

The primary objectives of root canal treatment are proper cleaning, shaping and 3-D fluid tight sealing of the root canal system. These objectives will be made impossible if an instrument gets separated in the canal. The success of root canal treatment declines markedly if the clinician fails to achieve the above said primary objectives. Endodontics has developed over time with the introduction of CBCT in diagnosis, dental operating microscope, ultrasonics, surgical loupes etc. Even though root canal treatment is being done under much developed conditions, mishaps like instrument separation are inevitable. Evaluation of post endodontic radiographs show that 2-6% of the cases have separated instruments¹. The presence of a separated instrument in the root canal leads to failure of root canal treatment. The prognosis depends on the degree of contamination of canal at the moment of instrument separation. Proper assessment should be made whether the canal can be instrumented even in the presence of fractured instrument. If the canal cannot be instrumented decisions should be made to remove the separated instrument²⁻⁴. The probability of removing a separated instrument is directly related to visibility, i.e. whether the fragment can be visualised or not. Visibility depends on the location of separated instrument. When the fragment is inside or beyond the curvature, visibility requires straightening of root canal that may lead to unnecessary removal of dentin and thereby weakening the root structure.⁵⁻⁸ An alternative technique that does not require direct visibility to the fragment is "bypass", where a fine file is inserted between the fragment and root canal wall and thereby negotiating the canal to full working length and enable thorough instrumentation and obturation with the fragment remaining in situ. Incorporating the fragment in the root canal obturation material considerably improves the case prognosis.⁹ In this article I present two case reports in which separated instruments were successfully bypassed with uneventful post operative period.

II. Casereports

2.1. Casereport 1

A 59 year old man presented to my private dental clinic in duhok city, Iraq with the chief complaint of spontaneous pain in his lower left back tooth for 2 weeks. The pain intensified by thermal stimuli and on mastication. History revealed intermittent pain in the same tooth with hot and cold stimuli for the past 1 month. The patient's medical history was non-contributory. Intra-oral examination revealed a carious mandibular left third molar which was tender to percussion. The tooth was not mobile. On vitality checking using heated gutta percha (Dentsply) and cold test (Endofrost, Roeko) an intense lingering pain was noticed, where a selective pulp stimulation (Parkell pulp vitality tester) caused a premature response. A preoperative radiograph revealed distal radiolucency nearing the pulp with periodontal ligament space widening. From clinical and radiographic findings, a diagnosis of symptomatic irreversible pulpitis with symptomatic apical Periodontitis was made. Since the first and second molars were missing and the tooth under study was a good candidate for an abutment, root canal treatment was planned. The tooth was anesthetised with 1.8ml 2% lignocaine containing 1:200,000 adrenaline followed by rubber dam isolation. An endodontic access cavity was established. While cleaning and shaping the canals, a 15 size K file was separated in the mesio-

buccal canal. On taking IOPA, it was found that the separated file was located below the curvature of the root. Since the fractured segment could not be visualised and was below the root curvature, bypassing was preferred over retrieval. The access cavity was filled with chelating agent-17% EDTA (Avuprep) and a no. 6K file was introduced into the mesio-buccal canal for searching a way to bypass the instrument. After a few tries, it was able to get the 6K file past the instrument. Working length was confirmed radiographically. During the shaping of canals, copious irrigation with 5% sodium hypochlorite and saline was performed. Patency was kept with an 8 size K file between every instrument. Shaping of mesial canals were done upto 4% 25 hero shaper files and for distal canal upto X2 Protaper Next file. The complete shaping sequence in the mesio-buccal canal where the instrument was separated, is listed in table 1. After shaping and cleaning, calcium hydroxide (Avucal) was placed in canals and the cavity was sealed with cotton pellet and temporary restoration was given. After 2 weeks, patient reported for the second appointment. The tooth was again isolated and temporary restoration was removed. Calcium hydroxide was removed using sterile saline solution. Canals were dried using paper points. 4% guttapercha (Dentsply) was fitted in mesial canals and 6% guttapercha (Dentsply) was fitted in distal canal. Obturation was done using cold lateral condensation technique. Post obturation radiograph was taken. Recall visits were uneventful and the patient is still under review.

Table 1: sequence of shaping files used to bypass the separated instrument in case 1

6K
8K
SX protaper
10K
15K
20K
Hero shaper N ^o 25-6%
Hero shaper N ^o 25-4%

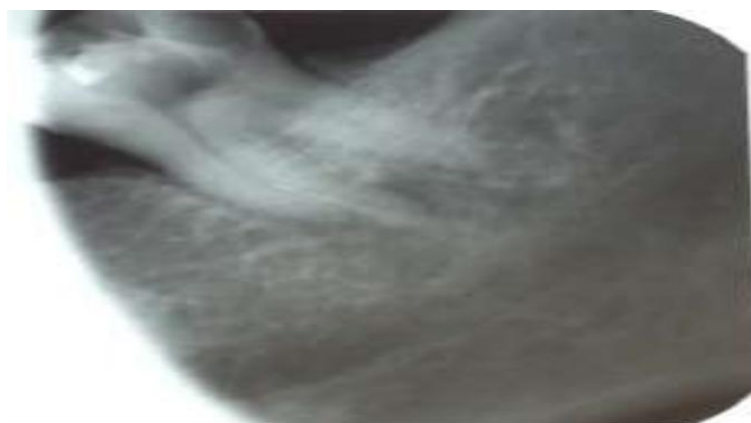


Figure 1: IOPAR of 38 showing fractured file in MB canal

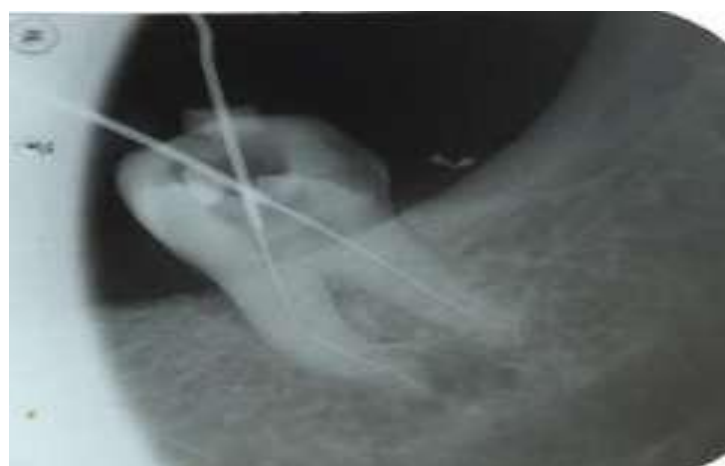

Figure 2: fractured file bypassed and working length determined

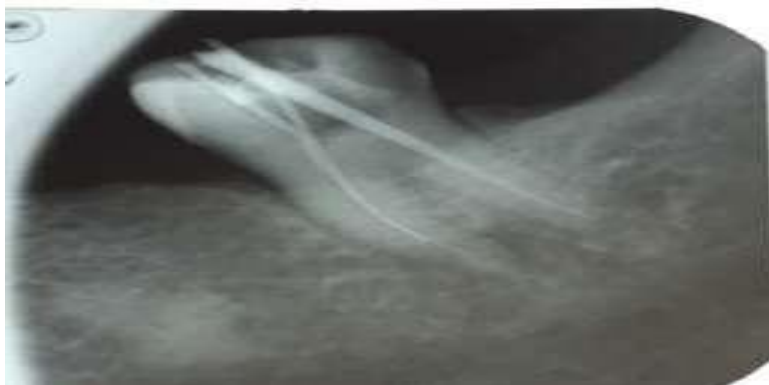

Figure 3: IOPAR of 38 with master cone

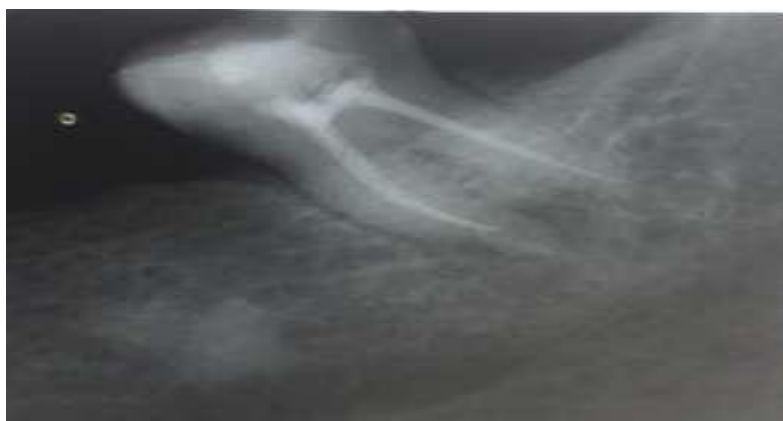

Figure 4: IOPAR of 38 after obturation

2.2. Casereport2

A 22-year-old woman presented to my private dental office in Duhok city, Iraq, with the chief complaint of gross decay of her lower right back teeth. Teeth were asymptomatic. On examination, carious mandibular first and second molars were found. Both teeth were root canal treated elsewhere 5 years back. Post-endodontic restorations were fractured. On radiographic examination, it was noticed that both teeth were poorly root canal treated with furcation involvement in 46 and a separated instrument in 47. Since the prognosis for 46 was poor, it was advised for extraction. Patient reported to my clinic 3 months later, after extraction of 46. The tooth was anesthetized with 1.8 ml 2% lignocaine containing 1:200,000 adrenaline followed by rubber dam isolation. The fractured restoration was removed. Endodontic access cavity prepared by the previous dentist was modified to get a better access to the canal orifices. Guttapercha from the canals were removed with the help of GP solvent (GP solve). On introducing 10 size K file to the canals, obstruction was felt in the mesiobuccal canal suggestive of separated instrument. The canal was kept under the field of DOM (Seiler) but the separated instrument could not be visualized. Owing to the fact that the file could not be visualized and limited thickness of the root, it was decided to bypass the separated file. Bypassing was started by introducing a 6 size K file. 17% EDTA (Avuprep) was used along with the 6 K file for chelation at the axial wall in the canal holding the separated instrument. It was able to direct the file inside the canal between the separated instrument and the axial wall of the canal. The same procedure had been repeated again to get patency of the canal and to reach the apex. Finally, the separated instrument was successfully bypassed and the file was reaching till the apical constriction. It was confirmed radiographically and thereby working length was also determined. During the shaping procedure, thorough irrigation of the canal was done with 5% sodium hypochlorite and sterile saline solution using alternatively. Intracanal medicament was given with calcium hydroxide (avucal) and patient was relieved. On the second visit, after removing calcium hydroxide, shaping of the canal was done and copious irrigation was carried out with 5% sodium hypochlorite and sterile saline solution. The complete shaping sequence to bypass the separated instrument is listed in table 2. Canals were dried using paper points. After taking master cone IOPA, obturation was done with guttapercha cones (Dentsply), using cold lateral condensation method. Follow-up was carried out after 1 month which was uneventful.

Table2: sequenceofshapingfiles usedtobypassthe separatedinstrumentincase2

6K
8K
SXprotaper
10K
15K
20K
HeroshaperN ⁰ 25-6%
HeroshaperN ⁰ 25-4%

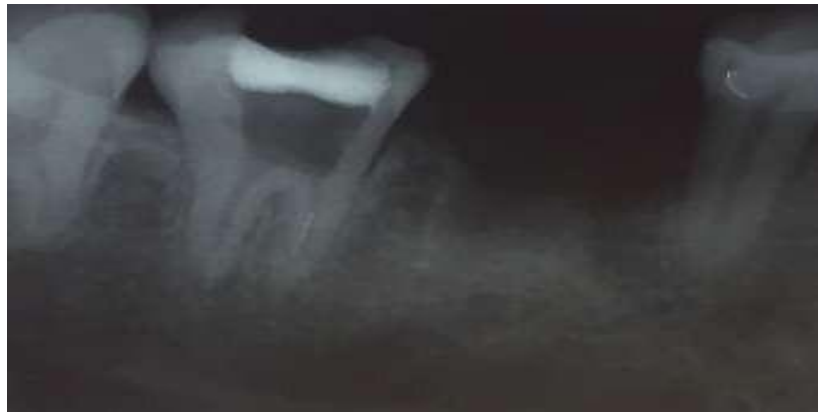

Figure5:a fracturedfileinthemesialcanalof47

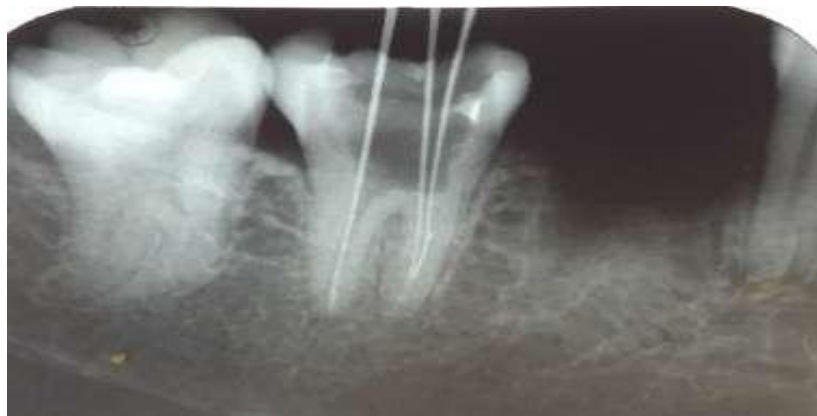


Figure6:fracturedfilebypassed

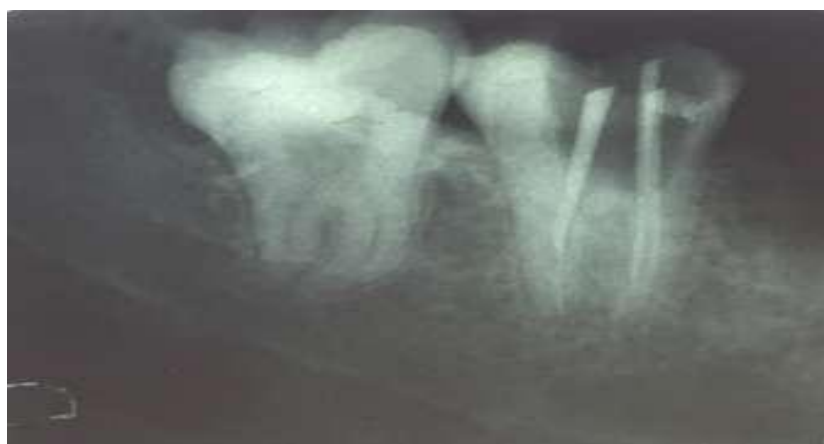

Figure7:IOPARof47withmasterconealongwithfracturedfile

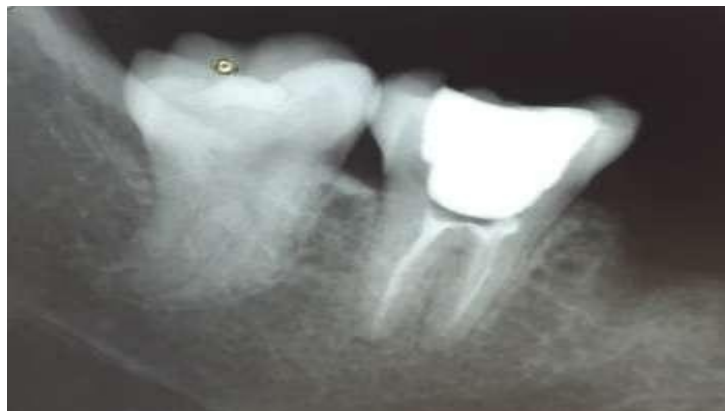

Figure 8: post obturation IOPAR of 47

III. Discussion

The presence of a separated instrument seriously affects the outcome of a root canal treatment as it usually prevents access to the apex, impedes thorough cleaning and shaping of root canal, inhibits the drainage from periapical area and prevents the three-dimensional fluid-tight obturation of root canal system.¹⁰

When an instrument gets separated in a canal, the clinician has got two options, either to retrieve the separated instrument or to bypass it. To retrieve the fragment, better visibility of the separated instrument is needed. Making a separated instrument visible requires straight line access to it. But when the fragment is located inside or beyond the root canal's curvature, visibility requires straightening of the root canal to a different extent which may lead to removing excessive amount of dentin and root weakening or even perforation⁵⁻⁸. Current information from scientific literature on the subject of broken instruments' retrieval is insufficient and mainly comprises clinical case presentations¹¹⁻¹³.

In both the cases we have mentioned in this article, the separated instrument was located beyond the root curvature. Considering the relatively small size of the root, retrieving the fragment was not opted for treatment.

An alternative technique that does not require direct visibility to the fragment is the so-called "bypass", where a fine file is inserted between the fragment and root canal wall and thereby negotiating the canal to full working length and enable thorough instrumentation and obturation with the fragment remaining in situ. Incorporating the fragment in the root canal obturation material considerably improves the case prognosis.⁹

Before bypassing a separated instrument, the clinician should examine different horizontally angulated radiographs¹⁴. Proper coronal access should be made before bypassing a separated instrument. Different techniques may be employed in flaring the canal coronal to an intra-canal obstruction. However, the predictable and safe way is sequential use of initially hand files, followed by Gates Glidden (GG) drill sizes 1 to 3. They should be used cautiously in approximation to the obstruction. Care should be ensured to use them away from furcation and to prevent transportation^{5,14}. In the cases mentioned in this article, we used the auxiliary shaping file Protaper SX to get proper coronal access.

Flushing the canal system with irrigating solution facilitate flaring of the canal walls. Their irrigation protocol, the delivery and sequence in which they are delivered is important to remove smear layer as well as debris¹⁵. The use of a chelating agent can facilitate removal of, or dissolve partially or totally, the debris stuck between the instruments' tips and between the instrument itself and the dentinal wall. In the cases reported here, we used a vampire chelating agent and it made bypassing a easy procedure.

IV. Conclusion

The best method for managing separated instruments in the root canal is prevention of such incidences. Thorough knowledge regarding root canal anatomy and various instruments used, following proven concepts and applying safe and modern techniques can prevent such an incidence. Even if a practitioner follows correct treatment protocol, instrument separation can happen. Decisions should be made whether to bypass it or to retrieve the separated instrument and it depends on various factors. Success of the treatment depends on the decision taken by the doctor. From the two cases mentioned in this article we were able to reach to a conclusion that if the separated instrument is able to be bypassed, it is more conservative than retrieving the separated instrument.

References

Two Case Reports of Fracture And Bypassing Separated Instrumens in The Root Canal

- [1]. KerekesK,TronstadL:Longtermresultsofendodontictreatmentperformedwithastandardizedtechnique.JEndod.1979; 5(3):83-90
- [2]. BahcallJK,CarpS,MinerM,SkidmoreL.Thecauses,prevention,andclinicalmanagementofbrokenendodonticrotaryfiles. DentToday.2005Nov;24(11):74, 76, 78-80
- [3]. CrumpMC,NatkinE.Relationshipofbrokenrootcanalinstrumentstoendodonticcaseprognosis:aclinicalinvestigation.JamDentAssoc.197 0Jun; 80(6):1341-1347.
- [4]. GrossmanLI.Fate ofendodonticallytreatedteethwithfracturedrootcanal instruments.JBr EndodSoc.1968 Jul-Sep; 2(3):35-37. [5]. RuddleCJ.Nonsurgical retreatment.JEndod.2004Dec; 30(12): 827-845.
- [5]. RuddleCJ.Brokeninstrumentremoval.Theendodonticchallenge.DentToday.2002Jul;21(7):70-72, 74, 76pasim.
- [6]. RuddleCJ.Nonsurgicalretreatment.In:Cohen S,BurnsRC,eds.Pathwaysof the pulp, 8thed. StLouis:Mosby;2002:875-930. [8]. RuddleCJ.Micro-endodonticnon-surgical retreatment.DentClinNorthAm.1997 Jul;41(3):429-454.
- [7]. SaundersJL,EleazerPD,ZhangP,MichalekS.Effectofaseparatedinstrumentonbacterialpenetrationofobturedrootcanals.J Endod. 2004Mar;30(3):177-179.
- [8]. NaidorfIJ.Clinicalmicrobiologyinendodontics.DentClinNorthAm.1974;18:329-344
- [9]. D'Arcangelo C,VarvaraG,DeFazioP. Broken instrument removal-two cases.J Endod.2000Jun; 26(6):368-370.
- [10]. Flanders DH.Newtechniques for removing separatedrootcanal instruments.NY State DentJ. 1996May;62(5):30-32.
- [11]. RahimiM,ParashosP.Anoveltechniquefortheremovaloffracturedinstrumentsintheapicalthirdofcurvedrootcanals.Int EndodJ. 2009Mar; 42(3):264-270.
- [12]. GorniFG,GaglianiMM.The outcome of endodontic retreatment:A2year followup.JEndod2004;30:1.
- [13]. 15.J.Huque,K.Kota,M.Yamaga,M.Iwaku, E. Hoshino. Bacterialeradication fromrootdentine by ultrasonicirrigation with sodiumhypochlorite.IEJ.1998;31:242-250.

Mohammed Rashed Nabi ALDOSKI. "Two Case Reports of Fracture And Bypassing Separated Instrumens in The Root Canal." IOSR Journal of Dental and Medical Sciences (IOSR-JDMS) 16.9 (2017): 86-91