

## Treatment of Arthrodesis of Neuropathic Joint By Trans Calcaneal Interlocking Nail: A Case Report

<sup>\*1</sup>Dr. William Isapure, <sup>2</sup>Dr. Anish Isapure <sup>3</sup>Dr. Pramod Bandgar

Corresponding Author: <sup>\*1</sup>Dr. William Isapure

Effects of neurological affliction of joints were first described by Charcot in 1868 [1]. Diabetes mellitus is currently the most common cause of neuroarthropathy [2]. Abnormal nociception and proprioception lead to progressive destruction of the joint. Management of Charcot's arthropathy by definitive surgical treatment remains a challenge despite technical advances in treatment modalities. In the diabetic population, ankle neuroarthropathy constitutes 3% to 10% of all cases. This leads to significant instability, fracture and collapse of ankle mortise and carries a high risk of amputation of the lower limb [3–7].

There has been change in the philosophy of surgical management of neuroarthropathy, from amputation to limb salvage. Sir John Charnley used uniplanar external fixator with compression clamps for ankle arthrodesis with variable success. Recent studies have shown good results with deformity correction and arthrodesis with internal fixation [8,9]. The principal goal of surgical intervention is to achieve a stable plantigrade foot without any deformity and to prevent re-ulceration [10]. There are numerous methods proposed to obtain a stable arthrodesis of the ankle joint [11–13]. External fixation or internal fixation have been used, however, there are still controversies over the most successful and reproducible method. In this backdrop, the present case report elicits neuropathic joint of the right ankle treated by trans calcaneal interlocking nail under spinal anaesthesia.

### I. Case Report

A 50 years old male reported with swelling of the right ankle joint since one year, deformity of the ankle joint since 8 months and difficulty in walking for 6 months. The patient was apparently alright 1 yr back when he started having swelling in right ankle joint. Further mild swelling has recurred and it progressively increased over the months, now the swelling is 10x12cm in size. Furthermore, the swelling aggravated on standing, walking and not relieved on rest.

For the last 8 months patient is having equinus deformity of the ankle. The patient He has to take support of walking stick and also developed a limp while walking. The pathological and radiological examination reveals the following outcomes. The X- rays both ankle joint - AP view & Lateral View displayed total loss of joint space on right, presence of right subtalar subluxation, presence of osteolytic lesions on right, soft tissue swelling on right, osteoarthritic changes of the ankle and distortion of normal anatomical axis (Fig 1A & 1B). Thus based on the final diagnosis, Neuropathic joint arthrodesis of the right ankle and treated with debridement and fusion of the ankle joint with trans calcaneal interlocking nail under spinal anaesthesia.

### II. Surgical Intervention

The patient is positioned supine on a radiolucent operating table with a well-padded bump under the ipsilateral buttock in order to internally rotate the involved extremity. We place another bump under the heel, so that intraoperative cross-table fluoroscopic imaging is facilitated. Spinal anesthesia is usually used, and a thigh pneumatic tourniquet greatly facilitates plantar dissection. We use intraoperative C-arm fluoroscopy. A longitudinal plantar approach is used, placing the incision slightly lateral to the midline, especially in the patient with significant valgus of the hindfoot and ankle. After the incision is made, blunt dissection is taken down to the plantar fascia, which is split longitudinally. The intrinsic muscles are swept laterally, and the neurovascular bundle is identified at the medial portion of the wound. A sharp awl is used to make a plantar calcaneal corticotomy, and the subtalar and tibiotalar articular surfaces are usually opened up with the use of a cannulated drill over its threaded guide wire. This opens up the tibiotalocalcaneal canal enough that a spade-tipped guide wire can be passed into the tibial medullary canal more readily. A series of progressively larger flexible reamers are used to open the tibiotalocalcaneal canal, reaming to a full to 1 mm diameter larger than the anticipated nail outside diameter.

The nail is attached to its alignment guide after noting the appropriate bow, and which holes are to be used for interlocking once the nail is inserted. The nail is slightly internally rotated, so that when the screws are inserted from lateral to medial, they will pass into the tibia, clearing the fibula. The foot is to be maintained in neutral or 0° plantar flexion, 0 to 5° valgus, and 10 to 15° of external rotation. The nail is quite readily inserted manually and then impacted on the plantar aspect of the hindfoot. The distal aspect of the nail is countersunk within the os calcis, and usually the distal two screws are inserted for interlocking first. This allows good

purchase of the foot, and then further impaction can be done, giving compression across the arthrodesis site before the nail is interlocked in the tibia. The interlocking screws are inserted from lateral to medial, using the interlocking alignment device, and when necessary, intraoperative fluoroscopy; wound was closed with nonadsorbable suture material (ethylon 2.0) with drain placed in situ Below-knee slab was applied for the immobilization.

### **Follow up**

Patient was made to walk the next day with the walker and full weight bearing after 6 weeks and was advised calf muscle building exercises. After two weeks post operative all the sutures were removed and healing was satisfactory. After six weeks patient was ambulating without support and could negotiate the stairs.

### **III. Discussion**

The goals of ankle arthrodesis are relief of pain and deformity and the development of a solid fusion. Numerous techniques and instrumentation devices have been described and created to achieve these goals. The authors believe that intramedullary nailing is an excellent method of fixation for arthrodeses of neuropathic joint (ANJ). In a German text entitled "The Practice of Intramedullary Nailing," published in the 1940s and 1950s, Küntscher [10] described a method of combined arthrodesis of the ankle and subtalar joints [14]. He employed a technique of closed medullary nailing with a conical nail inserted over a guide pin through the sole of the foot. He felt that extensive destruction of the joint and nailing should be done simultaneously. He used a 12 to 14 mm nail to achieve an interference fit, and no locking of the nail was done. The patients were kept at bed rest for 3 weeks and then ambulated in plaster. In 1979, Tomeno and Danan [15] presented 45 ankle arthrodeses using various fixation techniques, but with a fairly high infection rate. These authors had an 80% consolidation rate. Russotti et al [16] reported on 21 tibio-talocalcaneal arthrodeses employing Steinmann pins and external fixation. They had radiographic union in 86% with satisfactory results in 75% employing a posterior Achilles-splitting approach

Papa and Myerson [17] published a series of 21 pantalar and tibiotalocalcaneal arthrodeses for osteoarthritis. They achieved an 86% fusion rate using a transfibular approach with cannulated screws. These authors also had two patients who underwent ANJ in a neuropathic fusion series. Both these patients fused in under 5 months using a cannulated screw technique. Johnson and Gehrke returned to using an intramedullary nail for tibiotalocalcaneal fusion in a presentation given at the 1993 Summer Meeting of the AOFAS. They positioned the patient prone and used an Achilles-splitting approach, but they claimed that the technology in using the nail was more involved than other established techniques, and that the long-term results were not known as yet. The Richards supracondylar nail was initially designed to aid in the fixation of supracondylar femur fractures and is available in a variety of lengths and diameters. A special order ankle fusion nail, in which some of the locking holes that would be present near the arthrodesis sites are eliminated, is now under investigation. In this case we have approached debridement and fusion of the ankle joint with trans calcaneal interlocking nail fixation for. It achieved an overall good union at a mean time of 8 weeks.

### **IV. Conclusion**

Amputation of the limb which was the mainstay of treatment in olden days has been now rendered obsolete by the new technique of trans calcaneal interlocking nail. It has shown good results and also saves the limb of the patient.

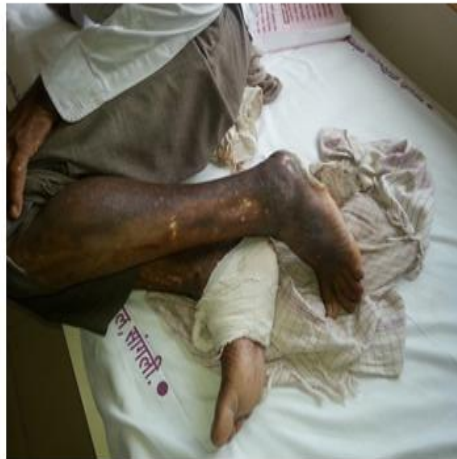### **References**

- [1]. Charcot JM. Sur quelques arthropathies qui paraissent dépendre d'une lésion due au cerveau ou de la moelle épinière. *Arch Physiol Norm et Pathol.* 1868; 1:161-78.
- [2]. Jacobs RL, Karmody A. Charcot foot. In: Jahss MH, editor. *Disorders of foot.* Vol. 2. Philadelphia: WB. Saunders; 1982. pp. 1248-65.
- [3]. Cofield RH, Morrison MJ, Beabout JW. Diabetic neuroarthropathy in the foot: Patient characteristics and patterns of radiographic change. *Foot Ankle.* 1983;4:15-22.
- [4]. Miller DS, Lichman WF. Diabetic neuropathic arthropathy of feet; Summary report of 15 cases. *AMA Arch Surg.* 1955; 70:513-8.
- [5]. Sanders LJ, Mrdjenovich D. Anatomical pattern of bone and joint destruction in neuropathic diabetes. *Diabetes.* 1991; 40:529A.
- [6]. Pohjolainen T, Alaranta H. Epidemiology of lower limb amputees in Southern Finland in 1995 and trends since 1984. *Prosthet Orthot Int.* 1999; 23:88-92.
- [7]. Stone NC, Daniels RT. Midfoot and hindfoot arthrodesis in diabetic Charcot arthropathy. *Can J Surg.* 2000; 43:449-55.
- [8]. Bono JV, Roger DJ, Jacobs RL. Surgical arthrodesis of the neuropathic foot. A salvage procedure. *Clin Orthop Relat Res.* 1993; 296:14-20.
- [9]. Papa J, Myerson M, Girard P. Salvage, with arthrodesis, in intractable diabetic neuropathic arthropathy of the foot and ankle. *J Bone Joint Surg Am.* 1993; 75A:1056-66.
- [10]. Kile TA, Donnelly PA, Gehrke JC, Werner ME, Johnson KA. Tibiotalo-calcaneal arthrodesis with an intramedullary device. *Foot Ankle.* 1994; 15:669-73.
- [11]. Anderson R. Concentric arthrodesis of the ankle joint. *J Bone Joint Surg.* 1945; 27:37.

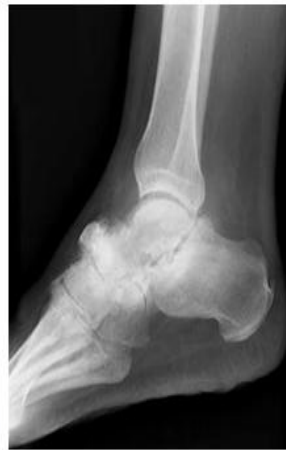## Treatment of Arthrodesis of Neuropathic Joint By Trans Calcaneal Interlocking Nail: A Case Report

- [12]. Barr JS, Record EE. Arthrodesis of the ankle joint. Indications, operative technique and clinical experience. N Eng J Med. 1953; 248:53-6.
- [13]. White AA., 3rd A precision posterior ankle fusion. Clin Orthop Relat Res. 1974; 98:239.
- [14]. Küntscher, G.: Combined Arthrodesis of the Ankle and Sub-talar Joints, in Practice of Intramedullary Nailing. Charles C. Thomas: 207-209, 1967.
- [15]. Tomeno B, Arama T. Combined arthrodesis of tibiotalar and subtalar joints (transtalar approach using a trephine. Rev Chir Orthop Reparatrice Appar Mot. 1986; 72:147-9
- [16]. 16. Russotti GM, Johnson KA, Cass JR. Tibiotalocalcaneal arthrodesis for arthritis and deformity of the hind part of the foot. J Bone Joint Surg Am 1988; 70:1304-7.
- [17]. Papa JA, Myerson MS. Pantalar and tibiotalocalcaneal arthrodesis for post-traumatic osteoarthritis of the ankle and hindfoot. J Bone Joint Surg Am 1992; 74:1042-49
- [18]. 18. Johnson KA, Gehrke JC. Intramedullary fixation for ankle arthrodesis. Proceedings of the Annual Summer Meeting of the American Orthopaedic Foot and Ankle Society. 1993

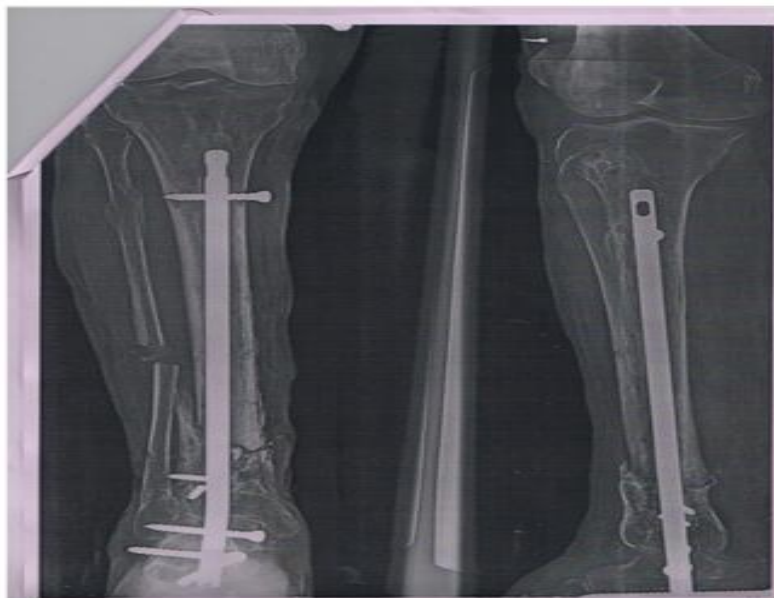
**Fig 1A**



**Fig 1B**



**Fig1:** Preoperative photograph and X-ray of the present case.



**Fig 2:** Post operative X-ray of the present case.

\*Dr. William Isapure. "Treatment of Arthrodesis of Neuropathic Joint By Trans Calcaneal Interlocking Nail: A Case Report." IOSR Journal of Dental and Medical Sciences (IOSR-JDMS) 16.9 (2017): 01-03.