

A Rare Case of Isolated Traumatic Perforation of Meckel's Diverticulum

*Dr. R. Jayakumar¹, Dr. D.N. Renganathan², Dr. Radhika R³, Dr. Mohamed Fayiz.P.T⁴, Dr. Balaji D.J⁵, Dr. Sathish Kumar J⁶, Dr. Muhammed Owaise J⁷,
Dr. A. Balamurugan⁸

Corresponding author: *Dr. R. Jayakumar

Abstract: We are presenting a rare case of isolated traumatic perforation of meckel's diverticulum which was identified incidentally during our emergency laparotomy on a patient who presented to our hospital trauma ward as a case of blunt injury abdomen by means of assault. Isolated traumatic perforation of meckle's diverticulum is a very rare entity which is usually detected incidentally during surgery. The treatment of this condition is Primary resection and anastomosis of meckel's diverticulum and adjacent small bowel. The post operative period of the patient was un-eventful and the patient was discharged after he was treated conservatively with Intra-venous antibiotics, Analgesics and daily wound care. The patient was discharged on the fifth post operative day without any post operative complications.

Keywords : meckel's diverticulum, resection, emergency

Date of Submission: 02 -08-2017

Date of acceptance: 23-08-2017

I. Introduction

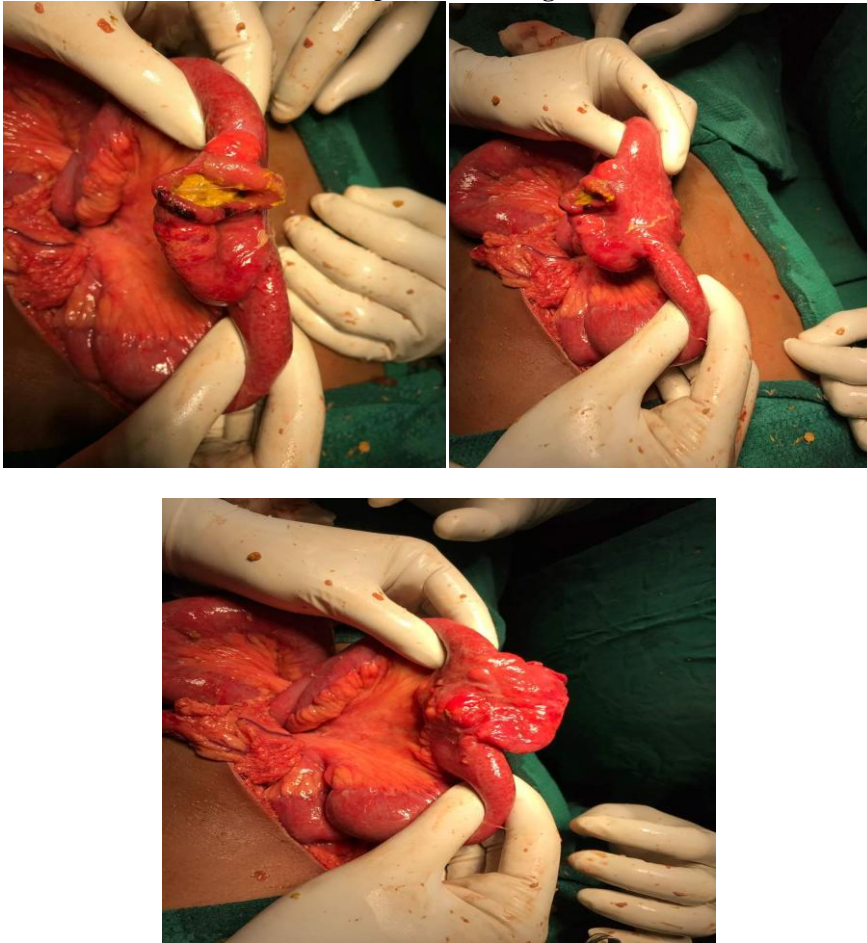
Meckel's diverticulum is the most common congenital anomaly of the small intestine occurring due to an incomplete obliteration of the vitello-intestinal duct. It is seen in about 2% of the population with a lifetime complication rate of 4 percent. It is vulnerable for the following complications: Hemorrhage, obstruction, inflammation, and perforation. Factors associated with increased risk of complications include male sex, age below 50 years, presence of heterotrophic mucosa within the diverticulum, length of diverticulum greater than 2 cm, or a diverticulum height to diameter ratio of greater than 2. Diagnostic laparoscopy plays a major role in the diagnosis and management of any type of abdominal injury. The importance of Diagnostic laparoscopy in abdominal injury and the incidence of Meckel's diverticulum which underwent a perforation following a Blunt abdominal injury is a rare event. In the literature, it has been found that the Meckel's diverticulum injury commonly occurs because of swallowed sharp objects. Meckel's diverticulum perforation should be treated as similar to a case of small intestinal perforation. The patient should be taken up for emergency laparotomy after performing the initial primary investigations. The patients are treated similar to a post laparotomy patients with intravenous antibiotics and analgesics. Oral feeds are usually started on post operative day – 3. The patients are usually followed up weekly after suture removal on the 7th post operative day.

II. Case Report

A 23YRS old male patient Thangam presented with the chief complaints of alleged h/o assault by one known person at 3:00 AM on 6/6/2017 at palayur M.G.R Nagar by use of bare hands. Patient presented with the chief complaints of abdominal pain to trauma ward. Primary examination of the patient was found to be within normal limits. Per abdominal examination of the patient reveals diffuse tenderness with guarding and rigidity. X-ray Chest – PA view and X-ray Abdomen erect AP view showed Bilateral Air under Diaphragm. Ultrasound Abdomen and Pelvis revealed minimal free fluid in the pelvis. Patient was provisionally diagnosed as Perforative Peritonitis following which the patient was planned for Emergency laparotomy and proceed after initial investigations which was done in our hospital and were found to be within normal limits.

Blood sugar- 76mg/dl. Blood urea – 28mg/dl. Serum creatinine -1.0mg/dl. Serum sodium- 138meq/l. Serum potassium -3.8 meq/l. Serum amylase – 70iu/l. Hemoglobin- 14gm/l. RBC : 6.16 lakhs/ cu.mm. WBC : 6300 cells/ cu.mm. VCTC : non reactive. ECG : NORMAL One unit of packed red cells was reserved. Informed high risk consent was obtained from the patient's attenders. Patient was shifted to the emergency operation theatre.

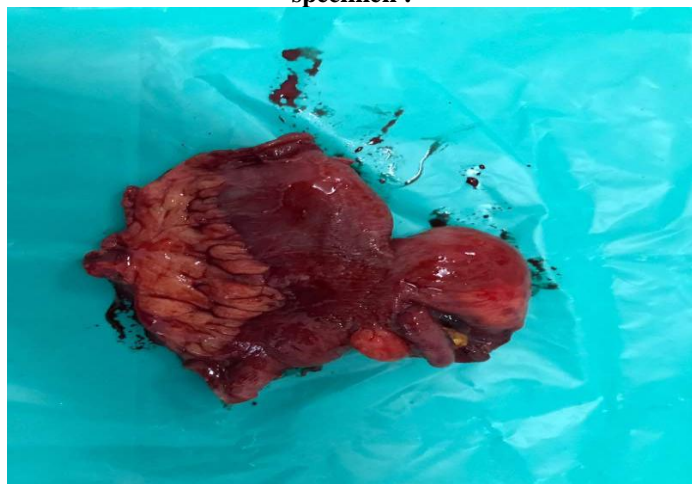Intra-operative findings :



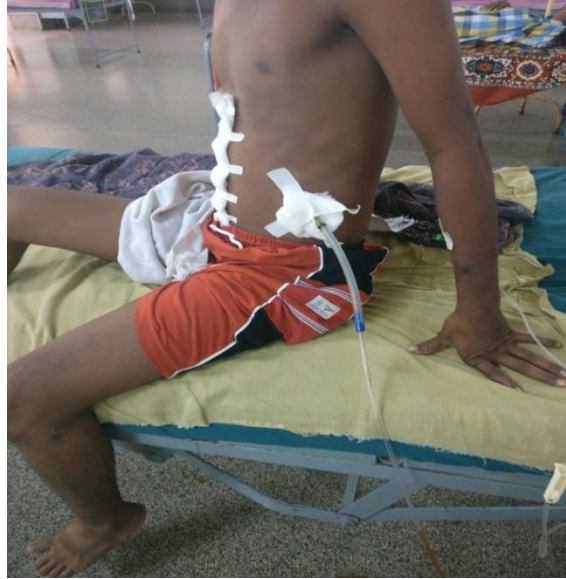2x2 cm perforatio at meckel's diverticulum 60 cm proximal to ileocecal junction with prolapsed mucosa. About 1 litre of feculent peritoneal fluid is found. Other solid organs are found to be normal. Following which resection and anastomosis of the Meckel's diverticulum with adjacent ileum of about 5 cm. Two layers of sutures were used , Inner vicryl and outer silk sutures. Mesenteric defect was closed with silk sutures. Anastamostic site was covered with omental patch. Two drains inserted . One drain is kept in morrison's pouch and another in the pelvic cavity.

Post operatively patient is managed with nil per oral , intra venous fluids , intravenous antibiotics , analgesics, antacids and with charting of blood pressure , temperature / pulse rate / respiratory charting and with Input output charting.

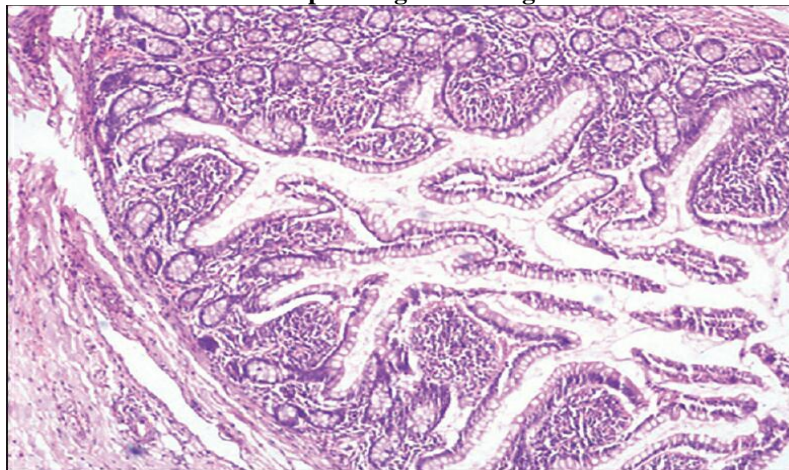
specimen :



Post operative picture :



Histopathological findings:




All three layers of bowel wall seen. Intestinal mucosal glands containing paneth cells are seen. Lymphoid aggregates are seen within the the layers. Fibrotic changes seen in the wall indicating perforation/ chronic inflammation. No ectopic tissues seen.

III. Discussion

Isolated Meckel's diverticulum perforation is a rare entity. In literature , the case reports of isolated traumatic meckel's diverticular perforation is a very rare entity. We are presenting this case report for its rarity as per the current reports and statistics. The treatment and surgical part of isolated meckel's diverticular perforation is similar to the treatment of small intestinal perforation without any changes. The post operative management is also similar. The prognosis of this patient was good without any post operative morbidity.

References

- [1]. Turgeon DK, Barnett JL. Meckel's diverticulum. *Am J Gastroenterol.* 1990;85:777-781.
- [2]. Elsayes KM, Menias CO, Harvin HJ, Francis IR (July 2007). "Imaging manifestations of Meckel's diverticulum". *AJR Am J Roentgenol.* **189** (1): 81–8. PMID 17579156. doi:10.2214/AJR.06.1257.
- [3]. J. F. Meckel. Über die Divertikel am Darmkanal. *Archiv für die Physiologie, Halle,* 1809, 9: 421–453.
- [4]. Schoenwolf, G. C., & Larsen, W. J. (2009). *Larsen's human embryology* (4th ed.). Philadelphia: Churchill Livingstone/Elsevier.
- [5]. F. Charles Brunicaudi, Dana K. Anderson, Timothy R. Billiar, et al. Small Intestine. In: Ali Tavakkoli, Stanley W. Ashley, Michael J. Zinner: *Schwartz's Principles of Surgery.* 10 ed. United states: McGraw-Hill;2015
- [6]. Tan, Y. M., & Zheng, Z. X. (2005). Recurrent torsion of a giant Meckel's diverticulum. *Digestive Diseases and Sciences,* 50(7), 1285–1287.
- [7]. Sharma R.; Jain V. (2008). "Emergency surgery for Meckel's diverticulum". *World J Emerg Surg.* **3** (27): 1–8. doi:10.1186/1749-7922-3-27.
- [8]. Al-Onaizi I; Al-Awadi F; Al-Dawood A. L. (2002). "Iron deficiency anaemia: An unusual complication of Meckel's diverticulum". *Medical Principles and Practice : International Journal of the Kuwait University, Health Science Centre.* **11** (4): 214–217. doi:10.1159/000065810.

- [9]. Johnston A. O.; Moore T. (1976). "Complications of Meckel's diverticulum". *British Journal of Surgery Society Ltd.* **63** (6): 453–454. doi:10.1002/bjs.1800630612.
- [10]. Tauro LF, George C, Rao BS, Martis JJ, Menezes LT, Shenoy HD (2010). "Asymptomatic Meckel's diverticulum in adults: is diverticulectomy indicated?". *Saudi J Gastroenterol.* **16** (3): 198–202. PMC 3003224 . PMID 20616416. doi:10.4103/1319-3767.65199.
- [11]. Martin JP, Connor PD, Charles K (February 2000). "Meckel's diverticulum". *Am Fam Physician.* **61** (4): 1037–42, 1044. PMID 10706156.

*Dr. R. Jayakumar. " A Rare Case of Isolated Traumatic Perforation of Meckel's Diverticulum." *IOSR Journal of Dental and Medical Sciences (IOSR-JDMS)* 16.8 (2017): 76-79