

PAOO- Systematic Review Of Case Reports

*Dr.Mrugank Vyas¹,Dr.Monali Shah²,Dr.Deepak Dave³,Dr.Yesha shroff⁴.

¹(post graduate student ,Department of periodontology, k M Shah Dental College/Sumandeep vidyapeeth, India)

²(Professor ,Department Department of periodontology, k M Shah Dental College/Sumandeep vidyapeeth,India)

³(Professor and Head, Department Department of periodontology, k M Shah Dental College
Sumandeep vidyapeeth, India)

⁴(post graduate student ,Department of periodontology, k M Shah Dental College/Sumandeep vidyapeeth, India)

Corresponding author: *Dr. Mrugank Vyas

Abstract: Recently, there has been a rise in the number of adult patients looking for orthodontic treatment with requirements regarding the duration of treatment and esthetics. Periodontally accelerated osteogenic orthodontics (PAOO) or Wilckodontics is a clinical procedure that combines selective alveolar corticotomy, particulate bone grafting, and the application of orthodontic forces. This procedure is theoretically based on the bone healing pattern known as the regional acceleratory phenomenon(RAP). PAOO results in an increase in alveolar bone width, shorter treatment time, increased posttreatment stability, and decreased amount of apical root resorption.

Keywords: Wickodontics, Alveolar Bone, Regional Acceleratory Phenomenon, Corticotomy.

Date of Submission: 03 -08-2017

Date of acceptance: 18-08-2017

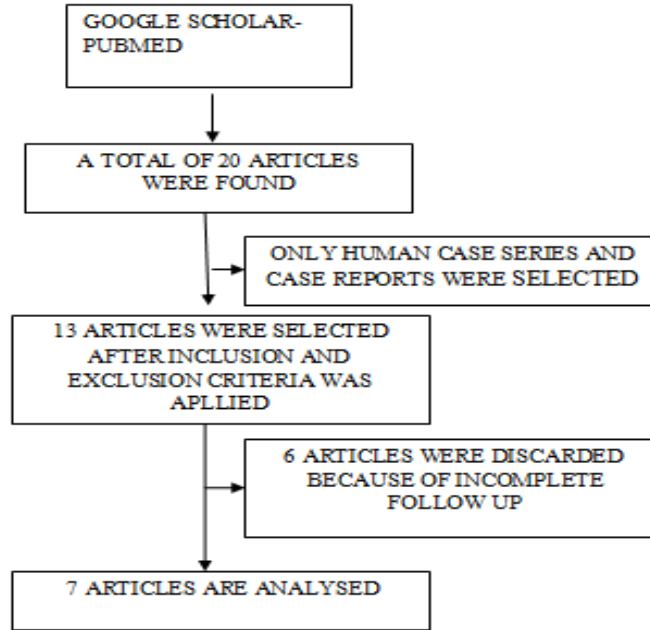
I. Introduction

Periodontally accelerated osteogenic orthodontics (PAOO) is also known as Wilckodontics. It is a relatively new treatment modality which opens the door for successful adult orthodontics and drastically reduces the time taken to complete orthodontic treatment with fewer complication[1]. This approach highlights the synergistic effects of two dental fields, orthodontics and Periodontics to improve the overall treatment of the patient[2]. It is a clinical procedure that combines selective alveolar corticotomy, use of bone grafts and the application of orthodontic tooth movements[3]. The concept of surgically assisted orthodontic tooth movement has been studied since the 1800's[4]. In 1893, L.C.Bryan was the first to describe that corticotomy facilitated tooth movement. Henrich Kole in 1959 emphasized that most resistance to tooth movement was caused by the continuity and thickness of the dense cortical bone[5]. In 1975, Duker conducted a study to determine the effect of corticotomy on tooth vitality and the marginal periodontium[6]. He concluded that the marginal bone should be preserved and the interdental cuts should be made at least 2 mm apical to the alveolar crest level. Technique was further modified by Wilcko et al. They added the concept of alveolar augmentation to corticotomy assisted orthodontic technique and patented the procedure as Periodontally accelerated osteogenic orthodontics (PAOO)[7].

It is based on the principle of Regional Acceleratory Phenomenon (RAP). RAP was first described by Herald Frost in 1983[8].Frost recognized that original injury resulted in accelerated normal regional healing process. RAP was described as a local response of the tissue to a noxious stimuli resulting in accelerated regional regeneration process. This response was directly related to the size, duration, intensity and magnitude of the stimuli. Accelerated bone turnover and decreased regional bone density are two main features of RAP which play a major role in orthodontics tooth movements and play important role for rapid orthodontic tooth movement[9].

II. Searching

A hand search was made in Google scholar and PUBMED using Wilckodontics, Periodontally Accelerated Osteogenic Orthodontics (PAOO), Orthodontic tooth movement, Regional Acceleratory Phenomenon, Corticotomy, Alveolar corticotomies keywords. 20 relevant articles were found. Out of which only human case series and case reports were selected. After applying inclusion and extrusion criteria 13 articles were selected. Out of these 13 articles 7 were discarded due to incomplete follow up. Finally 7 studies are analysis in this article.



(FIGURE -1)

Similarities, differences and follow up of included case-reports were tabulated.

III. Results

Author	Similarity	Follow Up	Difference	Result
Mahantesha S Et Al. 2017	Corticotomy Was Done Followed By Placement Of Bone Graft Assisted With Orthodontic Treatment.	Case-I 4 Month. Case-Ii 5 Month.	Angle’s Class 1 Malocclusion With Maxillary And Mandibular Prognathism.	Periodontally Accelerated Osteogenic Orthodontics (PAOO) Technique Is A Combination Of A Selective Decortications Facilitated Orthodontic Technique And Alveolar Augmentation.
Eshan Awasthi Et Al. 2016	Corticotomy Including Vertical Cuts Joined By Horizontal Cuts Was Performed Followed By Orthodontic Treatment.	4 Month.	Anterior Open Bite.	The Modified Decortication Technique Reduced The Treatment Time To A Considerable Extent. The Interdental Spacing Closed And Optimum Overjet And Overbite Was Achieved.
Karant Et Al. 2016	Corticotomy-Assisted Rapid Orthodontic Procedure Known As Periodontically Accelerated Osteogenic Orthodontics (PAOO) With Bone Graft Placement Was Done.	2 Month.	Angles Class I Malocclusion.	PAOO Is A Promising Technique That Has Several Applications In The Orthodontics Treatment Of Adults Because It Helps To Overcome Many Of The Current Limitation Of Adult Orthodontic Treatment, The Most Important Being The Lengthy Duration And The Potential For Periodontal Complications.
Swaroop Et Al. 2015	Corticotomy –Assisted Rapid Orthodontic Procedure Known As Periodontically Accelerated Osteogenic Orthodontics (PAOO) With Bonegraft Placement Was Done.	4 Month.	Crowding Of Upper And Lower Anteriors	The Orthodontic Treatment Time is Reduced To One-Third Of That Of The Conventional Technique.

Raja Et Al. 2014	Corticotomy –Assisted Rapid Orthodontic Procedure Known As Periodontically Accelerated Osteogenic Orthodontics (PAOO) With Bone Graft Placement Was Done.	2 Month	Angles Class I Malocclusion.	A Dramatic Reduction In The Time Of Orthodontic Treatment From 31 To 16 Month Was Observed.
Nowzari Et Al. 2008	Corticotomy-Assisted Rapid Orthodontics Procedure Known As Periodontically Accelerated Osteogenic Orthodontics (PAOO) With Bone Graft Placement Was Done.	8 Month	Angles Class Ii, Division Ii Malocclusion.	No Detrimental Periodontal Effect Or Root Resorption Were Observed. The Alveolar Ridges Of Both Maxilla And Mandible Maintained The Original Thickness And Configuration Despite Tipping Of The Incisors. Orthodontic Results Obtained In One-Third The Average Time.
Wilcko Et Al Et Al. 2001	Corticotomy Was Done Followed By Placement Of Bone Graft Assisted With Orthodontic Treatment.	Case-I 8.5 Month. Case-Ii 8 Month.	Angles Class I Malocclusion.	Viable And Safe Orthodontic Treatment That Can Be Completed In A Fraction Of The Time Required For Conventional Orthodontics. With Surgical Intervention, An Osteoporotic Situation That Is Favourable For Rapid Orthodontic Tooth Movement Can Be Induced Within The Alveolar Bone Without Increasing The Risk Of Apical Root resorption. The Alveolar Bone Can Be Simultaneously Augmented And Reshaped.

IV. Discussion

The procedure of Wilckodontics is advantageous than the conventional orthodontic treatment as it takes lesser time to achieve the results. There is less evidence of root resorption and history of relapse. It has been claimed that orthodontic treatment progresses faster and the results are more stable after corticotomy with minimal risk of complications.[10] Corticotomy with subsequent bone augmentation has been proposed to increase the volume of the alveolar process, to facilitate arch development, to prevent and treat fenestrations, and to maximize the metabolic response during orthodontic treatment.[11] Corticotomy-facilitated orthodontics has been indicated for non-extraction treatment of crowding, shortening treatment duration, extrusion of ankylosed teeth, intrusion of posterior teeth to close anterior open bites and impacted canines.[12] Contraindications include patients with severe active periodontal disease, inadequately treated endodontic problems, patients on long term medications which will slow down bone metabolism, such as bisphosphonate and NSAIDs and patients on long term steroid therapy due to presence of devitalized areas of bone and patients with inadequate width of attached gingiva.[13] The effects of Alveolar corticotomies on the acceleration of tooth movement were documented in rats, dogs, cats and humans based on split mouth study designs.

The outcome of these experiments show that the rate of tooth movement is doubled on the corticotomy treated site (about 1mm/month).[14] Generson et al described rapid orthodontic treatment for open bite malocclusion in 1978 using alveolar decortication without subapical osteotomy.[14] This modified surgical procedure was reported in 1991 and was referred to as corticotomy facilitated orthodontics.[15] In 1991, Suya reported surgical orthodontic treatment of 395 adult japanese patients with an improved surgical procedure that he referred to as corticotomy facilitated orthodontics. Suya’s surgical technique differed from Kole’s with the substitution of supra-apical corticotomy cut in place of horizontal osteotomy cut beyond the apices of the teeth. Suya contrasted this technique with conventional orthodontics.

This technique was found to be less painful, producing less root resorption and relapse. He recommended completing the major active tooth movements in 3-4 months[16]. In 1986, Anholm et al reported treatment of severe malocclusion using corticotomy facilitated orthodontics[17].

Kanno et al described a corticotomy procedure used to treat a case of severe open bite, moving the upper posterior bone– tooth segments 7 mm in a superior position. They used anchor plates and elastics three weeks after surgical intervention in two stages. Satisfactory results were obtained after 6 months of orthodontic treatment[18]. Dibart et al described a tunnel approach with piezoelectric bone cuts. Several vertical incisions are distributed on the attached gingiva through piezo-electric vertical corticotomies. The tunneling approach allows placement of the bone graft. A case of mild crowding was solved within 17 weeks of active treatment with this approach[19]. Studies (Sanjideh et al., 2010) comparing the rate of tooth movement showed that the tooth movement peaked at 22-25 days and then decelerated. During this three week period, corticotomy facilitated side moved twice than the control side[20]. Similar results were obtained in a study[21] conducted in adults to retract maxillary canines following premolar extractions. Based on the outcome of these studies the length of RAP was probably four months, after which the rate of tooth movement returns to normal.

Studies have shown that corticotomy shortens the treatment time. However, one cannot measure treatment time without measuring treatment quality. The American Board of orthodontics has developed a detailed grading system to assess the quality of orthodontic treatment.[22] Yet to date there are no RCT's focusing on this aspect of corticotomy. In support of Wilcko's concept, published data claims that bone grafting enhances the stability of orthodontic treatment results. Some cases report a greater volume of bone in Computed tomographic Scans. However is the new bone incorporated into native cortical –plate, or is it fibro osseous material encapsulated on the outside of the cortical plate was evaluated. The scans suggest that it is a fibro osseous encapsulation. Moreover a distinct disadvantage of this procedure is the additional cost, invasive nature and morbidity associated with the surgery.[23]

V. Conclusion

The procedure of Wilckodontics has made adult orthodontics a reality. The treatment can be accomplished within a shorter period of time which is attributable to the Regional Acceleratory Phenomenon (RAP). The use of this procedure avoids secondary effects of conventional orthodontic treatment such as root resorption or periodontal dehiscence. This technique also shows increased alveolar thickness due to the inclusion of bone grafts, better post orthodontic stability and less incidence of root resorption when compared to conventional orthodontic treatment. As Wilckodontics is a relatively newer procedure long term follow up studies with increased sample size are required to further authenticate this procedure into surgical orthodontics.

References

- [1]. Vig PS. The duration of orthodontic treatment with and without extractions: a pilot study of five selected practices. *Am J Orthod Dentofacial Orthop.*1990; 45-51.
- [2]. Reitan K. Biomechanical principles and reactions. In: Graber TM and Swain BF. *Orthodontics: Current Principles and Techniques*". St. Louis, MO: C.V. Mosby Company 1985;101-192.
- [3]. Wilcko MT. Accelerated osteogenic orthodontics technique: a 1-stage surgically facilitated rapid orthodontic technique with alveolar augmentation. *J Oral Maxillofac Surg* 2009; 2149-2159: 67.
- [4]. Guilford SH. *Orthodontia: Or Malposition of the Human Teeth, Its Prevention and Remedy*". Philadelphia, PA: Spangler and Davis 1893.
- [5]. Köle H. Surgical operations on the alveolar ridge to correct occlusal abnormalities. *Oral Surg Oral Med Oral Pathol* .1959; 515-529:12.5.
- [6]. DukerJ. Experimental animal research into segmental alveolar movement after corticotomy. *J Oral Maxillofac Surg* 1975; 81-84:3.
- [7]. Wilcko WM. Rapid orthodontics with alveolar reshaping: two case reports of decrowding. *Int J Periodontics Restorative Dent.* 2001; 9-19:21.1.
- [8]. Frost HM. The regional acceleratory phenomenon: a review. *Henry Ford Hosp Med J.*1983; 3-9:31.
- [9]. Wilcko WM. Rapid orthodontic de crowding with alveolar augmentation: case report. *World J Orthod.*2003; 197-205:4.
- [10]. Keole, H. Surgical operations on the alveolar ridge to correct occlusal abnormalities. *Oral Surg Oral Med Oral Pathol.*1959; 12:515:29.
- [11]. Wilcko, W.M., Wilcko, M.T., Bouquot, J.E. Rapid orthodontics with alveolar reshaping: two case reports of decrowding. *Int J Periodontics Restorative Dent.*2001; 21:9:19.
- [12]. Eelke, J. Hoogveen. Surgically facilitated orthodontic treatment: A systematic review. *Am J Orthod Dentofacial Orthop.*2014; 51-64:145.
- [13]. Pan Chern Hwei. Role of periodontal therapy in Rapid tooth movement. *IOSR J Dent Med Sci.*2014;13, (2) :62-65.
- [14]. Sirisha, K. 2014. Wickodontics- anovel synergy to save time. *J Clin Diagn Res.* 2014; 8(1):322-325
- [15]. Generson, R.M., Porter, J.M., Stratigos, G.T. Combined surgical and orthodontic management of anterior open bite using corticotomy. *J Oral Surg.*1978; 36: 216–9.
- [16]. Suya, H. Corticotomy in orthodontics. In Hosl E, Baldauf A (eds), *Mechanical and biological basis in orthodontic therapy.* Germany: Huthig Buch Verlag.1991;207- 26.
- [17]. Anholm, L., Crites, D., Hoff, R., Rathbun, E. Corticotomy – facilitated Orthodontics. *Calif Dent Assoc J.*1986; 7: 8-11.
- [18]. Kanno, T., Mitsugi, M., Furuki, Y., Kozato, S., Ayasaka, N., Mori, H. Corticotomy and compression osteogenesis in the posterior maxilla for treating severe anterior open bite. *Int J Oral Maxillofac Surg.*2007; 36:354-7.
- [19]. Dibart, S., Sebaoun, J.D., Surmenian, J. Piezocision: a minimally invasive, periodontally accelerated orthodontic tooth movement procedure. *CompendContinEduc Dent.*2009; 30: 342–50.

- [20]. Sanjideh, P.A., Rossouw, P.E., Campbell, P.M., Opperman, L.A., Buschang, P.H. 2010. Tooth movements in foxhounds after one ortho alveolar corticotomies. *Eur J Orthod.*2010; 32: 106-13.
- [21]. Aboul-Ela, S.M., El-Beialy, A.R., El-Sayed, K.M., Selim, E.M., El-Mangoury, N.H., Mostafa, Y.A. Miniscrew implant-supported maxillary canine retraction with and without corticotomy-facilitated orthodontics. *Am J Orthod Dentofacial Orthop.* 2011;139: 252-9.
- [22]. Casco, J., Vaden, J., Kokich, V. American Board of Orthodontics objective grading system for dental casts and panoramic radiographs. *Am J Orthod Dentofacial Orthop.*1998; 114: 589-99.
- [23]. Murphy, K.G., Wilcko, M.T., Wilcko, W.M., Ferguson, D.J. Periodontal accelerated osteogenic orthodontics: a description of the surgical technique. *J Oral Maxillofac Surg.* 2009;67: 2160-6.

*Dr.Mrugank Vyas. " PAOO- Systematic Review Of Case Reports." *IOSR Journal of Dental and Medical Sciences (IOSR-JDMS)* 16.8 (2017): 78-82