

## Orthodontic Extrusion A Simplistic Approach- Case Study

\*Dr. Kapil Fafat<sup>1</sup> (Private Practice) Dr. Vitam Mundra<sup>2</sup> (Private Practice)

<sup>1</sup>Former Sr. Lecturer VSPM Dental College and Hospital Nagpur

<sup>2</sup>College of Dental Science And Hospital Indore

Corresponding author: \* Dr. Kapil Fafat

**Abstract:** The management of patients with traumatic injuries to their dentition is an integral part of the general dental practice. Anterior teeth with fractures that extend subgingivally require a complex treatment plan that addresses biologic, esthetic, and functional factors, such as mastication and speech. Treatment of crown fractures often requires a multi-disciplinary approach. However, crown-root fractures with fracture line below the gingival attachment or alveolar bone crest present restorative difficulties. This case report presents a 24-year-old male who reported with fractured upper right lateral and central incisors and upper left central incisor following road accident. On clinical examination, it was observed that the upper right lateral incisor had a horizontal fracture at the cervical one-third level with the fracture line extending subgingivally, mid crown fracture of right central incisor and incisal fracture of left central incisor. All the traumatized teeth were first treated endodontically, and then for orthodontic extrusion before permanent crown placement.

**Keywords:** Anterior teeth, orthodontic extrusion, restorative difficulties, subgingival fracture, traumatic injuries

Date of Submission: 05 -08-2017

Date of acceptance: 18-08-2017

### Introduction

Traumatic injuries to the teeth in the esthetic region of the face pose a great challenge to the general as well as the restorative dentist. Since the gingival display of the upper anterior teeth contributes, the micro esthetics of the smile maintenance of this delicate contour is of prime importance. With the recent trend and attitude toward dental implants, extraction remains the common treatment modality. This, however, should be considered as the last option, and every attempt should be made to preserve and restore the natural tooth structure. Such treatment modalities involve a multi-disciplinary approach including endodontics, periodontal crown lengthening, and/or orthodontic extrusion followed by prosthetic rehabilitation. Periodontal crown lengthening involves the removal of supporting crestal alveolar bone while orthodontic intervention forcibly extrudes the tooth. Both are attempts to expose sufficient coronal tooth structure for proper prosthetic restoration. Crown lengthening procedures may expose excess of root and in turn, may compromise esthetic results that can be avoided by the use of orthodontic extrusion.<sup>[1],[2],[3],[4]</sup>

Different methods of orthodontic extrusion of fractured teeth have been reported in literature which basically includes two principal approaches namely:

1. Using brackets and wires as part of fixed mechanotherapy.
2. Extending a rigid wire across the teeth neighboring the fractured tooth and applying traction forces to the fractured tooth through this attachment.

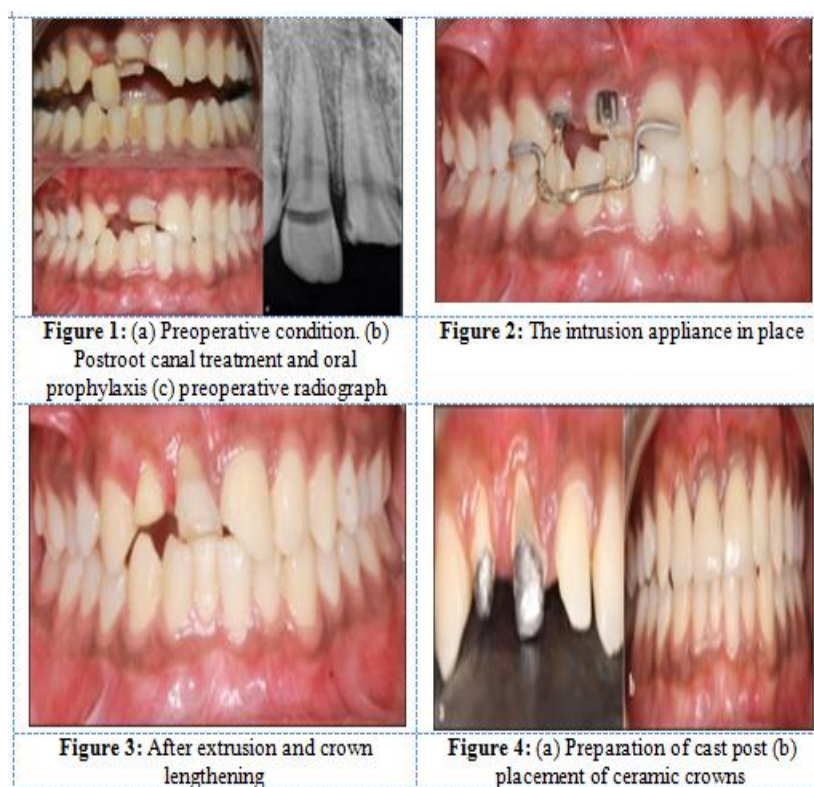
Orthodontic extrusion is usually achieved with fixed appliances. During orthodontic treatment, 20-30 g of force is required for extrusion.

The purpose of this paper was to review this multi-disciplinary treatment approach and to present a case of traumatized maxillary central and lateral incisors tooth with subgingival fracture and its management maintaining the healthy periodontal tissue and alveolar bone.

### III. Case Report

A 24-year-old male patient was referred to our clinic, with fractured upper right lateral and right and left central incisors following road accident. Clinical examination showed horizontal cervical fracture of upper right lateral and mid crown fracture of central incisor (nos. 11, 12) and oblique incisal fracture with exposed pulp tissue of upper left central incisor (no. 21) [Figure 1]. The fractured fragment of 12 attached to the soft tissue was subsequently removed. With patient's consent, root canal therapy was carried out immediately on the same appointment, and orthodontic extrusion was planned subsequently. After the tooth was asymptomatic for a week, rapid orthodontic extrusion was carried out [Figure 2].

Extrusion was done using a round 19 gauge rigid stainless steel stabilizing with soldered blobs placed on the wire. Based on the depth of the palatal fracture line, it was planned to extrude the tooth to about 3-4 mm. vertical bends were given in the wire to prevent rotation of the wire and to attain a larger length of elastic thread for adequate force generation. The wire was bonded to adjacent teeth (right no. 13 to left no. 21 teeth) using the composite restorative material. Begg brackets were bonded on 21 and 22. An elastic thread was stretched between the Begg brackets and the wire so that the thread seats between the blobs to avoid slipping of the elastic thread. A force of 35 g was applied which was measured using a Dontrix gauge. The elastic thread was changed every 15 days till the desired extrusion was obtained. The total extrusion was completed in 2 months. After the stabilization period, definitive coronal restoration was planned. After the stabilization period, crown lengthening was performed to restore the gingival contours [Figure 3] At this point, the remaining coronal structure was assessed, and it was judged to be adequate to retain a definitive full coverage restoration without any need for intra-radicular support. A cast post was prepared, and definitive ceramic crowns were placed over 11, 12, and 21 [Figure 4].



Patient was reviewed for 6 months, and the treatment outcome was stable and symptomless.

#### IV. Discussion

Movement of a tooth by extrusion involves applying tractional forces in all regions of the periodontal ligament to stimulate marginal apposition of crestal bone. Because the gingival tissue is attached to the root by connective tissue, the gingiva follows the vertical movement of the root during the extrusion process. Similarly, the alveolus is attached to the root by the periodontal ligament and is in turn pulled along by the movement of the root.<sup>[5]</sup> If the fracture line is positioned both below alveolar bone and gingival free margin, and if the length of the root segment is sufficient enough to support a coronal restoration, then the root can be endodontically treated and afterward, orthodontically extruded to elevate the fracture plane above the gingival margin. These procedures enable more favorable prosthodontic coronal restoration by securing its good sealing and esthetics, and moreover, preserving a good periodontal tissue health.<sup>[6]</sup> Forces of 15 g for the fine root of a lower incisor and 60 g for a molar are sufficient for slow extrusion. Some authors recommend that the maximum force for a slow movement should not exceed 30 g,<sup>[7],[8]</sup> whereas rapid extrusions are accomplished with forces higher than 50 g.<sup>[9]</sup> Rapid orthodontic extrusion is carried out at higher forces; hence, longer retention periods are required to stabilize the tooth for remodeling and adaptation of the periodontium to the newly acquired tooth position. Ulusoy *et al.*<sup>[10]</sup> and Fidel *et al.*<sup>[11]</sup> described a technique for extrusion using bonded brackets on the adjacent teeth. However, with bonded brackets, there is a necessity to align the anteriors and time will be lost as a result. Furthermore, reciprocal forces of intrusion might act on the adjacent teeth.

Murali *et al.*<sup>[12]</sup> suggested a lingual technique using STB brackets. The same forces of intrusion are evident here. Heda *et al.*<sup>[13]</sup> also suggested a similar technique using a bonded stainless steel wire. However, since no vertical steps were given for the extrusion, rolling of the wire was an issue. In the technique used for this case, vertical steps were given to prevent the rolling of the wire. Furthermore, no need for aligning the anteriors since the rigid wire could be bonded directly chair side. Readily available and cheap Begg brackets were used as attachments. Furthermore, the technique is so simple that even the general dentist can perform this procedure.

## V. Conclusion

A multi-disciplinary approach is necessary for the restoration of tooth fractured at a subgingival level because the margin of restoration should ideally be supragingival. In this clinical report, a treatment modality for forced eruption therapy that minimizes treatment time and increases ease of use was described. The use of this technique for forced eruption may help the general dentist to have a better esthetic result and better patient appreciation.

## References

- [1]. Delivanis P, Delivanis H, Kuflinec MM. Endodontic-orthodontic management of fractured anterior teeth. *J Am Dent Assoc* 1978;97:483-5.
- [2]. Johnson RH. Lengthening clinical crowns. *J Am Dent Assoc* 1990;121:473-6.
- [3]. Ivey DW, Calhoun RL, Kemp WB, Dorfman HS, Wheeler JE. Orthodontic extrusion: Its use in restorative dentistry. *J Prosthet Dent* 1980;43:401-7.
- [4]. Fournier A. Orthodontic management of subgingivally fractured teeth. *J Clin Orthod* 1981;15:502-3.
- [5]. Bach N, Baylard JF, Voyer R. Orthodontic extrusion: Periodontal considerations and applications. *J Can Dent Assoc* 2004;70:775-80.
- [6]. Bielicka B, Bartkowiak M, Urban E, Tomasz M. Holistic approach in the management of subgingivally fractured premolar tooth: Case report. *Dent Med Probl* 2008;45:211-4.
- [7]. Minsk L. Orthodontic tooth extrusion as an adjunct to periodontal therapy. *Compend Contin Educ Dent* 2000;21:768-70.
- [8]. Reitan K. Clinical and histologic observations on tooth movement during and after orthodontic treatment. *Am J Orthod* 1967;53:721-45.
- [9]. Bondemark L, Kurol J, Hallonsten AL, Andreasen JO. Attractive magnets for orthodontic extrusion of crown-root fractured teeth. *Am J Orthod Dentofacial Orthop* 1997;112:187-93.
- [10]. Ulusoy A. Indirect composite restoration of a crown fracture. *J Dent Child* 2012;79:2.
- [11]. Fidel SR, Fidel-Junior RA, Sassone LM, Murad CF, Fidel RA. Clinical management of a complicated crown-root fracture: A case report. *Braz Dent J* 2011;22:258-62.
- [12]. Murali RV, Rajashekhar L, Rajalingam S. Extrusion of fractured anterior tooth - An invisible approach. *Indian J Multidiscip Dent* 2011;1.
- [13]. Heda CB, Heda AA, Kulkarni SS. A multi-disciplinary approach in the management of a traumatized tooth with complicated crown-root fracture: A case report. *J Indian Soc Pedod Prev Dent* 2006;24:197-200.
- [14]. Forced orthodontic extrusion for anterior traumatized teeth by a simplistic approach [jdas.in/article.asp?issn=2277-4696;year=2014;volume=3;issue=2](http://jdas.in/article.asp?issn=2277-4696;year=2014;volume=3;issue=2)

\*Dr. Kapil Fafat. "Orthodontic Extrusion A Simplistic Approach- Case Study." *IOSR Journal of Dental and Medical Sciences (IOSR-JDMS)* 16.8 (2017): 66-68