

Smile Rehabilitation of Bilaterally Missing Maxillary Lateral Incisors: An Interdisciplinary Approach

*Dr.Falguni Mehta¹,Vidhi Tyagi²,Meera Nair³,Sneha Suman⁴,Puja Maru⁵

¹(Prof. and HOD, Dept of Orthodontics and Dentofacial Orthopaedics, GDCH, Ahmedabad, India)

^{2,3,4,5}(Post Graduate Student, Dept of Orthodontics and Dentofacial Orthopaedics, GDCH, Ahmedabad, India)

Abstract : Congenitally missing lateral incisors are a frequently seen anomaly leading to an unpleasant smile. Reduced tooth material also causes a problem for establishing a functional occlusion. Management of such cases often requires an interdisciplinary approach. This case report describes management of congenitally missing maxillary lateral bilaterally with prosthetic replacement after creating space orthodontically.

Keywords: bilateral, congenitally, interdisciplinary, lateral incisors, missing

Date of Submission: 21 -04-2017

Date of acceptance: 18-08-2017

I. Introduction

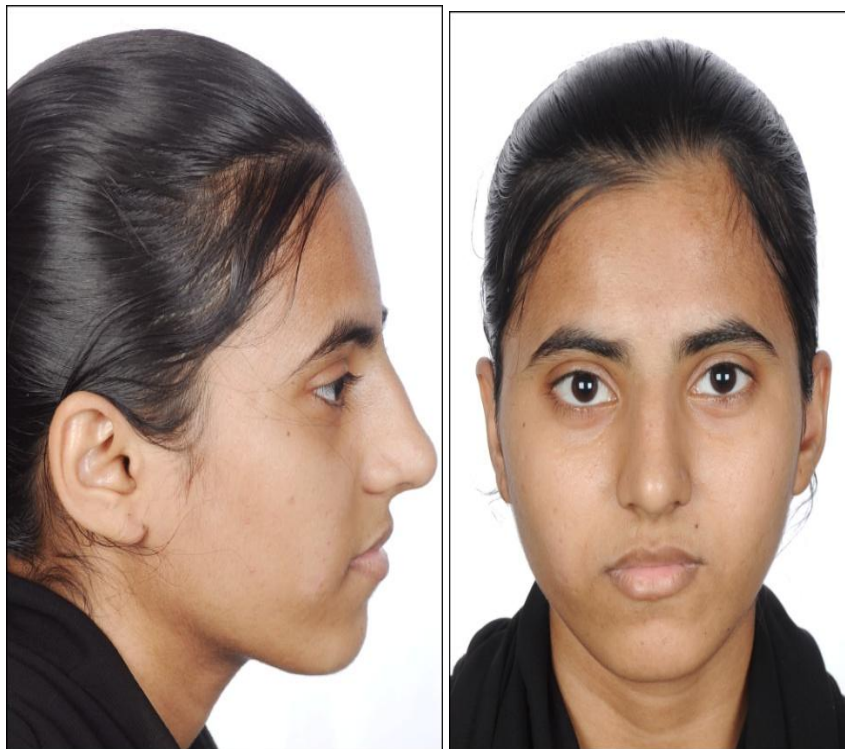
Missing maxillary lateral incisors are the second most common form of teeth agenesis after third molars.[1,2] A developmental disturbance in the process of embryonic fusion in the area of the median nasal process, similar to that seen in clefts, has been implicated as the cause of bilateral congenital absence of maxillary lateral incisors [3,4,5]. Age, location, space limitations, alveolar ridge deficiencies, uneven gingival margins, occlusion, and periodontal factors often necessitate an interdisciplinary approach for management of congenitally missing lateral incisors. Various methods for treatment of congenitally missing lateral incisors include canine substitution as laterals, single tooth implants and tooth supported restorations[6]. Many challenges are involved in obtaining and retaining an optimal result. In congenital absence of lateral incisors, the most preferred treatment would either be between space regaining of lateral incisors and later replacing it with prosthesis or space closure with canine substitution as laterals. For this several parameters need to be considered before treatment planning. The decision making process for management for congenitally missing lateral incisors is based on[7]:

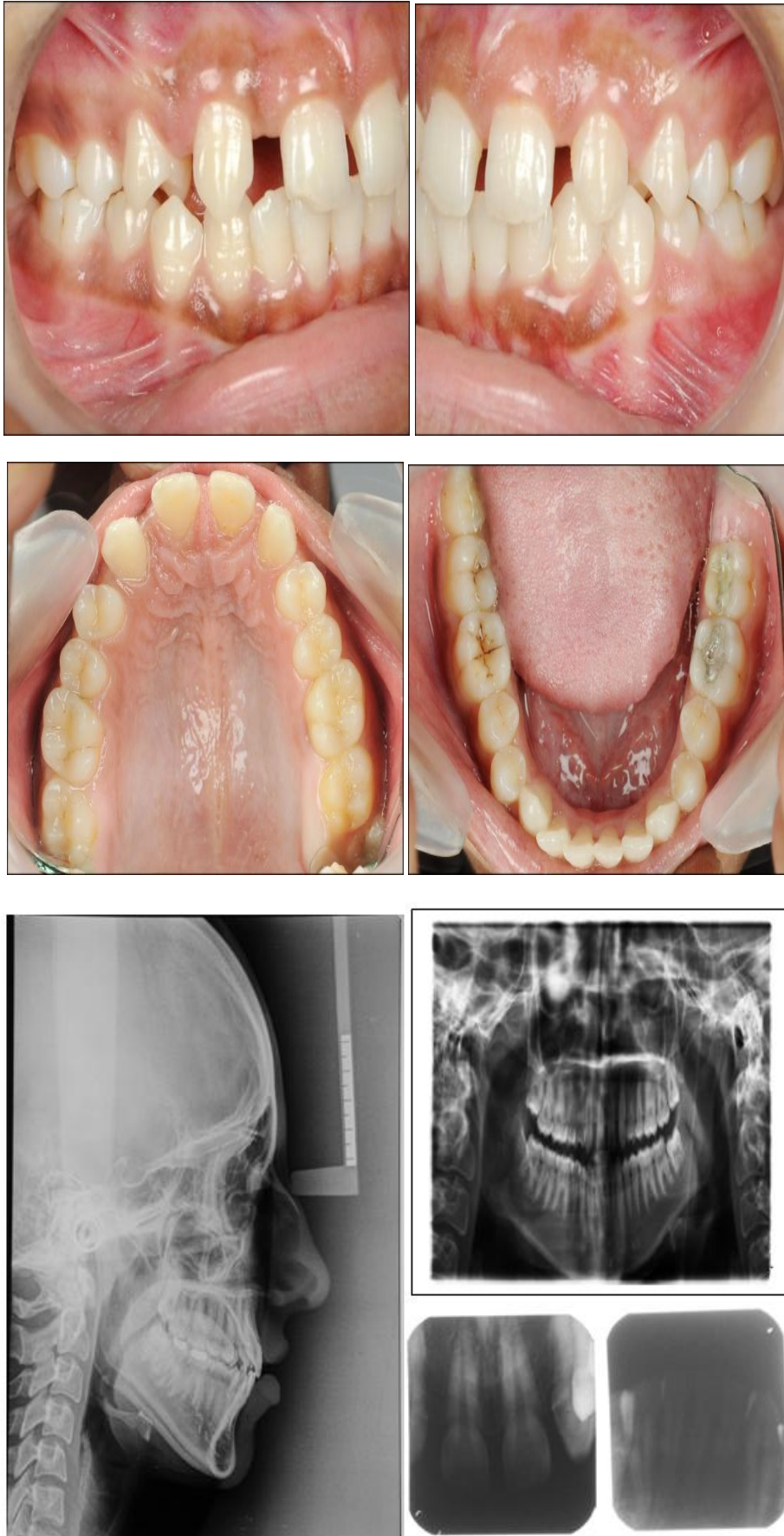- Occlusal relationship
 - *Overjet and Overbite:* Reduced overjet and increased overbite may easily be improved by space opening mechanics, whilst increased overjet and reduced overbite may benefit from space closure
 - *Molar relationship:* Molar Class I or Class III tendency are better treated with space opening to preserve ideal occlusal anterior and posterior relationship (i.e., canine and molar relationship) and establish a solid Angle's Class I relationship. In case of full cusp or partial molar Class II, space closure is preferred to facilitate orthodontic biomechanics and reduce treatment duration. A stable molar Class II and canine Class I relations are then obtained.
- Growth pattern: Space opening is indicated in low-angle subjects, while it is not advised in high angle cases.
- Profile: Retruded profiles are better treated with space opening and tooth substitution, in order to improve labial sagittal relationships. This treatment strategy should be avoided in subjects with bimaxillary dental protrusion, in which it could result in worsening of the profile.
- Arch length: In case of arch length discrepancies extractions in the lower arch should be considered, thus obtaining a molar and canine Class I.
- Canine morphology and position: Shape and size of canines affect the possible rehabilitation choice. Differently from cases with large canines, in which space opening is advocated, small canines can be easily transformed in lateral incisors by using porcelain veneers or composite materials. The original position of the canine should be considered. Teeth closer to the midline are best candidate for incisor substitution.
- Patient expectation and compliance

The amount of space is determined by two factors: Esthetics and occlusion. An esthetic relationship exists between the size of the maxillary central and lateral incisor teeth. This size ratio has been called the "golden proportion". Ideally, the maxillary lateral incisor should be about two-thirds width of the central incisor[8].

II. Case history

A 16 year old female patient presented with chief complaint of gaps in upper front teeth. Patient had no remarkable medical or dental history with no previous trauma or history of surgery or any symptoms related to disorders of TMJ. On clinical examination patient had Angle's Class I molar relation bilaterally, Class I canine relation on left side and end-on canine relation on right side superimposed over skeletal Class I maxilla-mandibular base relationship with average growth pattern and mesoprosopic facial form. Upper lateral incisors were missing bilaterally which was confirmed radiographically. There was generalized spacing in upper arch anteriorly with midline diastema and mild crowding in lower arch and rotated upper first premolars. She had a straight profile with excessive gingival display on smile.





Treatment Objectives

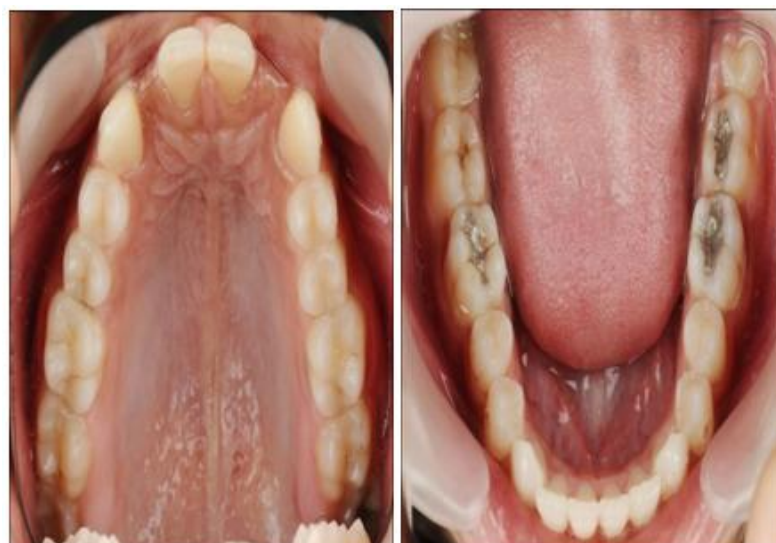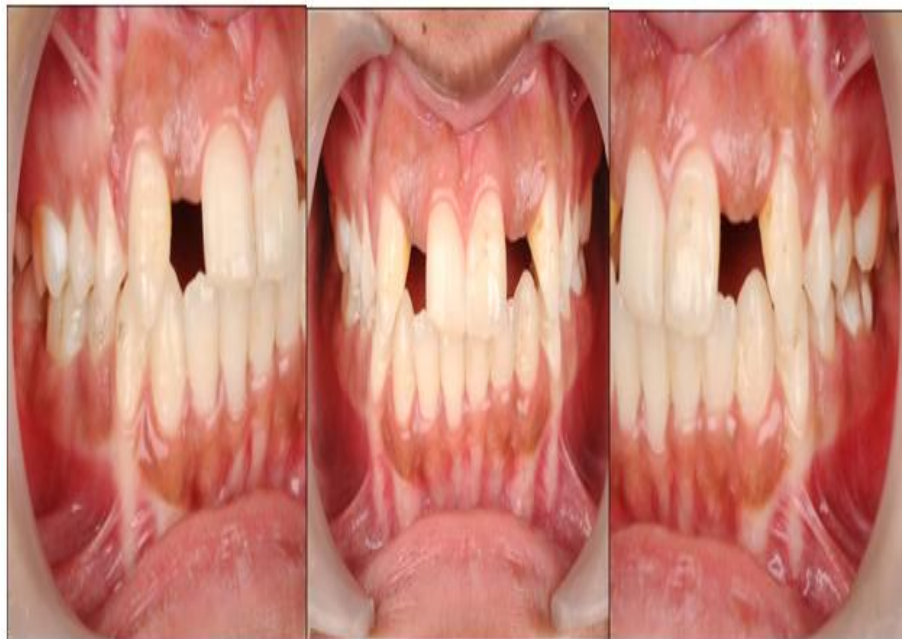- To obtain Class I canine relation bilaterally
- To create space for prosthesis of upper lateral incisors
- To reduce gingival display on smiling
- To provide prosthetic replacement of upper lateral incisors

1. Treatment plan

Create space for missing lateral incisors orthodontically and replacing it with fixed prosthesis

2. Treatment Progress

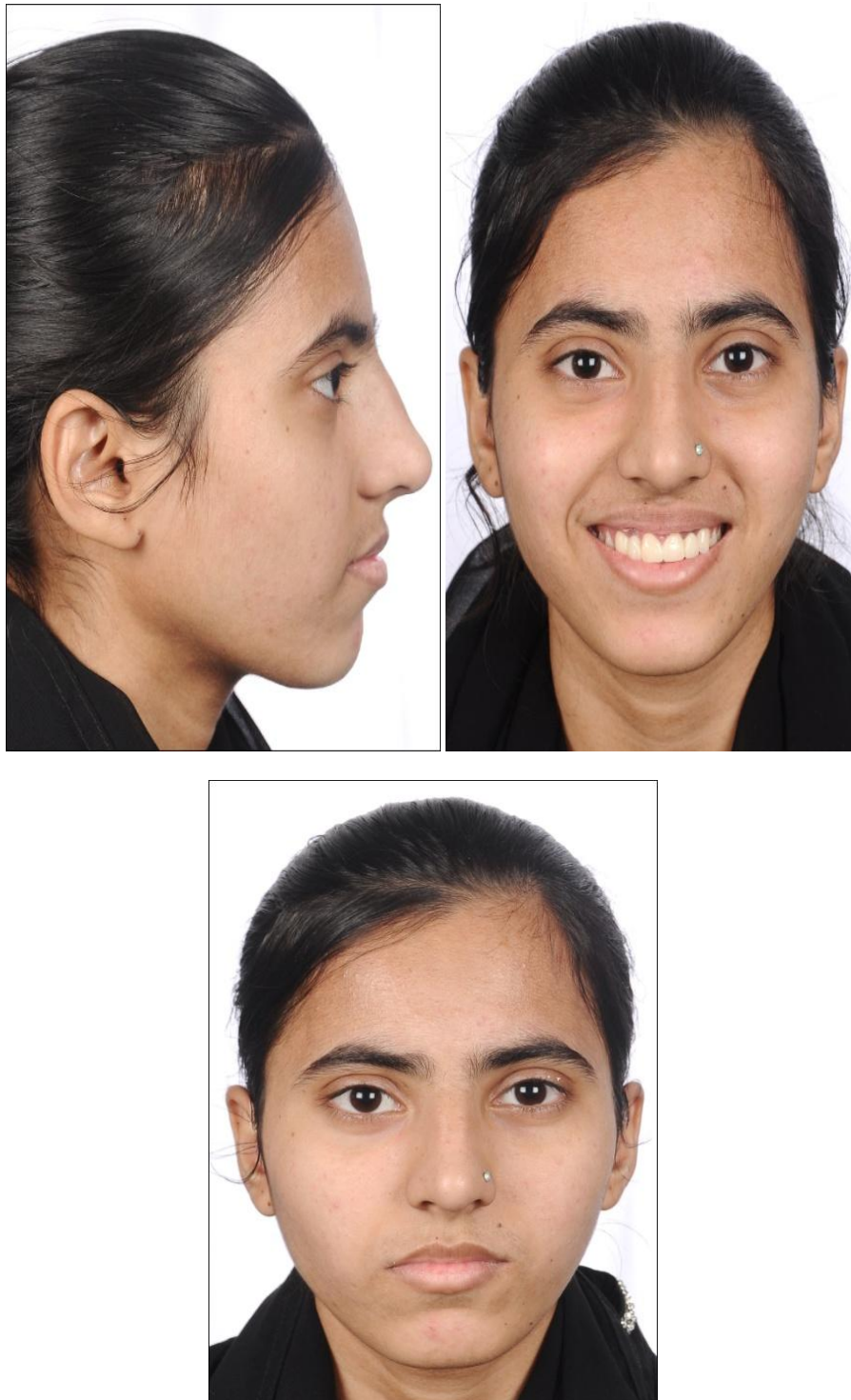
- Case was started with 0.022" MBT PAE appliance.
- 0.016" round NiTi wire was used for alignment and leveling of both the dental arches and correction of rotation of upper first premolars.
- 0.017"x0.025" HANT was then placed for maintaining the correction
- 0.017"x0.025" SS wire was used for distalizing canines and closing ing NiTi open coil springs.
- Tip back springs were used to intrude the upper incisors.
- 0.019"x0.025" SS wire was used for maintenance of corrections and settling of occlusion.
- All orthodontic appliance were debonded and debanded for prosthetic replacement

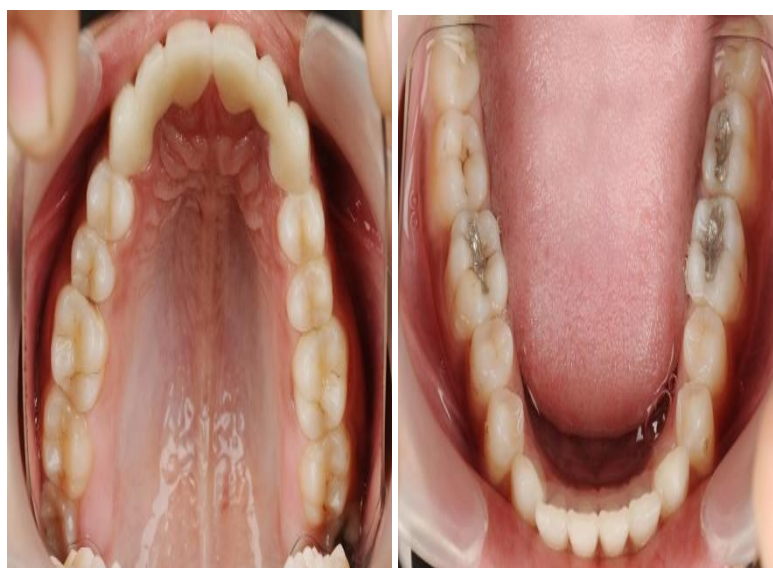
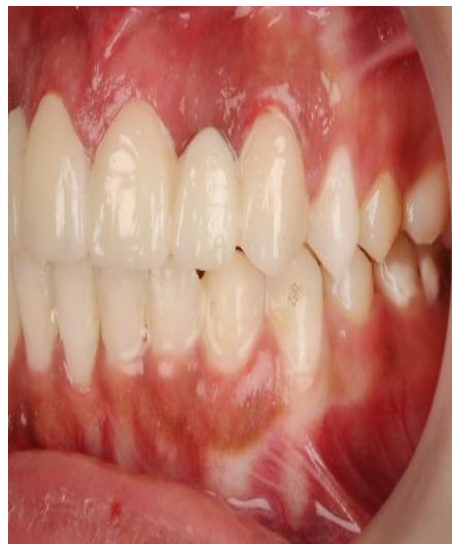
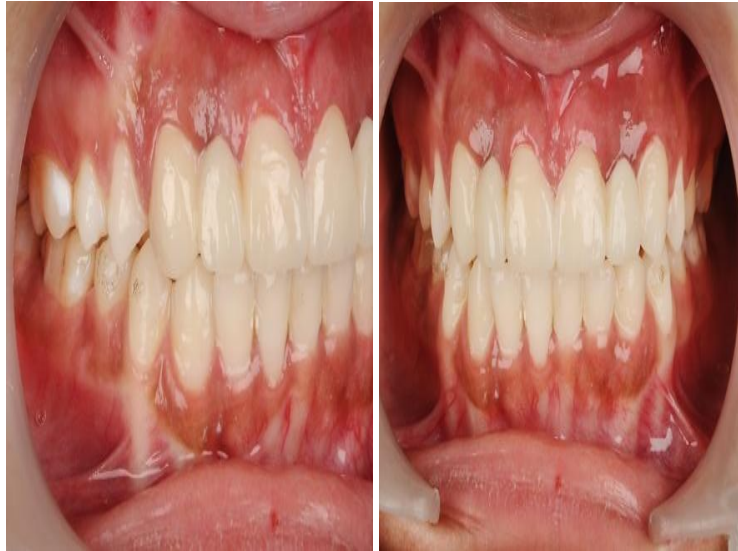A CBCT was taken for assessing bone width as loss of bone width is usually seen in lateral incisor area in cases when they are missing. The bone width in lateral incisor was found to be insufficient for implant placement. So, a two piece fixed partial denture was planned for the patient to achieve natural looking upper midline. The prosthesis was designed following the rules of golden proportion and required minimal tooth reduction.

III. Treatment Results

Post treatment records show that treatment objectives obtained. The facial photographs show significant improvements in her smile which follow rules of golden proportion. Class I molar relation is maintained and Class I canine relation is achieved.





IV. Discussion

The presented case report demonstrates that pleasing results are obtained with decision to replace missing tooth with fixed prosthesis. The clinical situation associated with congenitally missing teeth is often

difficult, and a dilemma for a clinician to select the best treatment plan. With interdisciplinary co-ordination it is possible to achieve the goals of orthodontic treatment.

References

- [1]. Muller TP, Hill IN, Petersen AC, Blayney JR. A survey of congenitally missing permanent teeth. J Am Dent Assoc 1970, 81:101-7.
- [2] Rose JS. A survey of congenitally missing teeth excluding third molars in 6,000 orthodontic patients. Dent Pratt 1966;17: 107-14.
- [2]. Dahl E. Craniofacial morphology in congenital clefts of the lip and palate. Acta Gdntol Stand 1970;28(suppl 57).
- [3]. Graber LW. Congenital absence of teeth: a review with emphasis on inheritance patterns. J Am Dent Assoc 1978;96:266-75.
- [4]. Woodworth DA, Sinclair PM, Alexander RG. Bilateral congenital absence of maxillary lateral incisors: a craniofacial and dental cast analysis. AM J ORTHOD 1985;87:280-93.
- [5]. Kokich VG. Managing orthodontic-restorative treatment for the adolescent patient. In: McNamara JA, Brudon WL, editors. Orthodontics and dentofacial orthopedics. Ann Arbor (Mich): Needham Press; 2001. p. 423-52.
- [6]. McNeil RW, Joondeph DR. Congenitally absent maxillary lateral incisors: treatment planning considerations. Angle Grthod 1973;43:24-9
- [7]. Vincent G Kokich, Frank M Spear. Guidelines for managing the orthodontic-restorative patient. Semin Orthod 1997;3: 3-20.

*Dr.Falguni Mehta. "Smile Rehabilitation of Bilaterally Missing Maxillary Lateral Incisors: An Interdisciplinary Approach." IOSR Journal of Dental and Medical Sciences (IOSR-JDMS) 16.8 (2017): 07-13