

Pulpotomy Using Platelet Rich Fibrin And Biodentinin A Permanent Molar Tooth-A Case Report

Dr. PoojaAnilkumar Bhojraj Patil¹,Dr. Laxmikant Kamatagi²,Dr. Jayaprakash Patil³,Dr. Prahlad Saraf⁴

¹(PG Student, Department of Conservative Dentistry and Endodontics, P M N M Dental College and Hospital, Bagalkot, Karnataka, India)

²(Reader, Department of Conservative Dentistry and Endodontics, P M N M Dental College and Hospital, Bagalkot, Karnataka, India)

³(Head Of The Department, Department of Conservative Dentistry and Endodontics, P M N M Dental College and Hospital, Bagalkot, Karnataka, India)

⁴(Reader, Department of Conservative Dentistry and Endodontics, P M N M Dental College and Hospital, Bagalkot, Karnataka, India)

Abstract :

Aim:To evaluate the use of autologous substances such as platelet concentrates and calcium silicate based materials in promoting the healing and regeneration of the inflamed pulp. Vital pulpotomy was performed on carious, mandibular first permanent molar diagnosed with chronic irreversible pulpitis. Taking into consideration the patient's age and the condition of the underlying pulp tissue, Platelet Rich Fibrin(second generation plasma derivative) pulpotomy was planned in view of preserving the vitality of the intact radicular pulps. Regenerative procedures with second generation blood matrices were chosen to encourage the recovery of the inflamed pulps. The systematic follow-up examinations performed at 24 hours, 1 week, 1 and 3 and 6 months revealed a successful clinical and radiological outcome. Within the limits of the present clinical study and correlating the success across the treated clinical case, we safely conclude the potential scope of regenerative pulpotomy approaches in chronic irreversible pulpitis in adult permanent teeth.

Keywords: Biodentin,Platelet rich fibrin,Pulpotomy

Date of Submission: 18 -08-2017

Date of acceptance: 28-08-2017

I. Introduction

Restorative therapy is aimed at restoring proper form, function and preserving the tooth vitality. Pulpal diseases can be treated by vital pulp therapies direct and indirect pulp capping or pulpotomy, in later stages pulpectomy may be required. Vital pulp plays an important role in induction, formation, nutrition, defense, and sensation along with the capacity to produce secondary, tertiary, and reparative dentin to the external stimuli.^[1,2] Therefore every effort should be made to preserve the vitality of the tooth. Pulpotomy includes removal of coronal portion of the pulp and preserving radicular pulp, followed by placement of a material which will protect pulp from further insult and induce healing and repair. In past years, variety of materials have been advocated for pulpotomy such as Calcium hydroxide after its use in 1978 by MiomirCvek. But it has several disadvantages such as antimicrobial efficacy when placed in contact with tissue fluids due to decrease in its acidic pH, limited sealing ability. MTA is one of the materials which is used frequently with drawbacks such as poor handling properties and prolonged setting time. Resins have also been tried with no promising results in humans.^[3]

Biodentine being a calcium silicate based material was introduced in 2009 (Septodont), also known as "dentin replacement" material has improved physical properties like adequate compressive strength, and short setting time along with biocompatibility and bioactivity.^[4,5]

PRF consists of an autologous leukocyte-platelet-rich fibrin matrix composed of a tetra molecular structure, with cytokines, platelets and stem cells within it which acts as a biodegradable scaffold that favors the development of microvascularization and is able to guide epithelial cell migration to its surface. This autologous matrix demonstrated in *in vitro* studies a great potential to increase cell attachment and a stimulation to proliferate and differentiate osteoblasts. PRF releases cytokines such as IL-4 by activating a subpopulation of

T-cells which aids in healing by moderating inflammation and inhibiting IL-1b-mediated stimulation of MMP-1, MMP-3, and synthesis of prostaglandin E-2. Thereby inducing regeneration of pulpal tissue.^[6]

The following case report describes the technique of platelet rich fibrin pulpotomy combined with Biodentine in mature permanent tooth .

II. Case Report

A 25-year-old man with a non-contributory medical history reported to our department with complaint of carious mandibular permanent first molar. The complete dental history was recorded with emphasis on the history of present illness. On extra oral examination, there was no swelling or tenderness with respect to that particular tooth. On clinical examination, there was a deep carious lesion involving the occlusal surface [Fig.1]. There was tenderness on percussion and no associated sinus opening adjacent to the tooth. On radiographic examination, the RVG image revealed a deep carious lesion involving the enamel, dentin, and pulp in the mandibular right permanent first molar. Electric pulp testing was done to evaluate the vitality of that tooth, during which patient had lingering pain which disappeared after removal of stimulus. Based on the clinical, radiographic, and pulp sensibility examinations, the diagnosis was established as asymptomatic irreversible pulpitis with apical periodontitis. The treatment modality of coronal pulpotomy using PRF was explained to the patient as an alternative to the conventional root canal treatment. The written consent was obtained from the patient. The medical examination and tests for the bleeding time, clotting time, and platelet count were performed and were found to be in normal range. The tooth was anesthetized with an inferior alveolar nerve block using Lignocaine 2% with adrenaline and rubber dam isolation was achieved. Access to the carious lesion was gained and pulpotomy was performed using a high speed arotor hand piece and the coronal pulp tissue was removed till the pulpal floor using a sharp endodontic spoon excavator. Hemostasis was attained using cotton pellets moistened with saline. [Fig.2]

PRF was prepared by drawing blood into a 10 mL test tube without the addition of an anticoagulant. Hence, to prevent the blood from coagulating after coming in contact with the glass tube, it was centrifuged immediately using a table top centrifuge at 3000 rpm for 15 minutes. The product thus obtained consisted of the three layers: the top most layer of acellular platelet poor plasma, the middle layer of platelet rich fibrin, and the bottom most layer of red blood corpuscles [Fig 3]. The PRF was segregated and was squeezed to form a membrane followed by its placement over the exposed pulp stumps [Fig.4]. Biodentine was placed over PRF to an approximate thickness of 2 mm and permanent restoration was done with Glass Ionomer Cement [Fig.5]. Digital radiographs were taken and the patient was recalled after one day, 1 week, 1 and 3 and 6 months [Fig.6] and evaluated for the presence of pain.

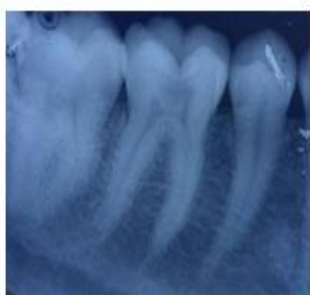

Fig.1-Preoperative radiograph

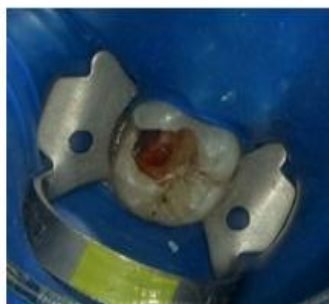

Fig.2- Removal of coronal pulp

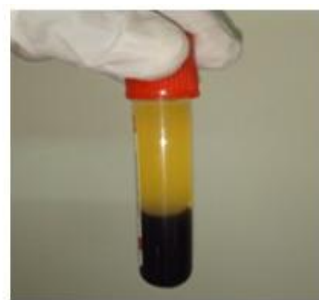


Fig.3-PRF Preparation- the middle layer of platelet rich fibrin

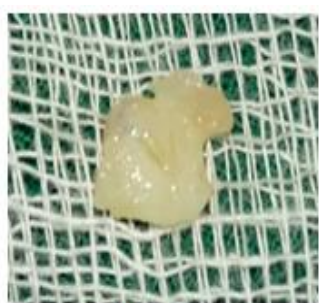

Fig.4- PRF membrane

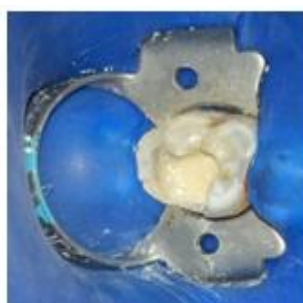


Fig.5- After placement of biodentine over PRF

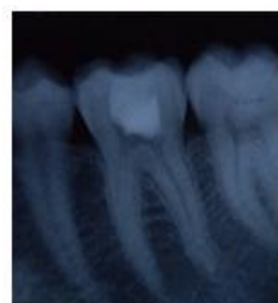


Fig.6- 6 months follow up

III. Discussion

Irreversible pulpitis can be treated more efficiently because of increased awareness and attention of researchers towards regenerative procedures. Wang et al. in 2010 demonstrated that the pulp tissue in teeth clinically diagnosed with irreversible pulpitis still has putative cells with stem cell properties. Pulp regeneration can be achieved by harnessing the regeneration potential of these cells providing suitable environment for the same^[7].

In the current case, an effort was made to use PRF which consists of growth factors that help in repair of a tooth with pulpitis along with its advantages of biocompatibility and bioactivity.^[8] According to a study conducted by Huang et al. PRF exerted no cytotoxic effect on dental pulp stem cells and each cell maintained its original morphology. PRF also actively contributes in pulpal healing by release of growth factors such as PDGF and Transforming growth factor beta which enhances proliferation and differentiation of stem cells.^[9] Drawbacks such as the prolonged setting time, difficult handling characteristics, and high cost of MTA have created a need for search of a more suitable material. Biodentine has dentin-like mechanical properties, which may be considered a suitable material for clinical indications of dentin-pulp complex regeneration.^[10]

Follow-up radiographs after 3, 6 months revealed total resolution of the periapical rarefactions and a trabecular pattern approaching normal [fig.6,7]. The potential theory behind the success of this case report could be that the pulp cells residing in pulp clinically diagnosed with pulpitis might have stem cell potential similar to healthy pulp cells and therefore might be a resource for autologous pulp regeneration as formerly stated by Wang et al.^[11] One of the key factors in determining the success rate of this technique is the status of pulp before vital pulp therapy.^[12] The ability to control bleeding is usually used as an indicator to assess the extent of pulpal inflammation, yet, there may be presence of inflammation in residual radicular pulp.^[13]

The results of the present case reports substantiate with those of study by McDougal et al. who reported clinical success rate of 90% at 6 months and 78% at 12 months. Radiographic success, however, was only 49% of pain-free teeth at 6 months and 42% of pain-free teeth at 12 months. Two common causes generally ascribed to a decrease in success rate over time are coronal leakage and presence of residual infection in pulp. Also according to Kumar V et al, clinical success rate was 85.4% at 12 months. However, when radiographic success was also included, the overall success rate was much lower, being 62.5% and 39.6% at 6 months and 12 months, respectively.^[12]

Another restraint in the present study was the limited diagnostic efficacy of the methods used to establish pulpal diagnosis. Advanced diagnostic methods based on pulpal blood flow can be advocated for a better case selection.

IV. Conclusion

The present case report showed that PRF is an effective vital pulp therapy agent for treating human permanent teeth with irreversible pulpitis, relieving associated pulpal symptoms and preserving pulp vitality. The slow polymerizing potential of PRF and the fibrin technology accounts for a favorable physiologic structure to support healing. Growth factors can act as a fundamental for tissue regeneration within tooth, thereby helping in dental tissue repair.

References

- [1]. Asgary S, Ahmadyar M. Vital pulp therapy using calcium-enriched mixture: An evidence-based review. *J Conserv Dent* 2013;16:92-8.
- [2]. Iwamoto CE, Adachi E, Pamejjer CH, Barnes D, Romberg EE, Jefferies S. Clinical and histological evaluation of white ProRoot MTA in direct pulp capping. *Am J Dent* 2006;19:85-90.
- [3]. M. J. Eghbal, S. Asgary, R. A. Baglue, M. Parirokh, and J. Ghoddusi, "MTA pulpotomy of human permanent molars with irreversible pulpitis," *Australian Endodontic Journal* 2009;35:4-8.
- [4]. Laurent P, Camps J, De Méo M, Déjou J, About I. Induction of specific cell responses to a Ca(3) SiO(5)-based posterior restorative material. *Dent Mater* 2008;24:1486-94.
- [5]. Laurent P, Camps J, About I. Biodentine induces TGF- β 1 release from human pulp cells and early dental pulp mineralization. *IntEndod J* 2012;45:439-48.
- [6]. Dohan DM, Choukroun J, Dissa A, Dohan SL, Dohan AJ, Mouhyi J, et al. Platelet rich fibrin (PRF): A second generation concentrate. Part II: Platelet related biologic features. *Oral Surg Oral Med Oral Pathol Oral Radiol Endod* 2006;101:e45-50.
- [7]. Comparative evaluation of platelet-rich fibrin, mineral trioxide aggregate, and calcium hydroxide as pulpotomy agents in permanent molars with irreversible pulpitis: A randomized controlled trial. *Contemp Clin Dent* 2016;7:512-8.
- [8]. Seltzer S, Bender IB, Ziontz M. The dynamics of pulp inflammation: Correlations between diagnostic data and actual histologic findings in the pulp. *Oral Surg Oral Med Oral Pathol* 1963;16:969-77.
- [9]. Huang FM, Yang SF, Zhao JH, Chang YC. Platelet-rich fibrin increases proliferation and differentiation of human dental pulp cells. *J Endod* 2010;36:1628-32.
- [10]. Borkar SA, Ataide I. Biodentine pulpotomy several days after pulp exposure: Four case reports. *J Conserv Dent* 2015;18:73-8.
- [11]. Hiremath H, Saikalyan S, Kulkarni SS, Hiremath V. Second-generation platelet concentrate (PRF) as a pulpotomy medicament in a permanent molar with pulpitis: A case report. *International Endodontic Journal* 2012;45:105-112.
- [12]. Kumar V, Juneja R, Duhan J, Sangwan P, Tewari S. Comparative evaluation of platelet rich fibrin, mineral trioxide aggregate and calcium hydroxide as pulpotomy agents in permanent molars with irreversible pulpitis: A randomized controlled trial. *Contemp Clin Dent* 2016;7:512-8.
- [13]. Ward J. Vital pulp therapy in cariously exposed permanent teeth and its limitations. *Aust Endod J* 2002;28:29-37.
- [14]. Kleitches AJ, Lemon RR, Jeanson BG. Coronal microleakage in conservatively restored endodontic access preparations. *J Tenn Dent Assoc* 1995;75:31-4.

*Dr. Pooja Bhojraj Patil. "Pulpotomy Using Platelet Rich Fibrin And Biodentin in A Permanent Molar Tooth-A Case Report." *IOSR Journal of Dental and Medical Sciences (IOSR-JDMS)* 16.8 (2017): 38-41