

A Clinical Evaluation to Assess the Amount of Residual Excess Cement when Using Prefabricated and Custom Fabricated Implant Abutment and a Modified Final Restoration.

*¹Vinni TK, Pramod Kumar AV², Suresh Babu C³, Jerry Mammen⁴

¹Associate Professor, Dept of Prosthodontics, Govt Dental College, Thrissur.

²Professor, Dept. of Prosthodontics, Govt. dental College, Thrissur.

³Professor, Mahe Institute of Dental sciences.

³Assistant Professor, Govt. Dental College, Thrissur.

Corresponding author: *Vinni TK

Abstract: Major disadvantage of a cement retained implant fixed prosthesis is the entrapment of residual excess cement in the peri-implant space especially in cases with deep restoration margins. In order to reduce the entrapment, various design modifications of abutments and final restorations were suggested.

Aim: Aim of the study was to compare the amount of residual excess cement formed after cementation (I) a final restoration on a custom fabricated abutment with long collar to reduce the depth of gingival sulcus, (II) a modified crown with a vent hole in the coronal area and (III) conventional technique.

Methods: 30 implant sites with gingival collar height more than 4 mm were restored with the above three techniques and the amount of residual excess cement formed is collected and weighed and compared.

Result: Mean weight of the residual excess cement formed were Group I -0.004238 gm SD -0.002532, Group II -0.012867gm SD -0.002378, Group III- 0.024563gm SD- 0.003042. Result of the study shows there is a statistically significant difference between group I, group II and group III

Conclusion: If aesthetics permits the abutment crown margin should be within 2 mm for safe removal of trapped residual excess cement. In deep gingival collar height it could be advisable to use customized abutments with clinically visible margins.

I. Introduction

Cement retained prosthesis are still continuing as the most commonly used implant fixed prosthetic option. The advantages of cement retained implant crowns include improved esthetics, control of occlusion, reduced fabrication cost and its resemblance to the procedure routinely performed on natural teeth.

However, cement retained implant restorations are not without limitations. A number of case reports demonstrate the occurrence of acute peri-implantitis manifesting as tissue swelling, inflammation or fistula around implants within few months after placement of cement retained implant prosthesis. Evidence of cement excess in subgingival space and their influence on peri-implantitis was seen in 81% of cases ranging from acute severe bone resorption to implant loss^(1, 2). The most possible reason for cement remnants in tissues is the common practice to place implant restoration margins subgingivally⁽³⁾. Aesthetic paradigms demand placement of the crown margins subgingivally⁽⁴⁾, which could lead to incomplete cement removal and development of iatrogenic peri-implant diseases^(5, 6, 7).

The presence of thick soft tissue over the residual ridge often necessitates placement of implant collar deep subgingivally. The difficulties in removing the residual excess cement increases with the increase in the depth of gingival sulcus. One method to reduce the incidence of residual excess cement is the use of custom fabricated abutment to make the margin within 1-2 mm subgingivally, for the ease of removal of excess cement. Another method suggested is the use of vent-holes in the final restoration for the venting of excess cement occlusally. In this clinical study a custom fabricated abutment with long collar to reduce the depth of gingival sulcus of final restoration, and a modified crown with a vent hole in the coronal area is compared against conventional technique regarding the amount of residual excess cement formed after cementation.

Review of literature

Pauletto et al and Gapski et al have stated that several case reports have been published revealing complications caused by residual cement, ranging from acute severe bone resorption to implant loss^(1, 2).

Wilson et-al in 2009⁽⁷⁾ explored the relationship between peri-implant disease using the dental endoscope. He concluded that excess dental cement was associated with signs of peri-implant disease in the majority (81%) of the cases. Clinical and endoscopic signs of peri-implant disease was absent in 74% of test implants after the removal of excess cement.

Wadhvani et-al compared the amount of cement extruded while cementing a crown with and without access hole prepared on the crown. They concluded that the use of two, 0.75 mm radius vent holes placed 3 mm apical to the occlusal area of the abutment and 180 degrees apart will limit the amount of cement extruded into the gingival sulcus of implant retained crowns.⁽⁸⁾

Linkevius et-al in 2011 initiated a study to evaluate the amount of the residual cement excess after cementation and cleaning of implant-supported restorations with various positions of the margins. Results showed that the amount of residual cement after cleaning increased as the restoration margins were located more subgingivally.⁽⁶⁾

Linkevius et-al in 2013 evaluated the amount of undetected cement after cementation and cleaning of implant-supported restorations. He concluded that the deeper the position of the margin, the greater amount of undetected cement was discovered. Dental radiographs should not be considered as a reliable method for cement excess evaluation.⁽⁹⁾

Emir Yuzbasioglu et al in 2014 stated that the major drawback of cement-retained restorations is the extrusion of the excess cement into the peri-implant sulcus, with subsequent complications. Insufficient removal of the excess cement may initiate a local inflammatory process, which may lead to implant failure. The article presents a method of controlling cement flow on implant abutments, minimizing the excess cement around implant-retained restorations, using stock or custom implant abutments, when cement-retained implant-supported restorations are utilized.⁽¹⁰⁾

Belser et-al have recommended to leave the implant margins 1-2mm subgingivally and this position is still a reference point for many clinicians⁽³⁾.

Anderson et-al have suggested that crown margins should be even deeper than 2mm to achieve a better crown emergence profile⁽⁴⁾.

Agar et-al have demonstrated that it is impossible to clean all the cement if margin is located 1.5-3mm below the peri-implant tissue level^(5,6). In addition the study has revealed that cleaning of cement may result in extensive scratching of the abutment.

The aim of the study was to compare the efficacy of custom fabricated abutment with final restoration and placement of vent hole in the final restoration in reducing the amount of residual excess cement (REC) left undetected after cementation of implant restorations.

Materials and Methods

30 implant sites were selected from patients coming to the Department of Prosthodontics, Govt. Dental College, Kozhikode, for replacement of missing teeth and were willing to participate in the study. Healthy patients within 20 -50 years of age undergoing treatment for implant supported cement retained prosthesis with osseointegrated implants (Adin Implants, Adin Dental Implant Systems Ltd, Afula, Israel) were selected. Cases with inflamed gingival tissue around implants and pregnant ladies were excluded from the study. During the prosthetic phase of implant surgery, two weeks after placement of gingival former, the height of the soft tissue from the implant collar to the gingival margin were measured with a probe and those cases with more than 4mm height were selected. Impressions were taken using direct double mix putty wash technique (Express STD Putty &Light body, 3M ESPE, USA).Cast is then prepared in type IV gypsum after placement of implant analogue. From the prepared cast two types of abutments and crowns were fabricated.

Group I:-A straight or angulated Titanium pre-fabricated abutment was selected and modified with PEEK to get proper emergence profile and sufficient gingival collar height to make the final restoration margin within 1 mm subgingivally without compromising the crown retention.

Preparation of custom abutment: After preparation of retention grooves with a diamond disc on the titanium abutment surface (Fig 1), wax-up was done with dental casting wax (Fig 2), invested in phosphate bonded investment (Brevest, Bredent GmbH &Co.KG, Senden, Germany).After dewaxing at 630°C, the mould was cooled down to 400°C. Pressing of PEEK was done at 400°C with a pressing machine (For 2 Press, Bredent GmbH &Co.KG, Senden, Germany). After deinvesting, custom abutment is retrieved and necessary adjustments were done with a Tungsten carbide bur. Gingival collar is polished to high gloss with PEEK polishing kit(Fig 3). Final restoration: Final restoration with an occlusal hole for easy access to abutment screw was fabricated in porcelain fused to metal by using conventional casting and ceramic layering. The access opening was sealed with composite resin so that it does not interfere with crown seating and will prevent venting of luting agent during cementation.

Group II:- Straight or angulated Titanium abutments(Adin, Israel) with shoulder finish line and 1mm collar height were secured to the implant analogue of prepared cast and a modified porcelain fused to metal(PFM) crown with occlusal opening was fabricated which enable easy retrievability and access to the abutment screw after cementation, which also enables easy venting of excess cement.

Group III: - The same crown used in the group II is used after sealing the access opening with composite resin without interfering with crown seating to prevent venting of luting agent during cementation(Fig 4).

Type I Glass Ionomer Cement (GC Gold Label 1, GC Corporation, Tokyo, Japan) Dispensing, mixing and cementation were done according to the manufacturer’s instructions. The same quantity of cement was loaded in the crown for all 3 groups.

After cementation of group II, the excess cement oozing out of the sulcus and within the gingival sulcus were removed with an explorer. The abutment screw was removed along with the prosthesis as a single unit, any cement adhered to the crown, and abutment and left deep in the gingival sulcus was carefully removed and collected. For group I& III after the cement set, the composite resin was removed with air turbine handpiece and diamond bur to facilitate access to abutment screw. Then steps will be repeated for group I and group III as in Group II (Fig 5, 6). The residual excess cement in each group will be weighed separately with an analytical balance and then correlated statistically. The final prosthesis was cemented on the same appointment.

II. Results

Result of the study shows there is a statistically significant difference between the groups I, II, and III. The amount of residual excess cement formed is significantly lower in case of custom fabricated abutment, followed by modified final restoration. (Table 1, Graph 1)

III. Discussion

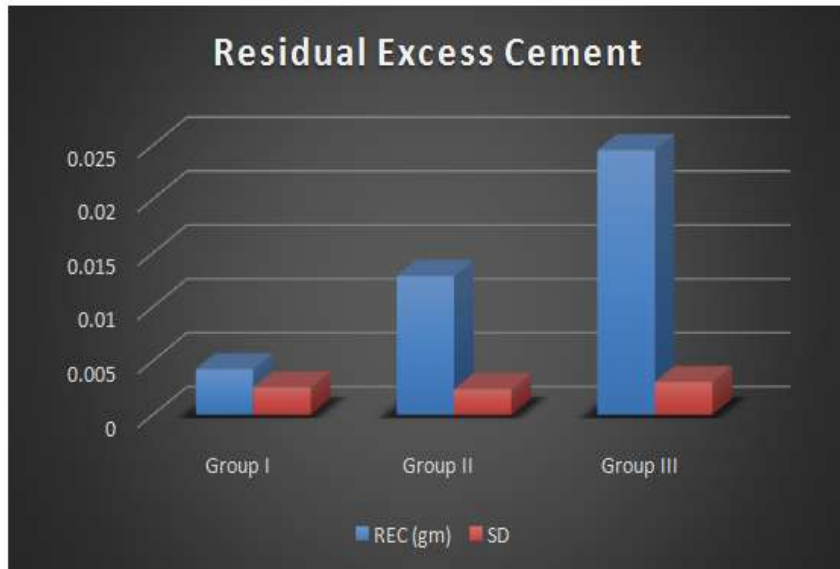
The current implant practice recommends placing the margin of an abutment below the soft-tissue level for aesthetic reasons. This is performed to hide the abutment–crown interface and to provide a favorable emergence profile. A review by Buser and colleagues has suggested that under normal conditions, the implant shoulder should be positioned 1-2 mm apically to the labial cemento-enamel junction of adjacent teeth⁽¹¹⁾. In aesthetic zone,in some clinical situations, due to excessive soft tissue thickness the gingival collar height may go even upto 6-7 mm . It must be noted that in such cases, interproximal crown margins are located even more subgingivally and are impossible to reach during removal of excess cement.

The results obtained from the data thus support the rejection of the null hypothesis, as the location of the margin had a statistically significant relation to the amount of undetected cement after cleaning. The result of the study correlates with the findings of Agar and colleagues, who were the first to state that cementation of the prostheses with 1.5–3 mm subgingivally placed margins may lead to insufficient cement removal⁽⁵⁾. An interesting finding of the study was that cement was left around the restorations, and in the gingival sulcus even after the researcher was convinced to have removed all the cement. This is also in agreement to the result of a clinical study done by Wilson which showed that about 80% of implant restorations contained REC, although the operators thought that they had removed it completely⁽¹²⁾.

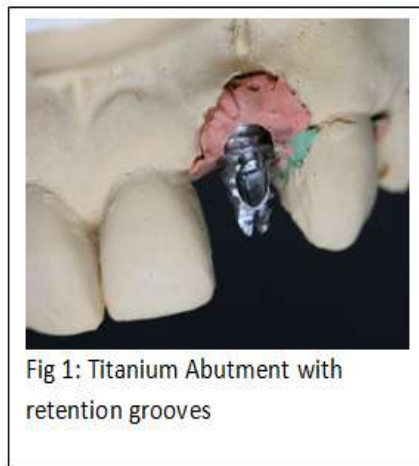
Residual Excess cement		
	Mean(gm)	Standard deviation
GROUP I	0.004238	0.002532
GROUP II	0.012867	0.002378
GROUP III	0.024563	0.003042

Residual excess cement	GROUP(I)	GROUP(J)	P value
	GROUP I	GROUP II	0.000*
	GROUP II	GROUP III	0.000*
	GROUP I	GROUP III	0.000*

Table 1: Comparison of mean values of Residual excess cement formed between Group I, II,& III



Graph 1: showing the comparison of mean values of residual excess cement formed IN GROUP I, II, and III

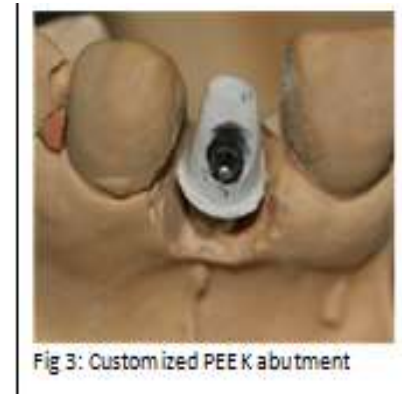
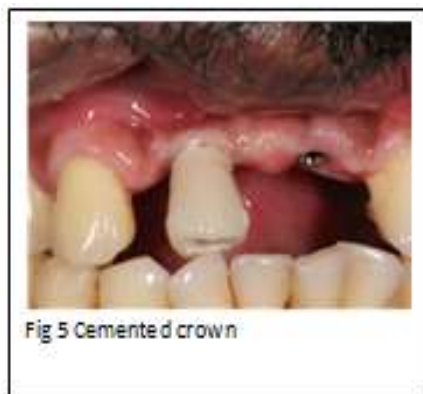
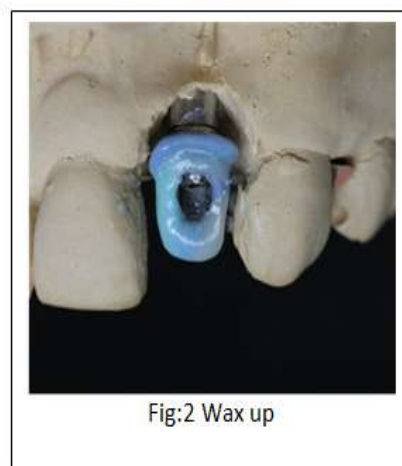


Fig 4: Final restoration with vent holes



Fig 6 Crown shows residual excess cement

The observation from the present study thus contradicts the proposed criteria for crown margin location, suggesting that cemented implant restoration should have a more coronal position. Andersson with colleagues also stated that deep subgingival margins can lead to insufficient cement removal⁽¹³⁾. It is also observed that the cases with cementation margins located supragingivally or equally with gingiva had the least excess of luting cement after cleaning. As the margin moved apically it was difficult to clean the REC completely. Thus it is obvious that margin visibility plays a crucial role in cement elimination. In contrast to natural teeth, the peri-implant tissues lack resistance to pressure due to the absence of an attachment to the implant surface. Connective tissue fibers do not attach to the implant and align themselves parallel along the fixture surface⁽¹⁴⁾. Subsequently, the peri-implant tissues may be less resistant to pressure compared with tissues around teeth⁽¹⁵⁾. Several studies have shown that pressure ranging from 20 to 130 N can be developed during the cementation of crowns⁽¹⁶⁾. This would suggest that cement may be pushed deeper in the peri-implant sulcus and restricts removal even after meticulous cleaning.

Techniques have been developed to minimize the extrusion of cement into the peri-implant soft tissues. The use of individual abutments with a restorative margin, which follows the contour of cemento-enamel junction, was advocated as a method to minimize excess luting agent after cementation⁽¹⁷⁾. It was also noted that during the study excess cement was seen more in the proximal areas where it was difficult to remove. Vent holes placed on occlusal or cervical thirds of the restoration might also be considered to avoid gross extrusion of cement into peri-implant tissues.

IV. Conclusion

Within the limitations of the study, following conclusions were drawn after the analysis of results. The amount of residual excess cement formed by all the three types of luting cements used in the study showed statistically significant increase as the depth of the gingival collar height increased. Based on the results of the study the following suggestions can be made. If aesthetics permits the abutment crown margin should be within 2 mm for safe removal of trapped residual excess cement. In deep gingival collar height it could be advisable to use customized abutments with clinically visible margins and easy cleanable cement for luting cement-retained restorations or give preference to screw-retained prostheses.

References

- [1]. Pauletto, N., Lahiffe, B.J. & Walton, J.N. (1999) Complications associated with excess cement around crowns on osseointegrated implants: a clinical report. *The International Journal of Oral & Maxillofacial Implants* 14: 865–868.
- [2]. Gapski, R., Neugeboren, N., Pomeranz, A.Z. & Reissner, M.W. (2008) Endosseous implant failure influenced by crown cementation: a clinical case report. *The International Journal of Oral & Maxillofacial Implants* 23: 943–946.
- [3]. Belser, U.C., Schmid, B., Higginbottom, F. & Buser, D. (2004) Outcome analysis of implant restorations located in the anterior maxilla: a review of the recent literature. *The International Journal of Oral & Maxillofacial Implants* 19 (Suppl.): 30–42.
- [4]. Andersson, B., Odman, P., Lindvall, A.M. & Branemark, P.I. (1998) Cemented single crowns on osseointegrated implants after 5 years: results from a prospective study on CeraOne. *International Journal of Prosthodontics* 11: 212–218.
- [5]. Agar, J.R., Cameron, S.M., Hughbanks, J.C. & Parker, M.H. (1997) Cement removal from restorations luted to titanium abutments with simulated subgingival margins. *Journal of Prosthetic Dentistry* 78: 43–47.
- [6]. Linkevicius T, Vindasiute E, Puisys A, Peciuliene, V. (2011) The influence of margin location on the amount of undetected cement excess after delivery of cement-retained implant restorations. *Clin. Oral Impl. Res.* 22; 1379–1384.
- [7]. TG Wilson Jr, (2009) The Positive Relationship Between Excess Cement and Peri-Implant Disease: A Prospective Clinical Endoscopic study. *Journal of periodontology* Sep; 80(9):1388-92.

- [8]. Wadhvani C, Piñeyro A, Hess T, Zhang H, Chung KH. Effect of implant abutment modification on the extrusion of excess cement at the crown-abutment margin for cement-retained implant restorations. *Int J Oral Maxillofac Implants*. 2011 Nov-Dec;26(6):1241-6.
- [9]. Linkevicius T, Vindasiute E, Puisys A, et al. The influence of the cementation margin position on the amount of undetected cement. A prospective clinical study. *Clin Oral Implants Res* 2013;24(1):71-6.
- [10]. Yuzbasioglu E. A modified technique for extraoral cementation of implant retained restorations for preventing excess cement around the margins. *J AdvProsthodont* 2014;6(2):146-9. Belser U, Buser D, Higginbottom F. Consensus statements and recommended clinical procedures regarding esthetics in implant dentistry. *Int J Oral Maxillofac Implants* 2004;19 Suppl:73-4.
- [11]. Belser U, Buser D, Higginbottom F. Consensus statements and recommended clinical procedures regarding esthetics in implant dentistry. *Int J Oral Maxillofac Implants* 2004;19 Suppl:73-4.
- [12]. Wilson TG, Jr. The positive relationship between excess cement and peri-implant disease: a prospective clinical endoscopic study. *J Periodontol* 2009;80(9):1388-92.
- [13]. Andersson B, Odman P, Lindvall AM, Lithner B. Single-tooth restorations supported by osseointegrated implants: results and experiences from a prospective study after 2 to 3 years. *Int J Oral Maxillofac Implants* 1995;10(6):702-11.
- [14]. Hermann JS, Buser D, Schenk RK, Higginbottom FL, Cochran DL. Biologic width around titanium implants. A physiologically formed and stable dimension over time. *Clinical Oral Implants Research* 2000;11(1):1-11.
- [15]. Ericsson I, Lindhe J. Probing depth at implants and teeth. *Journal of Clinical Periodontology* 1993;20(9):623-27.
- [16]. Black S, Amore J. Measurement of forces applied during the clinical cementation of dental crowns. *Physiological measurement* 1993;14(3):387.
- [17]. Dumbrigue HB, Abanomi AA, Cheng LL. Techniques to minimize excess luting agent in cement-retained implant restorations. *J Prosthet Dent* 2002;87(1):112-4.

*1Vinni TK. "A Clinical Evaluation to Assess the Amount of Residual Excess Cement when Using Prefabricated and Custom Fabricated Implant Abutment and a Modified Final Restoration." *IOSR Journal of Dental and Medical Sciences (IOSR-JDMS)* 16.7 (2017): 86-91.