

## Pleomorphic Adenoma of the Parotid Gland--- Review of 22 Cases

\*DebaJyoti Roy<sup>1</sup>, Nirupama Moran<sup>2</sup>

<sup>1</sup>Assistant professor, Department of Otorhinolaryngology, IQ City Medical College and Narayana Multispecialty Hospital, Durgapur, India.

<sup>2</sup>Senior resident, Department of Otorhinolaryngology, IQ City Medical College and Narayana Multispecialty Hospital, Durgapur, India.

Corresponding author: \*Nirupama Moran

---

### Abstract :

**Background and objectives:** pleomorphic adenoma is the most frequent benign salivary gland tumour, preferentially diagnosed in the parotid gland. This study was to analyse the outcome of patients with pleomorphic adenoma from Parotid gland in order to evaluate the surgical strategy in our institution.

**Materials and Methods:** The study was conducted in the department of Otorhinolaryngology, IQ City Medical College and Narayana Multispecialty Hospital, Durgapur, India between November 2014 to November 2016.

**Results:** The total numbers of cases were 22. Average age group for parotid pleomorphic adenoma was found to be between 31 – 50 years. The number of male patients was 7 and female 15. The pleomorphic adenoma preferentially originated in the right parotid gland (n=22; right 14, left: 8). Primary therapy of the patients were local resection in 5, conservative parotidectomy ( Superficial parotidectomy) in 17. Postoperatively 7 patients developed facial weakness which eventually improved during follow-up, 1 patient there was permanent facial weakness due to facial nerve sacrifice. Follow-up periods taken for 6 months.

**Conclusion:** Pleomorphic adenoma of parotid glands is a benign tumour. Surgery with safety margins is the therapy of choice. Multinodular tumours are prone to recurrent disease.

**Keywords:** conservative parotidectomy, Pleomorphic adenoma, parotid gland, local resection.

---

### I. Introduction

pleomorphic adenoma is the most frequent benign salivary gland tumour, preferentially diagnosed in the parotid gland. It occurs in patients of all ages, with the highest incidence reported in the fourth to fifth decades<sup>1</sup>. Histologically, the tumour is characterized by marked morphological diversity, with glandular, myxomatous and solid areas are seen. Seifert et al classified these tumours into cellular type (27-35%), myxoid (stroma rich) type (35-51%) and the classic type (14-37%)<sup>2</sup>. A capsule is usually present around the tumour, however, this capsule is usually focally thin or absent, particularly with the myxoid subtype and with the larger tumors<sup>3,4,5</sup>. The tumour grows slowly with long quiescent periods and short periods of rapid growth. It is usually symptomless apart from lump but some may complain of local discomfort. If patient presenting with pain and facial paralysis it must be considered for malignancy. The capsule of compressed normal parotid tissue varies in thickness and the tumour extends into the capsule in a lobulated fashion. This is why shelling the tumour out leads to the risk of local recurrence, which may be in several sites since some of the lobules in the capsule can be left behind<sup>6</sup>. If the tumour removal includes a cuff of surrounding parotid tissue, recurrence rates are typically less than 2 percent<sup>7,8,9,10</sup>.

Though pleomorphic adenoma is a benign tumour (Figure-1), if left untreated 5% may become malignant (carcinoma ex pleomorphic adenoma). For this reason, surgical excision is always to be advised<sup>1</sup>.

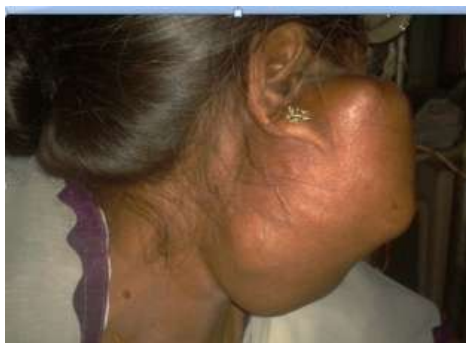

Figure-1 showing pleomorphic adenoma of a female patient

This study was to analyse the outcome of patients with pleomorphic adenoma from Parotid gland in order to evaluate the surgical strategy in our institution.

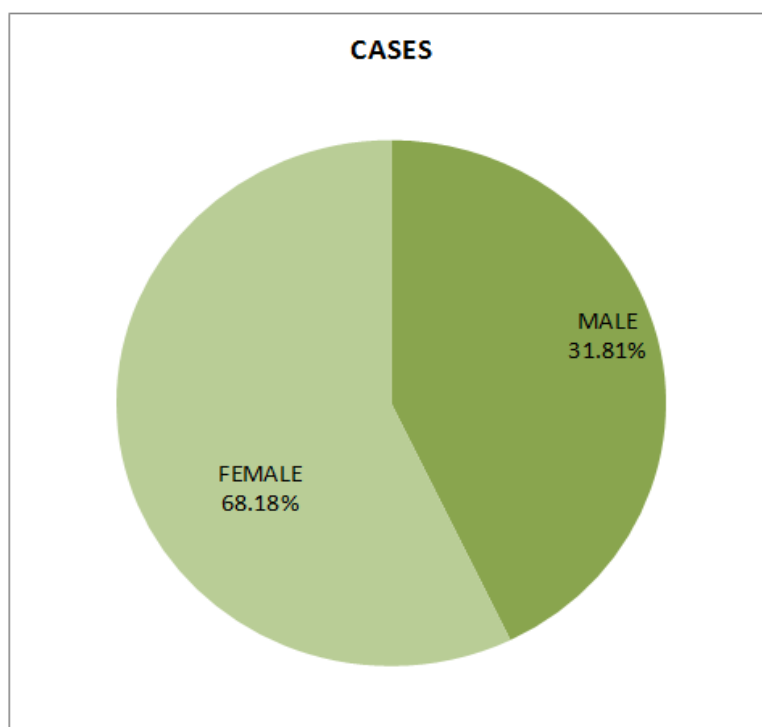
## II. Materials And Methods

The study was conducted in the department of Otorhinolaryngology, IQ City Medical College and Narayana Multispecialty Hospital, Durgapur, India between November 2014 to November 2016. All the patients included in this study were detailed clinical history and physical examination. Demographic data was recorded in terms of age, sex and the site of involvements. Total 22 cases were selected for surgeries. Out of 22 cases, 15 cases were female and 7 cases were male. Based on the clinical and radiological characteristics decisions were taken regarding the types of surgery.

Data were grouped and analysed by standard statistical method.

## III. Results and Observations

Out of 22 cases, 15(68.18%) cases were female and 7(31.81%) cases were male (Figure-2)



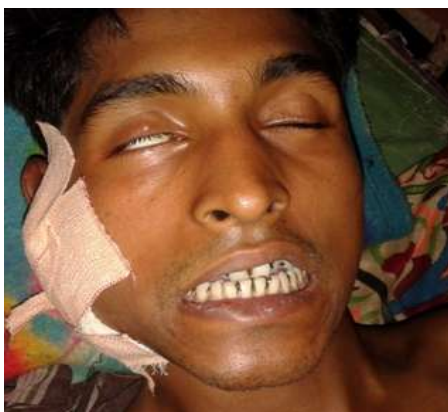**Figure-2.** showing Male and Female ratio

Average age group for parotid pleomorphic adenoma was found to be between 31 – 50 years.

AGE IN YEARS	NUMBER AND PERCENTAGE N=22
1.0-10	1 (5%)
2.11-20	2 (10%)
3.21-30	3 (15%)
4.31-40	5(22.72%)
5.41-50	8 (36.36%)
6.51-60	2 (10%)
7.61-70	1 (5%)
	Total 22

Table-1 showing age wise involvement.

The pleomorphic adenoma preferentially originated in the right parotid gland (n=22; right 14, left: 8). Swelling was the first finding in all the patients. Associated with pain in 36.36 % (n=8) Associated with feeling of pressure in 22.72% (n=5). Recurrent tumour was recorded in 2 patients, both between age group 40-50 years. Both operated outside the study period (Enucleation). There are 15 swellings were located in the pre-auricular, 6 were in the infra-auricular and 1 in the outer mandibular angle. Primary therapies of the patients were local resection in 5; superficial parotidectomies were done in 17 patients. Post-operatively: Local resection – no one developed facial weakness. But 2 patients back with recurrences. Superficial parotidectomies – 7 patients developed facial weakness which eventually improved during follow-up. 1 patient there was permanent facial weakness due to facial nerve sacrifice ( Figure -4). None of the operated patients developed recurrences.



**Figure-4** showing postoperatively developing facial palsy

#### **IV. Discussion**

Pleomorphic adenoma is a benign epithelial tumour. Complete tumour excision is mandatory; otherwise there is a considerable risk of local recurrence. Surgical treatment planning has to consider the risk of a carcinoma arising in a pleomorphic adenoma. In our study it was found that two patients who were enucleation presented to us with recurrence. Parotid gland (superficial parotidectomy) is adequate treatment for the majority of tumours. Enucleation or extra capsular dissection is acceptable in those rare situations when the tumour is hanging off the inferior pole of the parotid gland, but not otherwise. William et al in their study found that the optimal treatment for pleomorphic adenoma is wide excision with negative margins<sup>11</sup>.

The preferred treatment of pleomorphic adenoma of the parotid gland is superficial parotidectomy or total parotidectomy with facial nerve dissection and preservation<sup>12,13,14,15</sup>.

J.D Maynard, he carried out 336 parotidectomies for pleomorphic adenoma of the parotid gland, 130 primary pleomorphic adenomas were treated by wide excision of the tumour after identification of the facial nerve. Recurrence occurred in only one patient and, although 20 patients (15 per cent) experienced some degree of facial nerve weakness postoperatively, there was only one case of permanent weakness<sup>16</sup>.

#### **V. Conclusion**

Pleomorphic adenoma of parotid glands is a benign tumour. Surgery with safety margins is the therapy of choice. Multinodular tumours are prone to recurrent disease.

Partial parotidectomy is an effective treatment for the majority of pleomorphic adenomas; local recurrence is rare and morbidity is low.

#### **References**

- [1]. Patrick Sheahan and Ashok R Shaha. Salivary gland tumours. Stell & Maran's textbook of Head and Neck surgery and oncology, 5th edition 2012, 37:717.
- [2]. Seifert G, Langrock I, Donath K. A pathological classification of pleomorphic adenoma of the salivary glands. HNO 1976; 24:415-26.
- [3]. Stennert E, Guntias –Lichius O, Klussman JP, Arnold G. Histopathology of Pleomorphic adenoma in the parotid gland: a prospective unselected series of 100 cases. Laryngoscope 2001; 111:2195-200.
- [4]. Webb AJ, Eveson JW. Pleomorphic adenomas of the major salivary glands: a study of the capsular form in relation to surgical management. Clinical Otolaryngology and Allied Sciences 2001; 26:134-42.
- [5]. Naeim F, Forsberg MI, Waisman J, Coulson WF. Mixed tumours of the salivary glands: growth pattern and recurrence. Archives of Pathology and Laboratory Medicine 1976; 100: 271-5.
- [6]. A.G.D. Maran. Salivary gland disease. Logan Turner's Diseases of the nose throat and ear. 10<sup>th</sup> edition 1988; 2:11:129-41.
- [7]. Renshan A, Gleave EN, Hancock BD et al. Long-term follow-up of over 1000 patients with salivary gland tumours treated in a single centre. British Journal of Surgery 1996; 83: 1750-4.

- [8]. Leverstein H, Van der Waal JE, Tiwari RM et al. Surgical management of 246 previously untreated pleomorphic adenomas of the parotid gland. *British Journal of Surgery* 1997; 84:399-403.
- [9]. Debets JM, Munting JD. Parotidectomy for parotid tumors: 19-year experience from the Netherlands. *British Journal of Surgery* 1992; 79: 1159-61.
- [10]. Guntinas-Lichius O, Kick C, Klussman JP et al. Pleomorphic adenoma of the parotid gland: a 13-year-old experience of consequent management by lateral or total parotidectomy. *European Archives of Otorhinolaryngology* 2004; 261: 143-6.
- [11]. William M. Mendenhall, Charles M. Mendenhall, John W. Warning, Robert S. Malyapa and Nancy P. Mendenhall. Salivary gland pleomorphic adenoma. *American journal of clinical oncology*. Volume 31, Number 1, February 2008; 95-98.
- [12]. O'Brien CJ. Current management of benign parotid tumors—the role of limited superficial parotidectomy. *Head Neck*. 2003; 25:946–952.
- [13]. Piekarski J, Nejc D, Szymczak W, et al. Results of extracapsular dissection of pleomorphic adenoma of parotid gland. *J Oral Maxillofac Surg*. 2004; 62:1198–1202.
- [14]. Donovan DT, Conley JJ. Capsular significance in parotid tumor surgery: reality and myths of lateral lobectomy. *Laryngoscope*. 1984; 94:324–329.
- [15]. Donovan DT, Conley JJ. Capsular significance in parotid tumor surgery: reality and myths of lateral lobectomy. *Laryngoscope*. 1984; 94:324–329.
- [16]. J.D. Maynard. Management of pleomorphic adenoma of the parotid. *BJS*, Volume 75, Issue 4, April 1988, pages 305-308.

\*DebaJyoti Roy. "Pleomorphic Adenoma of the Parotid Gland--- Review of 22 Cases." *IOSR Journal of Dental and Medical Sciences (IOSR-JDMS)* 16.7 (2017): 36-39.