

Early Vs Delayed Loop Ileostomy Closure: A Comparative Study

*Mritunjay Sarawgi¹, *Sachin K Singh¹, Arun K Tiwary¹, Anjay Kumar¹

¹ Department of Surgery, RIMS, Ranchi, Jharkhand, India

Corresponding author: *Sachin K Singh

Abstract

Background and objectives: Ileostomy is often constructed in emergency surgical conditions like enteric or tubercular perforations when patients present late during illness to preclude primary closure. But the ostomy carries with it lot of morbidity making the quality of life poor. The early closure of ostomy can minimize the associated morbidity and help the patient to enjoy better quality of life sooner. Our aim was to prospectively compare the morbidity and mortality associated with early closure and late closure.

Methods: A total of 47 loop ileostomies made for various indications were taken for study during period Feb. 2013 to Feb. 2016. Patients were divided into two cohorts by the time of stoma closure. Early closure group in which stoma was closed within 4-6 weeks and late or delayed closure group in which stoma was closed after 90 days.

Results: Total 15 patients were taken up for early closure and remaining 32 for late closure. Only 4 patients in early closure group had minor pre-closure complication like skin excoriation. While in late closure group 11 patients had skin excoriation and 6 had prolapsed stoma. There was no instance of anastomotic leak, intraabdominal abscess and mortality in early closure group. Only single case developed enterocutaneous fistula which was managed conservatively. In late closure group two patients developed anastomotic leak requiring re-laparotomy and re-stoma formation.

Conclusion: The present study clearly highlights the potential advantages of early closure of loop ileostomy and is a feasible alternative to a more conventional delayed approach, provided careful selection of patients is done. This helps patients to live a better quality of life much earlier.

Keywords: Ileostomy, Infection, Koch's, Obstruction, Perforation

I. Introduction

In the developed countries, ileostomy is mainly constructed as a protective cover for distal colorectal or ileoanal pouch anastomosis, but in developing countries, it is still often made in emergency surgical settings where infective conditions like enteric or tubercular perforations are common and patients present late in their course of illness which precludes primary closure.

Stoma creation affects patients differently, and the reactions cover perceptions of an altered body image, changes in daily routines, lifestyle and sexuality [1]. On the other hand, stoma creation is a treatment that eliminates disease, relieves pain and improves health, whereby stoma creation may also have a positive impact [2]. Several individual factors are related to the individual's adaptation to life with a stoma including age [3], socio-economic profile [4], personality [5] and sex [6]. Studies have shown inferior quality of life in patients with a stoma compared with those who underwent similar procedures without stoma formation. Reversal of the temporary stoma resulted in improvement in quality of life [7,9] whereas knowing that the situation was temporary could interfere with adaptation to living with a temporary ileostomy [8].

The time for reversal of the stoma is an issue of central importance, and we therefore aim to investigate morbidity and mortality, health and economic implications as well as patient-reported outcome related to the time of reversal of a temporary ileostomy.

II. Methods

2.1 Study design and setting

This is a prospective comparative study of patient admitted for loop ileostomy closure conducted at Rajendra Institute of Medical Sciences, Ranchi, Jharkhand, India from period Feb. 2013-Feb. 2016.

All patient who were primarily operated and ended up with temporary loop ileostomy were admitted via the outpatient department. Consecutively allocated in two cohorts – group A (15 Patient) whose stoma were closed at 4-6 weeks and group B (32 patient) whose stoma closed at 12 weeks. Stoma was closed in two layers in both groups. Only those patients were taken up for early stoma closure whose Hb was > 10gm% and sr. albumin > 2.5gm%. Even preoperative blood transfusion was given to raise Hb up to 10 gm%. In addition, distal loop cologram using water soluble contrast done in all cases to ascertain the distal patency of the intestinal tract.

2.2 Inclusion criteria

All patient admitted for ileostomy closure from Feb. 2013 to Feb. 2016.

2.3 Exclusion criteria

- 1) Signs of active infection
- 2) Repeated complication of stoma/more than one stoma
- 3) Permanent/end ileostomy

2.4 Statistical Analysis

All the statistical analyses were performed using statistical package for social sciences (SPSS Inc., Chicago, Illinois, USA). Continuous data was presented as mean±SD. For calculation of significance between continuous variables between two separate groups, unpaired t- test was used. For calculation of significance between two proportions and percentages, Chi-square test was used.

III. Observation & Results

Patients were divided into two cohorts by the time of stoma closure. Patients with stoma closure within 4 to 6 weeks (n=15) were grouped in early closure while patients with stoma closure at 90 days (n=32) were grouped in late or delayed closure group.

Following observations & results were obtained after analysis of data.

3.1 Age and sex distribution (Fig. 1&2)

Most Patients to undergo early closure are in young age group (11-30 years.) (n=10).

3.2 Indication for initial stoma formation (Fig. 3)

In present study, the most common cause of stoma formation was enteric perforation (62%) followed by Koch's abdomen and trauma, each accounting for 13% of cases. Defunctioning ileostomy was done in 8% of cases. 4% had appendicular perforation.

3.3 Pre-closure complications(Fig.4)

Only 4 patients in early closure group had minor complication of skin excoriation. Whereas in late closure group 11 patients had skin excoriation and 6 had prolapsed stoma.

3.4 Post-op complications (Fig. 5)

Wound infection was the most frequently encountered complication in early closure group (20%). In early group, minor complications were more and only one patient developed enterocutaneous fistula which was managed conservatively and spontaneous healing of fistula occurred in 12 post-operative day. In late closure group, minor complications though less, two patients developed anastomotic leak requiring re-laparotomy and re-stoma formation.

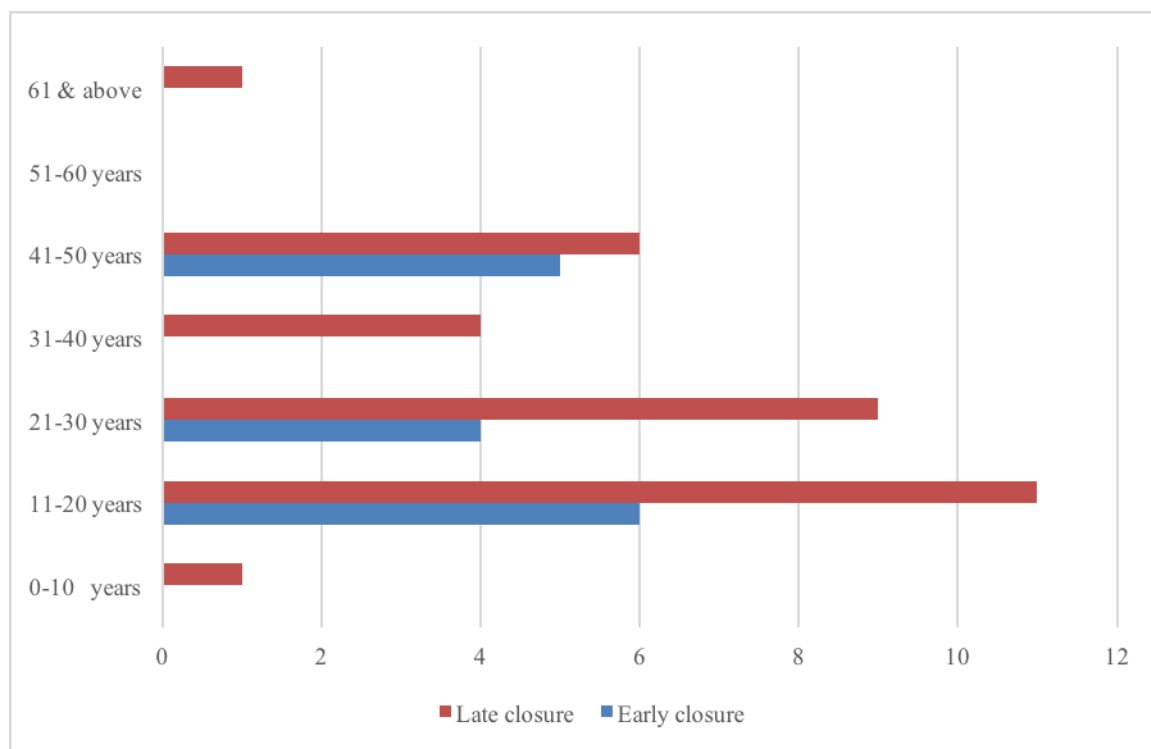


Fig. 1 Age wise distribution

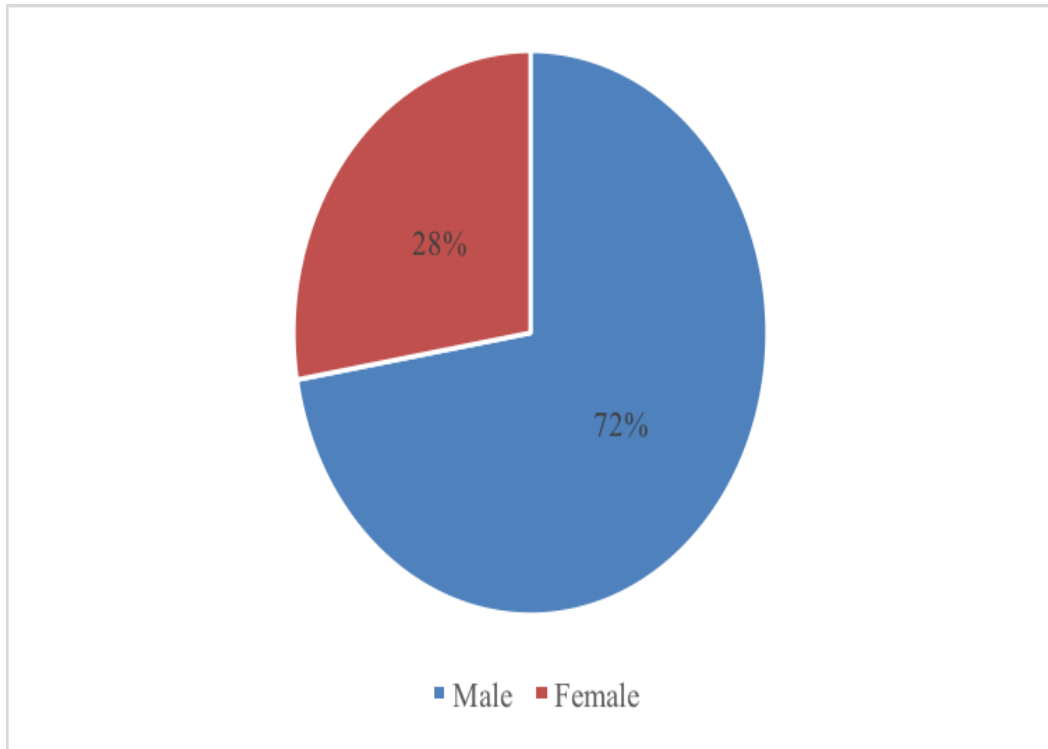


Fig. 2 Sex distribution




Fig. 3 Indications of stoma formation

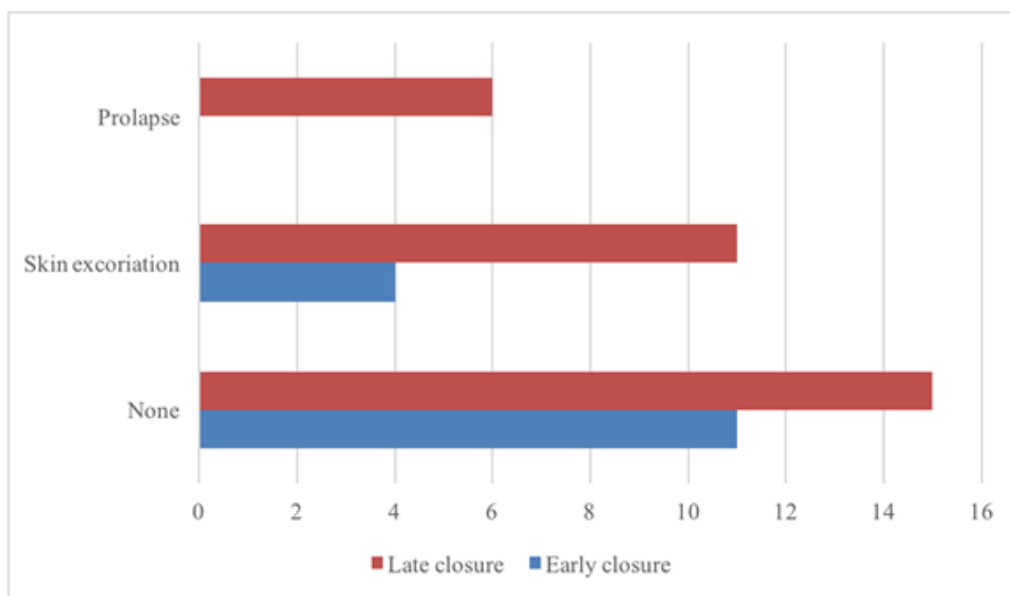


Fig. 4 Pre-closure stoma complications

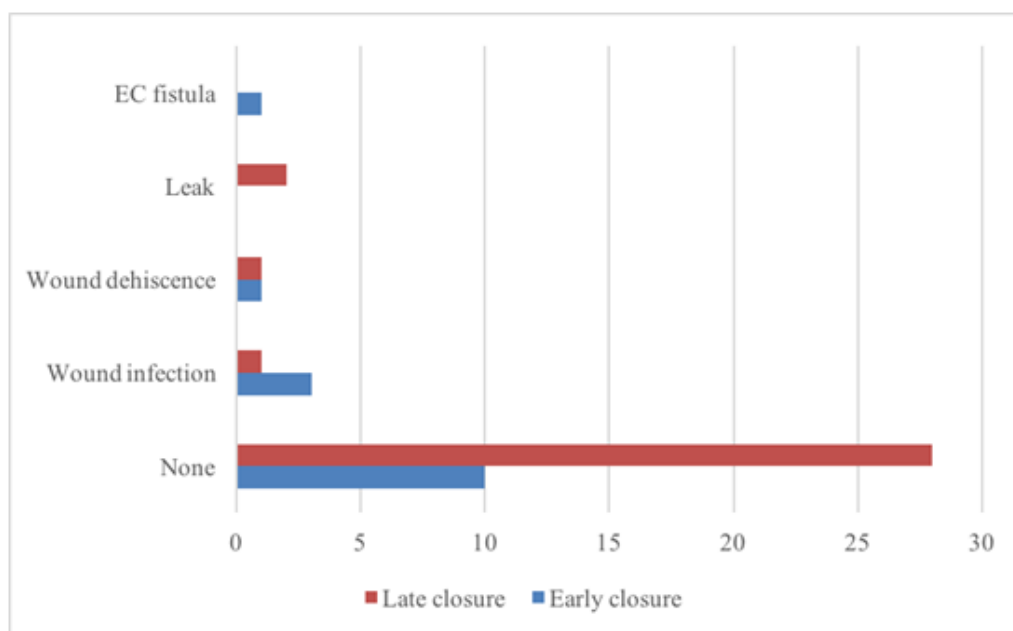


Fig. 5 Post-op complications

IV. Discussion

Intestinal stomas are often created in emergency abdominal situations when primary repair of bowel carries high risk of failure due to gross peritoneal contamination or severely inflamed bowel as can occur in enteric and tubercular perforations or in hemodynamically unstable patient [10,11]. In recent times, many research articles have been published in the west regarding early closure of ostomy but there is sharp difference in patient profile in India and west. In the developed countries, ileostomy is mainly constructed as a protective cover for distal colo-rectal or ileo-anal pouch anastomosis [12,13,14]. But in developing countries, it is still often made in emergency surgical setting where infective conditions like enteric or tubercular perforations are common and patients present late in the course of illness to preclude primary closure [10,11].

Stoma surgery is associated with high costs for patients and society alike. Patients experience a reduced quality of life, due among others to feelings of physical and mental restrictions and debilitating nuisances [15,16,17]. Stoma is associated with morbidity in the form of skin irritation, diarrhea, prolapse, retraction, parastomal hernia, ileus, etc. [18,19], and sometimes increased salt and fluid loss [19,20]. Ostomies are socio-economically expensive because they require training in ostomy care, multiple hospitalizations and contacts to

general practitioners and hospital clinics. In India, stoma formation and the external discharge of effluents is also associated with social stigma.

The literature is in much disarray over the optimal stoma reversal time. Restoration of intestinal continuity is usually performed after 8-12 weeks. However, during this time, stoma related complications occur in a quarter of patients, with adverse effects on quality of life [18,21]. Many randomized clinical trials have demonstrated that early closure of the temporary loop ileostomy was feasible in patients who had an uneventful recovery during the first week after rectal resection. Despite the higher rate of wound complications, early closure was associated with lower rates of medical complications (including stoma-related morbidity) and small bowel obstruction. This study demonstrates that patients undergoing early ostomy closure do not have more complications than patients undergoing late ostomy closure. We also observed similar operative times in the early closure group when compared with the late closure group. Thus, our results do not support the assumption of a “hostile” abdominal environment during early relaparotomy and that ostomy closure could be considered at an earlier time during admission. This has potential benefits for the patients and families and reduces the cost of stoma care.

The inclusion and exclusion criteria of the four prospective studies of early closure were virtually identical [22,23,24]. Patients were not to have symptoms of active infection or organ failure and they had to be in a good physical condition. Furthermore, they were not to show radiological signs of leakage of the anastomosis verified with aqueous contrast examination.

The patient profile is very different in our set up. Most common cause of stoma formation in our study was enteric perforation in 62% of cases. This is in sharp contrast to western world where mostly a temporary covering ileostomy is constructed, especially in low rectal anastomoses, to reduce the number of serious anastomotic leakages which are associated with high levels of morbidity and mortality [13,15]. We observed only 4 patients in early closure group had minor pre-closure complication of skin excoriation. Whereas in late closure group 11 patients had skin excoriation and 6 patients had prolapsed stoma. In a prospective audit of complications of loop ileostomy construction and take down, Garcia-Botello et al [26] described ileostomy related complications in 39.4% patients. The most common were skin related – dermatitis (12.6%) and erythema (7.1%) put together. In another study where ileostomy was done for enteric perforation [12,13], ileostomy related complications occurred in 63.33% of patients. Peristomal skin excoriation (33.33%) was the most common complication followed by weight loss (13.33%), retraction (13.33%), fluid and electrolyte imbalance (10%) and prolapse (3.33%). In fact, these were the very factors, in particular lack of proper stoma care services which motivated us to consider early stoma closure, so that stoma related complication could be minimized. Although early closure seems to have a lot of advantages, not all patients are good candidates for early ostomy closure. The selection of the cases for early closure was done based on adequate nutritional level of the patient and patients with unfavorable parameters were given more time to improve their nutritional status. We kept Hb% and Sr. Albumin levels of 10.0 gm% and 2.5 gm% respectively as cut-off, before considering the patient for stoma closure. Moreover, the distal patency was confirmed by contrast study, and patients with distal obstruction or leak were turned down for early closure. During surgery for stoma closure we didn't encounter any difficulty in dissection and mobilization of bowel from the parietes or peritoneum. Sufficient space was created by lysing intra-peritoneal adhesions so that bowel can be safely repositioned inside the peritoneal cavity. No intra-operative bowel perforations occurred, neither conversion to full laparotomy.

Minor complications are defined as complications directly related to the anastomosis which occur after the stoma has been closed but do not require reoperation. In the literature, such minor complications include ileus, sepsis and abscess. Almost all studies describe minor complications, but the proportion of patients who have complications in the individual studies varies from 4-5% to 30% [24]. In present study wound infection was the most frequently encountered post-operative complication (20%) in early group. In early group, minor post-operative complications were more and one patient develop enterocutaneous fistula, which was managed conservatively. In late closure group, minor complications though less, two patients developed anastomotic leak requiring re-laparotomy and re-stoma formation. In both cohorts, most of the patients passed flatus within 48 hrs. Again, chi-square test yielded a $p=0.142$, meaning no significant difference ($p>0.05$).

Most importantly, we did not encounter any intra-abdominal abscesses, anastomotic leaks or mortality figures in early closure group. This is in contrast to a recorded leak rate of 4.5% and mortality of 2.2% by Samiullah et al[25] and, 5.76% leak rate plus mortality of 1.2% by Nadim Khan et al[24] in evaluating the early closure of temporary loop stoma. Even literature suggests an anastomotic leak rate following closure of ileostomy, whether early or late, in the range of 0% to 8%. The present study has focused primarily on temporary loop ileostomies. We can say that the results of our study are comparable to results of other studies on early closure of stoma as well as to the studies where closure was delayed or even better as far as anastomotic leak and mortality rates are concerned. The stringent adherence to surgical principles, meticulous tissue mobilization and careful selection of patients perhaps all together can lead to favorable outcome in stoma closure, even if done earlier.

V. Conclusion

This study concludes:

- Early closure of the stoma had no adverse effect on functional results.
- By closing the temporary stoma early, would yield economic and administrative benefits to the department and personal benefits for patients.

Limitations of the study

The conclusion is based on a relatively small number of patients in early closure group and a large prospective controlled study, preferably a multicenter study, is therefore warranted.

Acknowledgements

The authors thank Dr. Om Prakash for his valuable contribution in carrying out the study.

Disclosure

The authors declare no conflict of interest.

References

- [1] Chow A, Tilney HS, Paraskeva P *et al.* The morbidity surrounding reversal of defunctioning ileostomies: a systematic review of 48 studies including 6,107 cases. *Int J Colorectal Dis* 2009; 24:711-23
- [2] Hindenburg T, Rosenberg J. Closing a temporary ileostomy within two weeks. *Dan Med Bul* 2010; 57:1-5
- [3] Brown H, Randle J. Living with a stoma: a review of the literature. *J Clin Nurs* 2005; 14:74-81.
- [4] Gooszen AW, Geelkerken RH, Hermans J *et al.* Quality of life with a temporary stoma: ileostomy vs. colostomy. *Dis Colon Rectum* 2000;43:650-5
- [5] Nugent KP, Daniels P, Stewart B *et al.* Quality of life in stoma patients. *Dis Colon Rectum* 1999; 42:1569-74
- [6] Rauch P, Miny J, Conroy T *et al.* Quality of life among disease free survivors of rectal cancer. *J Clin Oncol* 2004; 22:354-60
- [7] Ma N, Harvey J, Stewart J *et al.* The effect of age on the quality of life of patients living with stomas: a pilot study. *ANZ J Surg* 2007; 77:883-5.
- [8] Holzer B, Matzel K, Schiedeck T *et al.* Do geographic and educational factors influence the quality of life in rectal cancer patients with a permanent colostomy? *Dis Colon Rectum* 2005; 48:2209-16.
- [9] Siassi M, Hohenberger W, Losel F *et al.* Quality of life and patient's expectations after closure of a temporary stoma. *Int J Colorectal Dis* 2008; 23:1207-12.
- [10] Platell C, Barwood N, Makin G. Clinical utility of a defunctioning loop ileostomy. *ANZ J Surg* 2005;75(3):147-151
- [11] Zida M, Ouedraogo T, Bandre E, Bonkougou GP, Sanou A, Traore SS. Primary ileostomy for typhoid-related ileal perforation: a 62-case series in Ouagadougou, Burkina Faso. *Med Trop (Mars)*. 2010 Jun;70(3):267-8.
- [12] Struijs MC, Poley MJ, Meeussen CJ, Madern GC, Tibboel D, Keijzer R. Late vs early ostomy closure for necrotizing enterocolitis: analysis of adhesion formation, resource consumption and costs. *J Pediatr Surg*. 2012 Apr;47(4):658-64
- [13] Karanjia ND, Corder AP, Holdsworth PJ, Heald RJ. Risk of peritonitis and fatal septicaemia and the need to defunction the low anastomosis. *Br J Surg* 1991;78(2):196-198
- [14] Gastinger I, Marusch F, Steinert R, Wolff S, Koeckerling F, Lippert H. Protective defunctioning stoma in low anterior resection for rectal carcinoma. *Br J Surg* 2005;92(9):1137-1142
- [15] Sushil Mittal, Harnam Singh, Anand Munghate, Gurpreet Singh, Anjna Garg and Jyoti Sharma. A Comparative Study between the outcome of Primary Repair versus Loop Ileostomy in Ileal Perforation. *Surgery Research and Practice*, Vol. 2014;doi:10.1155/2014/729018.
- [16] Tang CL, Choen FS, Chong SF *et al.* Bioresorbable adhesion barrier facilitates early closure of the defunctioning ileostomy after rectal excision. *Dis Colon Rectum* 2003; 46:1200-7.
- [17] Kronborg O, Jakobsen AK. Cancer Recti. *Ugeskr Laeger* 2002; 164:3046-8
- [18] Leary DP, Fide CJ, Foy C *et al.* Quality of life after low anterior resection with total mesorectal excision and temporary loop ileostomy for rectal carcinoma. *Br J Surg* 2001;88:1216-20
- [19] Gooszen AW, Geelkerken RH, Herman J *et al.* Temporary decompression after colorectal surgery: randomized comparison of loop ileostomy and loop colostomy. *Br J Surg* 1998;85:76-9
- [20] Gooszen AW, Geelkerken RH, Hermans J *et al.* Quality of life with temporary stoma. *Dis Colon Rectum* 2000; 43:650-5
- [21] Thalheimer A, Bueter M, Kortuem M, Thiede A, Meyer D. Morbidity of temporary loop ileostomy in patients with colorectal cancer. *Dis Colon Rectum* 2006; 49:1011-1017
- [22] Alves A, Panis Y, Lelong B *et al.* Randomized clinical trial of early versus delayed temporary stoma closure after proctectomy. *Br J Surg* 2008;95:693-8.
- [23] Jordi Galais P, Turrin N, Tresallet C *et al.* Early closure of temporary stoma of the small bowel. *Gastroenterol Clin Biol* 2003; 27:697-9
- [24] Nadim K, A Bangash, A Hadi, M Ahmad. Is early closure of stoma warranted in the management of temporary loop ileostomy? *JPMI* 2010;24(4):295-300.
- [25] Samiullah, M Ali, S Rahman, A Khan, Y Khalily. Evaluation of early closure of ileostomy. *Gomal Journ of Med Sci* 2010;8(2):143-45
- [26] Garcia-Botello J, Garcia-Armengol E, Granero G. A Prospective audit of the complications of loop ileostomy construction and take down. *Dig Surg* 2004; 21:440-46

*Mritunjay Sarawgi . "Early Vs Delayed Loop Ileostomy Closure: A Comparative Study."
IOSR Journal of Dental and Medical Sciences (IOSR-JDMS) 16.7 (2017): 08-13.