

Assessment of Efficacy of Fluoroscopy Guided Steroid Injection By Transforaminal Approach in Patients with Chronic Lumbosacral Radiculopathy.

*Dr.Nitin Wagh¹,Dr.Sandip Pangavane¹,Dr.Mehul Sarkar¹

¹Department of Orthopedics,Dr. Vasantrao Pawar Medical College and Research Center , Nashik,
Maharashtra,India

Corresponding author: *Dr.Nitin Wagh

Abstract: Lumbosacral radiculopathy has been treated using steroid injections by various approaches for symptomatic pain relief. This study was conducted to identify the efficacy of fluoroscopy guided depot methylprednisolone: lignocaine transforaminal injection for patients with chronic lumbosacral radiculopathy.

Methodology: After clearance from the institutional ethics committee, 20 patients diagnosed with lumbosacral radiculopathy were identified and included in the study with their written informed consent. Detailed history and clinical examination was done and patients were injected with 40mg/ml of depot-methylprednisolone with lignocaine via transforaminal approach. Patients were assessed for pain relief with the Numeric Pain Rating Scale (NPRS-11) on the day of procedure and 1 month, 3 months and 6 months post procedure.

Statistical analysis : The data was analyzed using appropriate statistical tests.

Results and conclusions: Immediately after procedure 55% patients reported complete pain relief. At 1 month post procedure 85% patients reported significant pain relief. At 3 months, 65% patients reported significant pain relief and at 6 months, 50% patients continued to have significant pain relief.

Studies conducted over the years for transforaminal steroid injection for lumbosacral radiculopathy have found variable long term results but this procedure has been found to be effective for short term pain relief.

Keywords: fluoroscopy, lumbosacral radiculopathy, sciatica, steroid, transforaminal

I. Introduction

Lumbar disk herniation is due to displacement of the nucleus pulposus contained in the intervertebral disk through the annulus fibrosus. This might lead to compression and irritation of the lumbar nerve roots leading to radiating pain known as sciatica.^[1] The etiology of the sciatica may be due to mechanical compression of the nerve roots leading to release of inflammatory and noiceptive mediators from the nucleus pulposus.^[2-8] Low back pain is one of the most common symptoms of spinal abnormalities, with an annual point prevalence averaging 30%.^[9] It is the commonest diagnosis amongst degenerative diseases of the lumbar spine.^[1] Disc herniation is treated conservatively initially and surgical treatment reserved for cases with failed or unsatisfactory conservative treatment, progressive neuro-deficit^[1,10]. Out of the Various techniques described in literature, minimally invasive techniques are more valued due to less tissue violation, shorter duration of hospital stay, decreased anaesthetic risk and earlier return to work.^[1-8,11]

Transforaminal radicular block is a good option among the minimally invasive techniques for treating lumbar disc herniation pain. This makes it possible to reduce the inflammatory response, improve the state of pain, reduce the consumption of analgesics, maintain work activities and eliminate the need for surgery, among most individuals.^[8,12-14] Transforaminal root block can be indicated for refractory cases of conservative treatment for radiating pain in an attempt to postpone or avoid surgery.^[1,15] We conducted the present study with the aim of making a significant contribution towards alleviating pain symptoms caused by disc herniation.

II. Methodology

After clearance from the institutional ethics committee, 20 patients diagnosed with lumbosacral radiculopathy were identified and included in the study with their written informed consent. Detailed history and clinical examination was done and patients were injected with 40mg/ml of depot-methylprednisolone with lignocaine via transforaminal approach. Patients were assessed for pain relief with the Numeric Pain Rating Scale (NPRS-11) on the day of procedure and 1 month, 3 months and 6 months post procedure. The sample selection took into consideration the following inclusion criteria: the patients presented with lumbar sciatic pain secondary to disk hernia with no response to 3 weeks of conservative treatment with out any instability as seen on dynamic lateral lumbar radiographs. Patients were excluded if they presented lumbar sciatic pain with causes other than disk hernia, or if their pain responded to conservative treatment after 3 weeks.

Table No.1

INCLUSION & EXCLUSION CRITERIA

INCLUSION CRITERIA	EXCLUSION CRITERIA
Patients with lumbar disc hernia with no response to 3weeks of conservative treatment	Patients with lumbar sciatic pain due to other causes (except disc hernia)
Patients without any instability seen on dynamic lateral lumbar radiographs	Patients showing improvement with conservative treatment after 3 weeks
	Patients with concurrent medical conditions

III. Technique

The patient is put in prone position and the fluoroscopy unit is centered over the spinous processes. Local Anaesthetic is injected at the desired level of block in the skin. The needle is inserted into the skin over the lateral border of and approximately halfway between the two adjacent transverse processes at the target interspace under fluoroscopy guidance. The target landmark for transforaminal needle placement is the inferior aspect of the pedicle, with the needle placement just below superior to the existing nerve root in the 6 o'clock position. Bogduk and Derby and coworkers [16] described a safe "triangle" at this location, with three sides corresponding to the horizontal base of the pedicle, the outer vertical border of the intervertebral foramen, and the connecting diagonal nerve root and dorsal ganglion .Thus, a needle placed into the safe triangle will lie above and lateral to the nerve root. Following this, if the needle has penetrated the epidural membrane there will be a loss of resistance and the patient may experience radiating pain at that point withdraw the needle a few millimeters and inject a mixture of 1ml of 40mg/ml depo-methyl prednisolone mixed with 2 ml of 2% lignocaine .

Fig.1

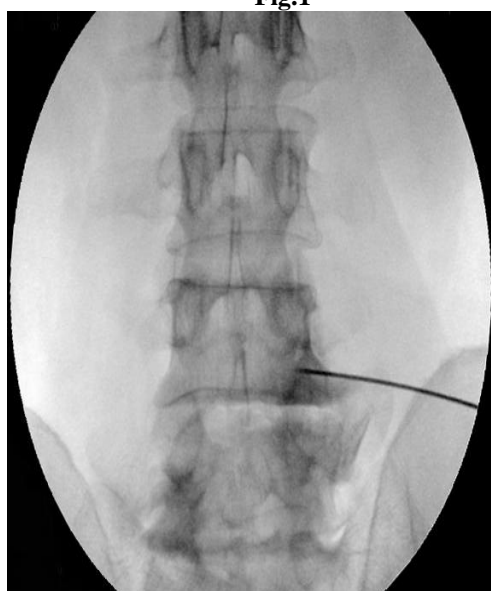
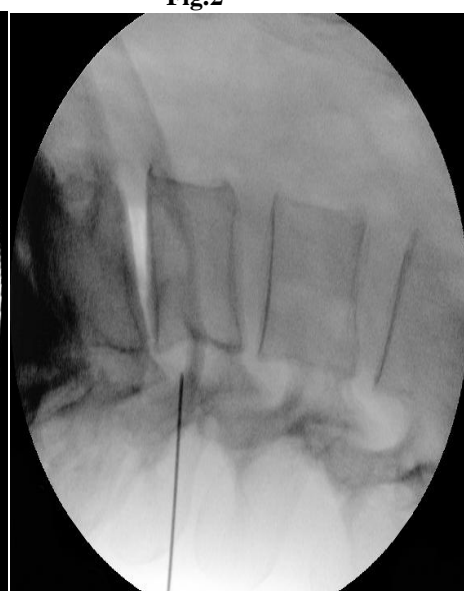
Fig.2



IV. Results

The study sample consisted of 20 patients of which half were males and other half were females from age of 19 to 68 years with a mean age of 42.8 yrs. 4 patients were less than 30 years, 11 patients were in between 30 to 50 yrs and 5 patients more than 50 years of age.

Table No.2

TOTAL NUMBER OF SUBJECTS		20
AGE Mean Age 42.8 yes		
1	< 30 YRS	4
2	30-50 YRS	11
3	>50 YRS	5
SEX		
1	MALES	10
2	FEMALES	10

4.1 At 4 hours post procedure:

55%(11) of the study population had complete pain relief. 45%(9) had considerable pain relief categorized as mild pain. 6 males and 5 females had complete pain relief while 4 males and 5 females had mild symptoms of pain.

4.2 At 1 month ,

5% of the study population had complete pain relief , 80% reported mild pain complains while 15 % noticed moderate pain relief. 1 male had no pain ,9 males and 7 females had mild pain while 3 females moderate pain.

4.3 At 3 months,

65% of the patients of mild pain symptoms.20% had moderate pain symptoms and 15% reported minimal pain relief. 6 males and 7 female had mild pain symptoms and moderate pain symptoms were reported by 3 males and 1 female and 1 male and 2 females had minimal pain relief.

4.4At 6 months,

50% of the study population maintained mild symptoms while 35% patients reported moderate pain relief and 15% had minimal pain relief. 4 male and 6 females reported mild pain symptoms, 4 males and 3 females reported moderate pain relief and 1 male and 2 females reported minimal pain relief.

Table no.3 Perception of pain of subjects on serial assessments on the Numeric Pain Rating Scale -11

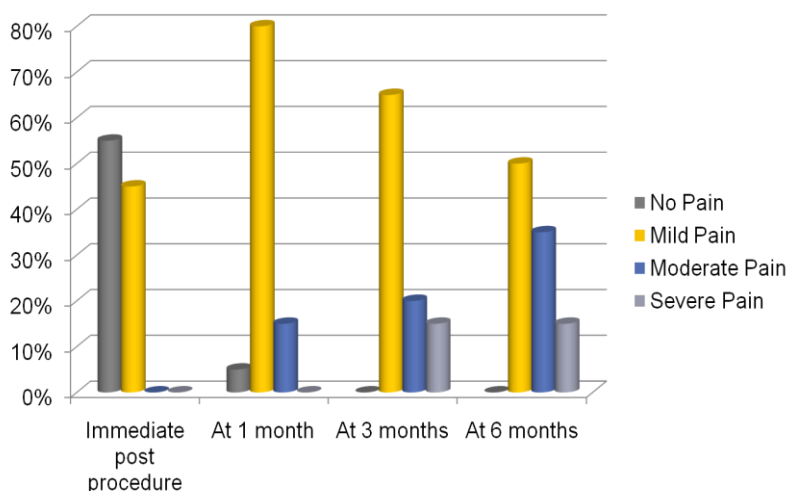
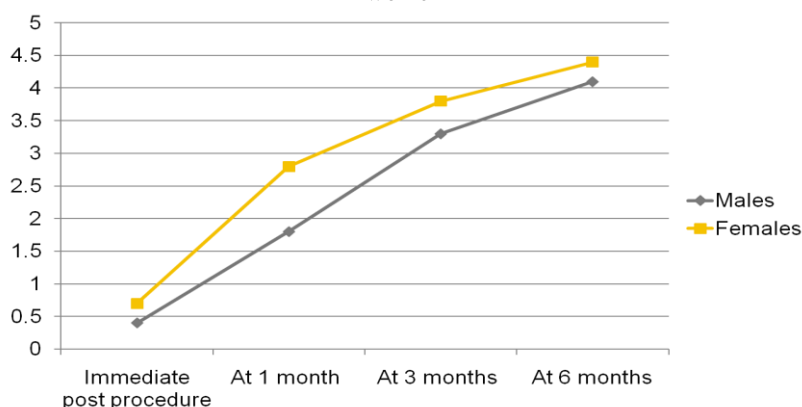


Table No.4 Average pain perception as per serial assessment with numeric pain rating scale-11 in men and women



V. Discussion

Boswell et al. found a strong evidence about the effectiveness of transforaminal steroids for short term pain relief^[19], various other studies reported similar encouraging results.^[20,21] Ackerman and Ahmed in their study reported superiority of transforaminal route as compared to caudal or interlaminar approach.^[26,27]

Our study was designed to measure efficacy of injection of epidural steroids by transforaminal approach for management of lumbar radicular pain due to lumbar disc herniation. Manchikanti et al showed that lumbar disc prolapse was more common in the age group of 30 to 40 years in both males as well as females with male to female ratio of 2:1. In other age groups male:female ratio was almost comparable. In our study we found that initially 55 % of the study population had complete pain relief immediately post intervention and the efficacy of the procedure deteriorated over the period of six months when 15% patients started experiencing severe pain symptoms. The study of William E Ackerman and Mahmood Ahmad gave the following results after a follow-up of 1 year Transforaminal steroid injection: complete pain relief in 30%, partial pain relief in 53.33% and no pain relief in 16.66%. They concluded that transforaminal route was more effective than caudal or interlaminar route.^[26] According to the study conducted by Tschugg A, the pain threshold to lumbar radicular pain was less in women as compared to men.^[31] Our study also found similar trends for pain threshold. Age related pain perception changes were seen in a few studies which were not apparent from our study, most probably because of a small sample size.^[32,33] No adverse effects to the procedure were found in our study. Michel Benoist in his review study on efficacy and safety of epidural steroid injection has mentions good tolerability to epidural steroids and complications usually are related to unsound technique.^[34] Manchikanti et al., do not report any major adverse event in their study assuring its safety.^[35]

VI. Limitation

The major limitation of our study was the small sample size. A large sample size will help factoring in for age, nature of work and detailed study of side effects of this technique. Causality could not be associated due to a smaller sample size.

VII. Conclusion

Our study concludes that effective short term relief can be offered by transforaminal epidural steroid injection for lumbar radicular pain, which is in keeping with other studies based on similar lines. Multiple studies show that long term pain relief solution for radicular pain is surgical intervention. But it may not be desirable for patients who have higher risk of anaesthesia associated complications or those unwilling to undergo a surgical procedure. The financial concern about surgical intervention in our Indian setting is a major factor and transforaminal steroid injections can provide a cost effective solution for patients in these situations. It will be interesting to find out whether the efficacy of this technique increases with serial injections by a similar approach for prolonged pain relief or by concurrent physiotherapy in form of back extension exercises.

References

- [1]. Vialle LR, Vialle EM, Henao JES, Giraldo G. Hémiadiscallombar. Rev Bras Ortop. 2010;45(1):17–22
- [2]. Tachihara H, Sekiguchi M, Kikuchi S, Konno S. Docorticosteroids produce additional benefit in nerve root infiltration for lumbar disc herniation? Spine (Phila PA 1976).2008;33(7):743–7.
- [3]. Depalma MJ, Bhargava A, Slipman CW. A critical appraisal of the evidence for selective nerve root injection in the treatment of lumbosacral radiculopathy. Arch PhysMedRehabil. 2005;86(7):1477–83.
- [4]. Fish DE, Lee PC, Marcus DB. The S1 “Scotty Dog”: report of a technique for S1 transforaminal epidural steroid injection. Arch Phys Med Rehabil. 2007;88(12):1730–3.

- [5]. Karppinen J, Malmivaara A, Kurunlahti M, Kyllönen E, Pienimäki T, Nieminen P, et al. Periradicular infiltration of the sciatic nerve: a randomized controlled trial. *Spine (Phila PA 1976)*. 2001;26(9):1059–67.
- [6]. Kumar N, Gowda N. Cervical foraminal selective nerve root block: a “two-needle technique” with favorable results. *Eur Spine J*. 2008;17(4):576–84.
- [7]. Ng L, Chaudhary N, Sell P. The efficacy of corticosteroids in periradicular infiltration for chronic radicular pain: a randomized, double-blind, controlled trial. *Spine (Phila PA 1976)*. 2005;30(8):857–62.
- [8]. Postacchini F. Management of herniation of the lumbar disc. *J Bone Joint Surg Br*. 1999;81(4):567–76.
- [9]. Chou R, Atlas SJ, Stanos SP, Rosenquist RW. Nonsurgical interventional therapies for low back pain: a review of the evidence for an American Pain Society clinical practice guideline. *Spine (Phila PA 1976)*. 2009;34(10):1078–93.
- [10]. Sousa FA, Colhado OC. Bloqueio analgésico peridural lombar para tratamento de lombociatalgia discogênica: estudo clínico comparativo entre metilprednisolona e metilprednisolona associada à levobupivacaína. *Rev Bras Anestesiol*. 2011;61(5):544–55.
- [11]. Sousa FA, Colhado OC. Bloqueio analgésico peridural lombar para tratamento de lombociatalgia discogênica: estudo clínico comparativo entre metilprednisolona e metilprednisolona associada à levobupivacaína. *Rev Bras Anestesiol*. 2011;61(5):544–55.
- [12]. Sayegh FE, Kenanidis EI, Papavasiliou KA, Potoupnis ME, Kirkos JM, Kapetanos JA. Efficacy of steroid and nonsteroid caudal epidural injections for low back pain and sciatica: a prospective, randomized, double-blind clinical trial. *Spine (Phila PA 1976)*. 2009;34(14):1441–7.
- [13]. Schaufele MK, Hatch L, Jones W. Interlaminar versus transforaminal epidural injections for the treatment of symptomatic lumbar intervertebral disc herniations. *Pain Physician*. 2006;9(4):361–6.
- [14]. Abdi S, Datta S, Lucas LF. Role of epidural steroids in the management of chronic spinal pain: a systematic review of effectiveness and complications. *Pain Physician*. 2005;8(1):127–43.
- [15]. Derby R, Bogduk N, Kine G. Precision percutaneous blocking procedures for localizing spinal pain. Part 2. The lumbar neuraxial compartment. *Pain Digest* 1993; 3:175-188
- [16]. Carrette S, Leclaire R, Marcoux S, Morin F, Blaise GA, St-Pierre A. Epidural corticosteroid injections for sciatica due to herniated nucleus pulposus. *N Engl J Med*. 1997;336:1634–40.
- [17]. Abdi S, Datta S, Trescot AM, Schultz DM, Adlaka R, Atluri SL. Epidural steroids in the management of chronic spinal pain: a systematic review. *Pain Physician*. 2007;10(1):185–212.
- [18]. Boswell MV, Hansen HC, Trescot AM. Epidural steroids in the management of chronic spinal pain and radiculopathy. *Pain Physician*. 2003;6:319–34.
- [19]. Chou R, Atlas SJ, Steven MPH, et al. Nonsurgical interventional therapies for low-back pain. A review of the evidence for an American Pain Society Clinical Practice guideline. *Spine*. 2009;34:1078–93.
- [20]. Spaccarelli KC. Lumbar and caudal epidural corticosteroid injections. *Mayo Clin Proc*. 1996;71:169–78.
- [21]. Koes BW, Scholten R. Efficacy of epidural steroid injections for low-back pain and sciatica: a systematic review of randomized clinical trials. *Pain*. 1995;63:279–88.
- [22]. Luijsterburg P, Verhagen A, Ostelo R. Effectiveness of conservative treatments for the lumbosacral radicular syndrome: a systematic review. *Eur Spine J*. 2007;16:881–99.
- [23]. Nelemans PJ. Injection therapy for subacute and chronic low back pain. *Spine*. 2001;26:501–15.
- [24]. Watts RW, Silagy CA. A meta-analysis on the efficacy of epidural corticosteroids in the treatment of sciatica. *Anaesth Intensive Care*. 1995;23(5):564–69.
- [25]. Ackerman WE, Ahmad M. The efficacy of lumbar epidural steroid injections in patients with lumbar disc herniations. *Anaesth Analg*. 2007;104:1217–22.
- [26]. Laxmaiah M, Vijay S, Vidyasagar P, Frank JE, Joshua A. Comparison of the efficacy of Caudal, Interlaminar, and Transforaminal epidural injections in managing lumbar disc herniation: Is one method superior to the other? *Korean J Pain*. 2015;28:11–21.
- [27]. Pandey RA. Efficacy of Epidural Steroid Injection in Management of Lumbar Prolapsed Intervertebral Disc: A Comparison of Caudal, Transforaminal and Interlaminar Routes. *Journal of Clinical and Diagnostic Research : JCDR*. 2016;10(7):RC05-RC11. doi:10.7860/JCDR/2016/18208.8127.
- [28]. Ergan M, Hansen von Büнау F, Courthéoux P, Viader F, Prouzeau S, Marcelli C. Cerebral vein thrombosis after an intrathecal glucocorticoid injection. *Rev Rhum Engl Ed*. 1997;64(7-9):513–16.
- [29]. Wybier M, Gaudart S, Petrover D. Paraplegia complicating selective steroid injections of the lumbar spine. Report of five cases and review of the literature. *Eur J Radiol*. 2009;59:1539–47.
- [30]. Tschugg Anja, Löscher Wolfgang N., Hartmann Sebastian, Neururer Sabrina, Wildauer Matthias, and Thomé Claudius. *Journal of Women's Health*. September 2015, 24(9): 771-776. doi:10.1089/jwh.2014.5108.
- [31]. Wandner LD, Scipio CD, Hirsh AT, Torres CA, Robinson ME. THE PERCEPTION OF PAIN IN OTHERS: HOW GENDER, RACE, AND AGE INFLUENCE PAIN EXPECTATIONS. *The Journal of Pain*. 2012;13(3):220-227. doi:10.1016/j.jpain.2011.10.014.
- [32]. Defrin, Ruth, Libby Shramm, and Ilana Eli. "Gender role expectations of pain is associated with pain tolerance limit but not with pain threshold." *PAIN@145.1* (2009): 230-236.
- [33]. Benoist M, Boulu P, Hayem G. Epidural steroid injections in the management of low-back pain with radiculopathy: an update of their efficacy and safety. *Eur Spine J*. 2012;21:204–13.
- [34]. Manchikanti L, Buenaventura RM, Manchikanti KN, Ruan X, Gupta S, Smith HS, Christo PJ, Ward SP. Effectiveness of therapeutic lumbar transforaminal epidural steroid injections in managing lumbar spinal pain.

*Dr. Nitin Wagh. "Assessment of Efficacy of Fluoroscopy Guided Steroid Injection By Transforaminal Approach in Patients with Chronic Lumbosacral Radiculopathy." *IOSR Journal of Dental and Medical Sciences (IOSR-JDMS)* 16.07 (2017): 95-99.