

Incidental Finding of Huge Benign Ovarian Tumour in An Infertile Women : A Case Report

¹dr.N.Idaya Vani(Pg) , ²dr.Saraswathi(Hod), ³dr.Geethalakshmi

(Assistant Professor) Shree Balaji Medical College And Hospital

Abstract: Ovarian cysts frequently occur in women of reproductive age. Fertility sparing surgery should be reserved for women who desirous of future pregnancy. We present a case report of a young woman who resumed fertility following unilateral salpingo oophorectomy for an incidental finding of huge benign ovarian tumour with contralateral ovarian reserve.

Keywords: Huge, benign, ovarian tumour, infertile woman.

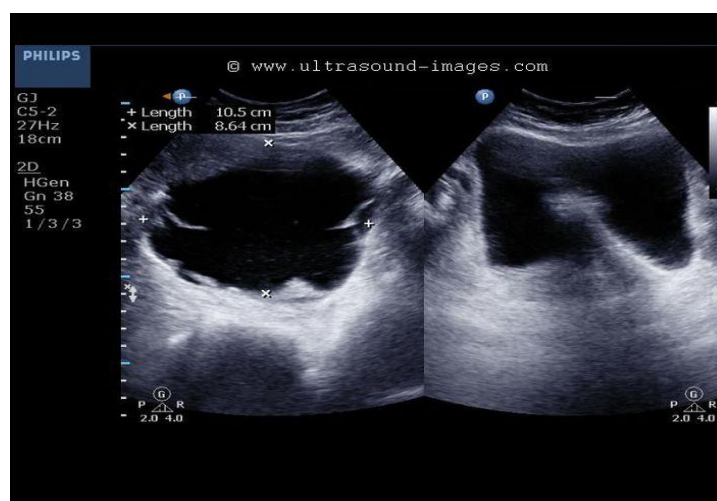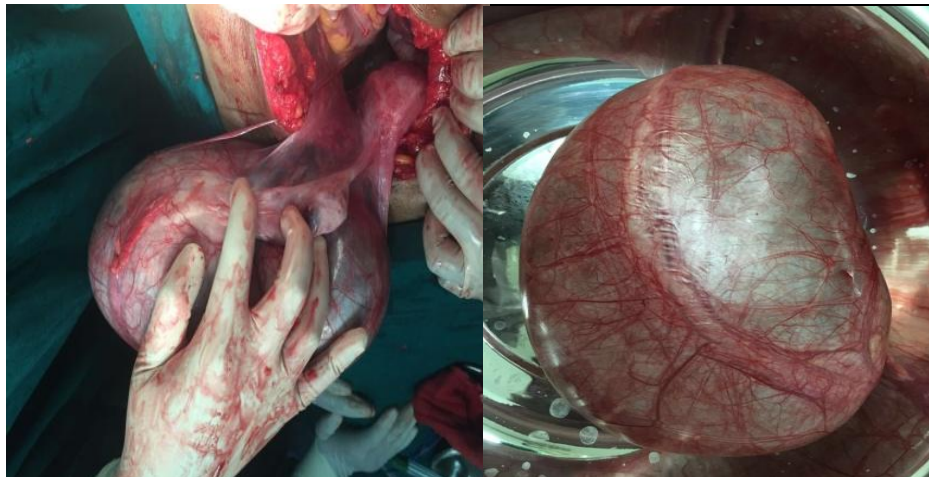
I. Introduction

Ovarian cysts in reproductive age group may be functional or non functional. Among which Endometriosis, PCOS will affect fertility. Functional cyst, corpus luteal cyst, cystadenoma, dermoid cyst are not associated with infertility. Though, Ultrasonography permits early detection and appropriate treatment. occasionally, ovarian cysts reach enormous dimensions without raising any symptoms. A few cases of giant ovarian cysts have been sporadically reported in the literature . We presented a case of a giant ovarian cyst in a 26 year old , infertile woman with characteristics of ovarian serous cyst adenoma .

Case presentation

A 26 year old Mrs.X, nulligravida, married since 3 years with regular and normal menstrual cycles presented at the outpatient department of shreebalaji medical college and hospital as a case of primary infertility with complaints of mild dragging lower abdominal pain on and off for 1 year. She was not aware of any abdominal distension. Her bowel and bladder habits were normal. She had no serious medical illness or surgeries in the past. Family history were nil significant. Her husband was non smoker and non alcoholic with normal semen parameters. Her coital history doesn't reveal any significant variation. On examination, she was moderately built and nourished with BMI 24.5 kg/m², Her systemic examination were normal. On abdominal examination, abdomen was grossly distended to 32 week of pregnant uterus size mass which is non tender, cystic , with palpable lower border and side to side mobility with no Fluid thrill. Bimanual pelvic examination showed, cervix deflected to right ,uterus retroverted normal size, cystic mass of about 32 weeks of pregnant uterus size in posterior fornix with positive groove sign. Per rectal examination no nodules. Her renal and liver parameters are within normal limits including Ca125.

Both abdominal USG and MRI, was suggestive of biloculated left ovarian cyst size 28 × 15× 8 cm with few thin internal septations, papillary projections and with internal echoes. Right ovary and Uterus was normal. Bowels were compressed by the mass, and a mild left hydronephrosis was seen. Though the clinical and sonographic parameters are more suggestive of benign, except for the huge size.. On explorative laparotomy there was a large tense, smooth- surfaced cystic mass of about 20 × 10× 8 cm was noted in the left ovary, due to the huge cyst, ovarian tissue could not be spared and hence ipsilateral oophorectomy done .Tubal patency test showed spill on right side of tube with normal right ovary .There was no free fluid in the abdomen and other visceral organs feels normal. Omentum normal. Histopathology confirmed serous benign cystadenoma of the ovary. The postoperative period was uneventful



She reported again, 4 months after her surgery, with 6 weeks of amenorrhea. Intrauterine pregnancy confirmed. Her first and second trimesters were uneventful. At 36 weeks she reported with premature rupture of membranes and She delivered an healthy baby by LSCS, done due to fetal distress.

II. Discussion

Ovarian cysts in reproductive age group may be functional or non functional. Functional ovarian cysts include follicular and corpus luteal cysts. Neoplastic tumours may be benign or malignant. Ovarian cysts are functional, benign, malignant in 24%, 70% and 6% respectively. Two third of these occur in women between 20 and 44 years. and are benign [2]. Common symptom of ovarian mass include abdominal distension, pain or discomfort and urogenital symptom. Acute pain may occur with adnexal torsion, cyst rupture or bleeding into a cyst. Masses which are unilateral, cystic, mobile and smooth are likely to be benign, whereas those that are bilateral, solid, fixed, irregular and associated with ascites, cul-de-sac nodules with rapid growth are more likely to be malignant.[1]

The ovarian serous cystadenoma is a type of benign ovarian epithelial tumour. It is the second most common cystic tumor of ovary first being benign cystic teratoma.[1,2] Serous tumour account for 20% of all ovarian tumours. The peak incidence is at 4th and 5th decades of life. Serous tumours are generally benign, 5% to 10% are borderline malignant and 20 – 25 % are malignant [1]. Depending on the amount of the fibrous tissue, it can be classified into cystadenoma, cystadenofibroma, adenofibroma, papillary cystadenoma, papillary cystadenofibroma, and papillary adenofibroma. Even couldn't find any benign serous cyst adenoma of ovary of such a huge size in an infertility women, as not be reported so far.

Pathology:

Grossly, serous tumours may be small 5-10cm in diameter, but can be as large as 30-40 cm, most are large, spherical to ovoid, cystic structures. About 25% of the benign forms are bilateral. In the benign form, the serosal covering is smooth and glistening contrast to malignant form with irregular nodularities. Serous cystadenomas are usually composed of unilocular and at times multilocular cysts filled with clear watery fluid.

Histologically the benign tumours are characterized by a single layer of tall columnar epithelium lining cyst wall. Papillary projections may be seen. Occasional Psammoma bodies can be seen in papillary projections. The Society of Radiologists in Ultrasound published a consensus statement concluding that asymptomatic simple cysts 30–50 mm in diameter do not require frequent follow-up, cysts 50–70 mm require follow-up, and cysts more than 70 mm in diameter should be considered for either further imaging (MRI) or surgical intervention due to difficulties in examining the entire cyst adequately at time of ultrasound.

Tumor markers:

CA125, In the reproductive-age, rises in many conditions such as fibroids, endometriosis, adenomyosis and pelvic infections. Ca 125 is more significant in predicting epithelial ovarian malignancy in a postmenopausal woman than in a premenopausal woman .

Management:

Even a benign ovarian tumour more than 7 cm requires removal ,otherwise it may grow in size, undergo complication or turn malignant. Though some guide lines suggested laparoscopy for a huge ovarian cyst which has its known advantages, but it requires a well expertees with the risk of rupture and spillage of the contents of the cyst due to limited workspace and need for a secondary surgery if ovarian malignancy is diagnosed.

III. Conclusion

The dictum of management of ovarian cyst in infertile women is to preserve the ovarian tissue as far as possible. Before giving definitive treatment, preoperative counseling regarding the future fertility, if we pushed to go for a complete removal of ovary in a benign ovarian cyst with an infertile women.

References

- [1]. Helm, C.W. (2012) Ovarian Cysts, Medscape.<http://emedicine.medscape.com/article/255865-overview#showall>
- [2]. ACOG Practice Bulletin (2007) Management of adnexal masses. *Obstetrics and Gynecology*, 110, 201-214.
- [3]. Teichmann, A.T., et al. (1995) The influence of the dose of ethinylestradiol in oral contraceptives on follicle growth. *Gynecological endocrinology: The Official Journal of the International Society of Gynecological Endocrinology*, 9, 299-05. doi: 10.3109/09513599509160463
- [4]. Qublan, H.S., et al. (2006) Ovarian cyst formation following GnRH agonist administration in IVF cycles: Incidence and impact. *Human reproduction*, 21, 640-644. doi:10.1093/humrep/dei371
- [5]. Nelson-Al, G.J. (2010) Congenital anomalies and benign conditions of the ovaries and fallopian tubes. In: Hacker, N.F., Gambone, J.C. and Hobel, C.J., Eds., *Hacker and Moore's Essentials of Obstetrics and Gynecology*, 5th Edition, Saunders, Philadelphia, 248-255.
- [6]. Beckmann, L.F. and Smith, R.P., et al. (2006) Ovarian and adnexal disease. In: Beckmann C.R.B., Ling F.W., Smith R.P., et al, Eds., *Obstetrics and Gynecology*, 5th Edition, Lippincott Williams & Wilkins, Philadelphia, 464-476.
- [7]. GREEN TOP GUIDELINE 14th edition Novaks 14th edition Shaw 16th edition