

Aberration in Branching Pattern of Hepatic Artery: A Case Report

Mamata Sar¹, Srikanta Kumar Mishra², Sarita Behera³,
Manoj Kumar Dehury⁴

(Department Of Anatomy, VSS Institute Of Medical Science And Research, Odisha, India,

Abstract:

Aim: To study the hepatic vascular anatomy and to find out aberration in its origin, course, branching pattern or in the anatomical relation with accompanying structures.

Method: During routine dissection in a 50 year old male cadaver we dissected out all the three branches of celiac trunk all through their course. As the hepatic artery was found to have a different mode of branching we traced the artery till its destination in to liver parenchyma and studied its course and relations with adjacent structures.

Results: Hepatic artery was normal in its origin from celiac trunk. There was no replaced or accessory hepatic artery. But in contrast to the normal mode of termination of a proper hepatic artery into right and left hepatic artery near the porta hepatis we found the artery dividing very close to its origin. As a result the left and right hepatic artery traversed a long distance in the lesser omentum to reach the porta hepatis. They occupied the left lateral and right lateral position in the lesser omentum with relation to the portal vein and bile duct.

Discussion: Variations in hepatic arterial anatomy are important because they greatly influence the surgical and interventional radiological procedures.

Keywords: Bile duct, Celiac trunk, hepatic artery, Portal vein, porta hepatis

I. Introduction

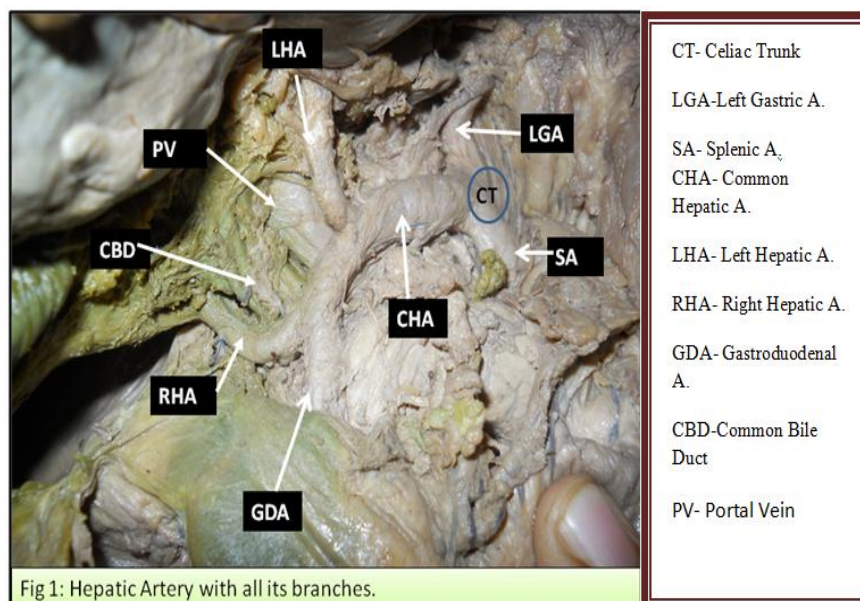
Hepatic arterial anomalies are not rare. A large number of studies have been undertaken on variant patterns of aberrant hepatic arteries because of its high surgical relevance. Some studies have shown the incidence of aberrant hepatic arteries to be as high as almost 50 %. All the studies done earlier were on aberrant origin of hepatic artery and we did not find any report on abnormal branching pattern of the artery. During routine dissection we had this accidental finding of abnormality in branching pattern of the hepatic artery with altered relations and course of its branches. A comprehensive understanding of common and uncommon variations in hepatic arterial system is very much essential for the surgeons to avoid any potentially disastrous complication. Knowledge on this abnormal anatomy will be helpful to avoid injuring the arteries during surgeries like pancreaticoduodenectomy in patients with ampullary tumor.

II. Methods

During routine dissection in a 50 year old male cadaver while dissecting celiac trunk and its branches we found left hepatic artery being given up from common hepatic artery immediately after its origin from celiac trunk. As this is a deviation from normal branching pattern we dissected the artery throughout its extra hepatic course and looked for the site of origin of other branches like gastro duodenal, right gastric and cystic artery. We examined the relation of the arteries with major structures like bile duct and portal vein. We also searched for other common aberrations like, accessory hepatic arteries and replaced hepatic arteries. We compared our findings with previous reports and tried to find out its embryological and surgical significance.

III. Case Report

The celiac trunk was in its usual position and trifurcated into left gastric, splenic and hepatic artery. The course, relation and branching pattern of left gastric and splenic arteries were normal. The common hepatic artery, after a short distance from its origin gave its first branch which passed upward through the lesser omentum to porta hepatis. This artery was identified to be the left hepatic artery which instead of arising from proper hepatic artery was a direct branch of common hepatic artery. It gave a branch to the gall bladder before entering into porta hepatis. The hepatic artery passed horizontally to the right to the upper border of first part of duodenum. Here it crossed the portal vein and bile duct anteriorly and then bifurcated into gastroduodenal and right hepatic artery. The right hepatic artery ascended in the free margin of lesser omentum with portal vein and bile duct up to the porta hepatis. In the free margin of lesser omentum it was present on the right side of bile duct. Just before entering into porta hepatis it supplied the gall bladder through cystic artery (Fig 1)



IV. Discussion

The hepatic artery is subdivided into common hepatic artery, from the celiac trunk to the origin of gastroduodenal artery and proper hepatic artery from that point to its bifurcation. Normally proper hepatic artery runs in the free margin of lesser omentum on the left side of bile duct and terminates near the porta hepatis by dividing into right and left hepatic artery. So the right and left hepatic arteries have a very short extra hepatic course. In the present case the division occurred very early, even before the origin of gastroduodenal artery. So both right and left hepatic arteries traversed a long distance in the lesser omentum to reach the porta hepatis. Normally occurring hepatic arterial anomalies are described as either accessory or replaced hepatic arteries. A vessel that supplies a lobe in addition to its normal vessel is defined as an accessory artery. A replaced hepatic artery is a vessel that does not originate from an orthodox position and provide the sole supply to that lobe¹. The present case is neither a case of accessory or replaced hepatic artery. Here there is no variation in origin of the artery but the branching pattern, course and relations are abnormal. John A Stauffer et al have described in detail the course and relations of replaced and accessory right and left hepatic artery. According to them a replaced right hepatic or replaced common hepatic artery lie on the right side in the hepatoduodenal ligament posterolateral to the common bile duct². The same has also been described by Carmine M Volpe et al , Woods MS et al and Biehl TR et al^{3 4 5} . In the present case the relation of the artery to the bile duct in the hepatoduodenal ligament was like that of a replaced right hepatic artery.

Normal variations are important to be demonstrated angiographically before any hepato biliary pancreatic and liver transplantation surgery, because accidental ligation of aberrant hepatic arteries may result in hepatic necrosis, ischemic biliary injury , graft injury or breakdown of biliary enteric anastomosis⁶ . The present case is neither a case of accessory or replaced hepatic artery but the longer course and the altered relation with biliary system may make it vulnerable to injury during surgery. To our knowledge this type of hepatovascular abnormality has not been reported earlier. So we feel that surgeons should also be aware of such rare possibilities to avoid any intraoperative vascular injury.

References

- [1]. Standring S.Gray's Anatomy.The Anatomical Basis Of Clinical Practice . 40th ed.London:Elsevier , Churchill Livingstone Edinburg ; 2008 :1169
- [2]. John A Stauffer , Mellena D Bridges , Naciya Turan .Aberrant right hepatic arterial anatomy and pancreaticoduodenectomy , recognition , prevalence and management . journal of Hepato Pancreatic Biliary Association 2009;11(2):161-165 .
- [3]. Volpe C M ,Peterson S ,Hoover E L . Justification For Visceral Angiography Prior to Pancreaticoduodenectomy . The American Surgeons 1998 ;64:758-761
- [4]. Woods M S ,Traverso L W . Sparing a replaced common hepatic artery during Pancreaticoduodenectomy . Am Surg 1993;59:719-21
- [5]. Biehl T R,Traverso L W .Preoperative angiography alters intraoperative strategy during the Whipples procedure . Amj Surg 1993 ; 165: 607-12
- [6]. Feng Yang ,Jiang Long , De Liang Fu ,Chen Jin .Aberrant Hepatic Artery in patients undergoing Pancreaticoduodenectomy . Pancreatology 2008 ; 8: 50-54