

Traumatic Dislocation of the Hip Associated To Ipsilateral Femoral Shaft Fracture in a Racing Driver

Nabil Kassou, Aimane Naam*, Badr El Alami, Saeed Abdulrazak,
Amine Marzouki, Kamal Lahrach, Fawzi Boutayeb

Department of Trauma and Orthopedic Surgery A, Hassan II University Hospital, Faculty of medicine and pharmacy Sidi Mohamed Benabdellah University, Morocco, Fes

Main authors: Nabil Kassou, Aimane Naam

Author in 2nd position: Badr El Alami

Abstract: *The incidence of traumatic dislocation of the hip associated with femoral shaft fracture on the same side is rare. It meets with two main problems: diagnosis and treatment.*

We describe in this paper a special case which was treated with closed reduction of the hip and ORIF of the femoral shaft with a dynamic compression plate.

Keywords: *femoral fracture, hip dislocation, ipsilateral*

I. Background

Fracture of the femoral shaft combined with hip dislocation on the same side is rare occurrence [1, 2]. This presentation is important because surgeons find problems at two levels. First how to not miss the hip dislocation and the second is how to treat the injury at time. We report a case of traumatic dislocation of the hip with ipsilateral femoral shaft fracture in a 25 years old male which was treated with closed reduction of the hip and ORIF of the femoral shaft with a dynamic compression plate.

II. Case report

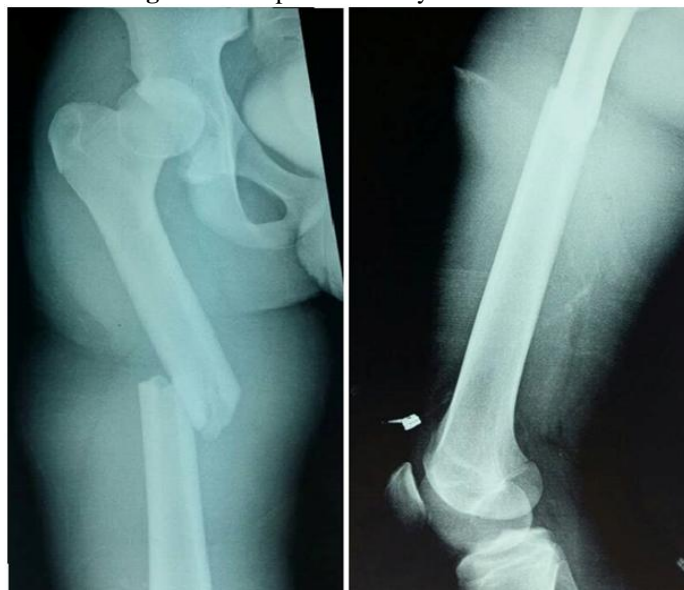A youth of 25, a racing driver was admitted to hospital in a shocked state with severe injuries due to a road accident during a race competition.

The patient presented with pain and deformity of the left hip and thigh.

The patient was admitted to the intensive care unit of the emergency ward. Then he was clinically examined. The hip was in attitude of flexion and adduction and leg was in attitude of external rotation. There was no distal neurovascular deficit of the left lower limb. Swelling and abnormal mobility in the thigh were noticed.

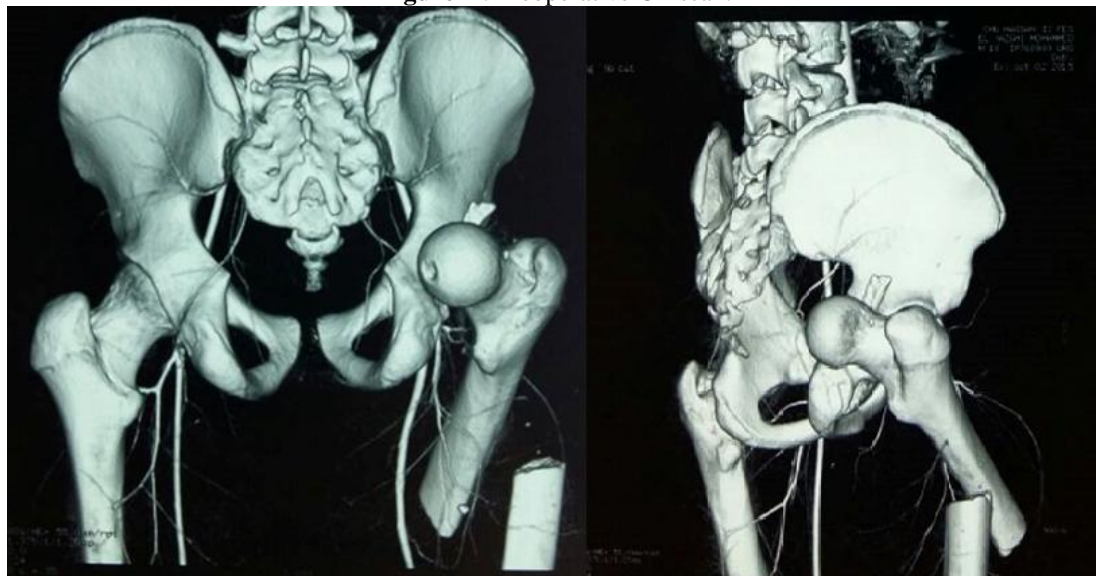
After being stabilized, the patient went to the radiology service. X-rays were taken of both hips and femoral shaft of the left side (**figure 1**).

Figure 1: Preoperative X-ray examination.



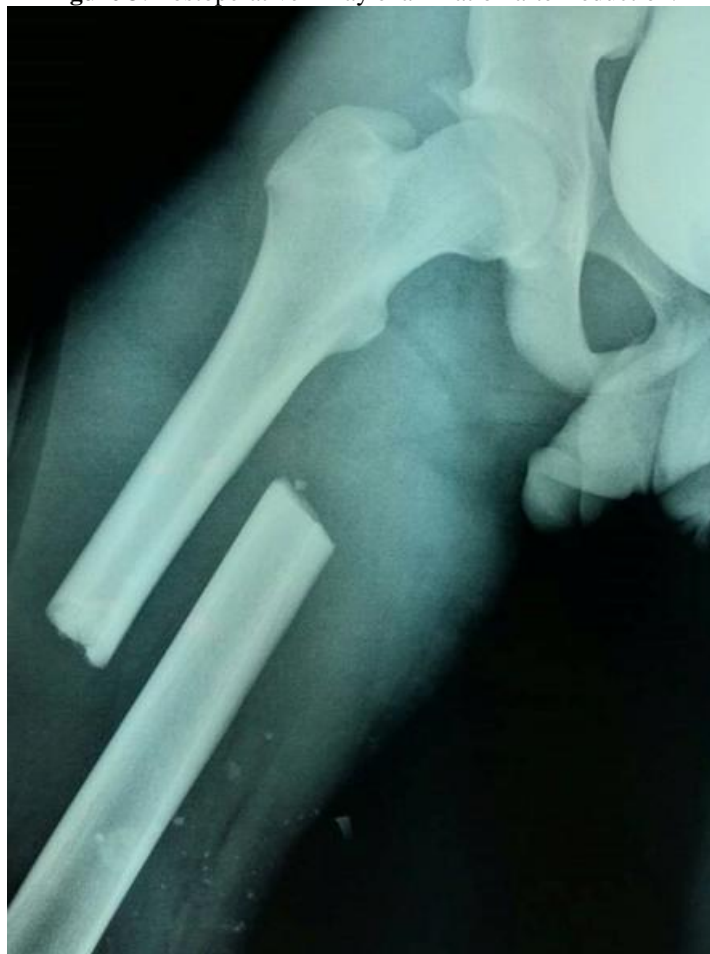To exclude any hip fracture a CT scan was performed showing a small posterior fragment (**figure 2**).

Figure 2 : Preoperative CT scan.



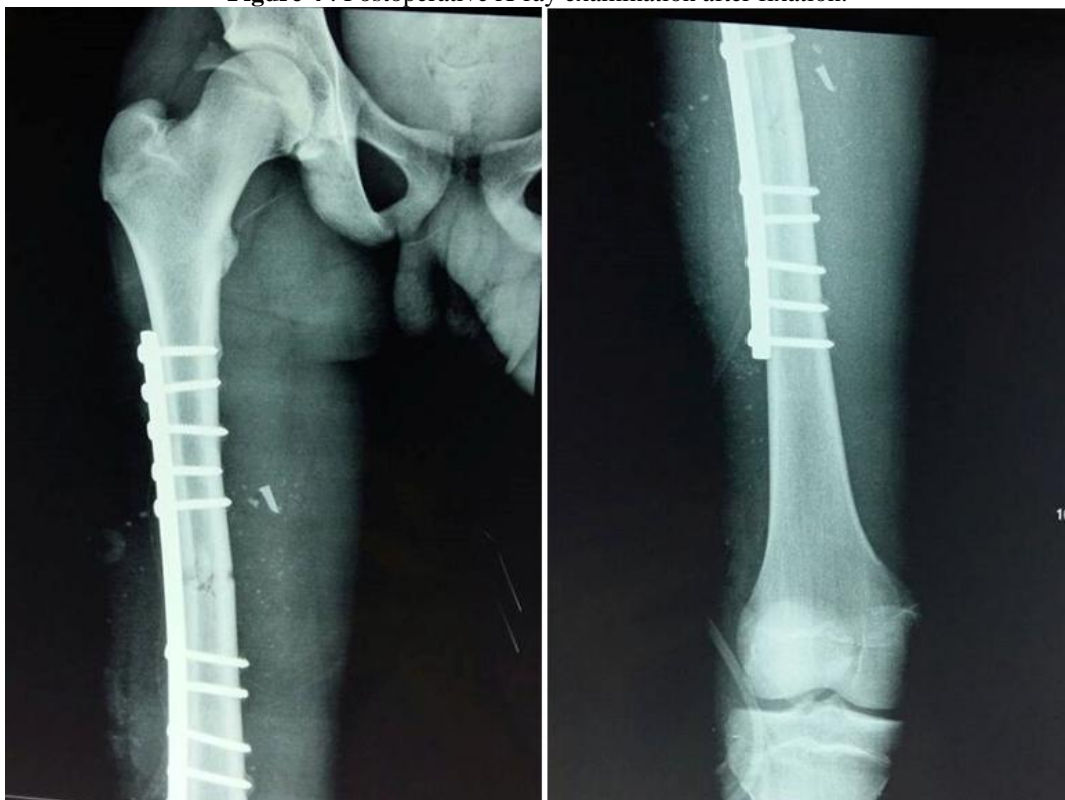Few minutes after we have taken the patient to the operating room and under general anesthesia an attempt of closed reduction of the left hip was tried according to Böhler manipulation and it was surprisingly successful. Reduction was confirmed by an x-ray of the left hip (**figure 3**).

Figure 3: Postoperative X-ray examination after reduction.



Next day we admitted the patient again to the Operating room. This time an open reduction and internal fixation of the left femoral shaft was realized using a lateral thigh approach and a dynamic compressing plate. The x rays of control showed an anatomic reduction of the fracture and the hip was in place (**figure 4**).

Figure 4 : Postoperative X-ray examination after fixation.



Post operatively the lower limb was immobilized in a Zimmer splint with hip in abduction. The patient was administered ketoprofen 100 mg and enoxaparin to prevent DVT deep vein thrombosis. He was followed with serial X-rays of hip and femur shaft. He used axillary crutches to walk with no weight bearing instruction for the first month. Progressively partial weight bearing was authorized till the fourth month. At the end of the fifth month we gave him permission of full weight bearing with a good range of movements. Our patient was undergoing sessions of physiotherapy at special center.

III. Discussion

Traumatic hip dislocation with femoral shaft fracture in the same side is extremely rare [1, 2]. The surgeons face two major problems concerning this type of injury in which the mechanism is a complex one according to cadaveric studies that proved that the dislocation happened first because of an axial force then the shaft fracture is produced by a lateral force that comes in the second place [3].

This two problems consist in:

First, how to be aware of the hip dislocation even if the shaft fracture of the femur can led us to miss this important diagnosis.

The second thing, if the diagnosis is early made how to reduce the hip and should we began with treating the femoral shaft first then the hip or the opposite.

After reviewing literature we found that the time it takes to diagnosis dislocation can vary widely [4].

Detzel on 1953 described a patient in whom the diagnosis of the dislocated hip was made five years after the injurie [3].

Meticulous analysis of clinical and radiographic examination can be of very great help reducing the delay.

Clinically two main signs were given by Helal and Skevis: elevation of the trochanter, palpable proeminence of the femoral head in the buttock and bruising of the buttock [3].

Radiographically, when we found a transverse fracture of the femoral shaft and the proximal shaft fragment is adducted, a diagnosis of the posterior dislocation of the hip must be made.

For the treatment no one had made an established approach or an effective algorithm for dealing with this combined injury.

According to several authors various techniques were used: Smith traction screw device inserted into the femoral neck or screwed up the medulla of the proximal shaft [5-9].

The open reduction was only used when the closed methods failed or a *sciatic nerve palsy* was detected [10].

As we succeeded in hip reduction just by external maneuver we found that only 29,43% of cases where the diagnosis is made early are likely to respond favorable for this technique [5]. Other authors described an interesting technique in which a transfixing Steinman pin was introduced in the great trochanter then manipulation of the femoral head was done in order to reduce the posterior hip dislocation [3].

IV. Conclusion

Hip dislocation with ipsilateral fracture shaft femur is a rare occurrence. This type of injury is unique due to the difficulties encountered in diagnosis and treatment. Majority of such injuries are missed diagnosis primarily, hence great awareness of such combined injuries coupled with a thorough clinical and radiological assessment aids in diagnosing such fracture. Early diagnosis of such injury and early treatment of such cases is advised for a good functional outcome.

Authors' Contributions

All authors contributed either directly or indirectly in the writing and general format of this article.

Competing interest

The authors declare that they have no competing interests.

Main authors: Nabil Kassou, Aimane Naam

Author in 2nd position: Badr El Alami

References

- [1]. Sir Cooper A. A treatise on dislocations and on fractures of the joints: fractures of the neck of the thigh-bone. 1823. Clin Orthop Relat Res. 2007 May;458:6-7.
- [2]. Wiltberger BR, Mitchell CL, Hedrick DW. Fracture of the femoral shaft complicated by hip dislocation; a method of treatment. J Bone Joint Surg Am. 1948 Jan;30A(1):225-8.
- [3]. Helal B, Skevis X. Unrecognised dislocation of the hip in fractures of the femoral shaft. J Bone Joint Surg Br. 1967 May;49(2):293-300.
- [4]. Schoenecker PL, Manske PR, Sertl GO. Traumatic hip dislocation with ipsilateral femoral shaft fractures. Clin Orthop Relat Res. 1978 Jan-Feb;(130):233-8.
- [5]. Dehne E, Immermann EW. Dislocation of the hip combined with fracture of the shaft of the femur on the same side. J Bone Joint Surg Am. 1951 Jul;33-A(3):731-45.
- [6]. Henry AK, Bayumi M. Fracture of the femur with luxation of the ipsilateral hip. Br. J. Surg. 1934 22,204.
- [7]. Epstein HC. Posterior fracture-dislocations of the hip; long-term follow-up. J Bone Joint Surg Am. 1974 Sep;56(6):1103-27.
- [8]. Watson-Jones, Sir R.: Injuries of the hip. In Wilson, J. N (ed.) Fractures and Joint Injuries. Ed. 5. New York. Churchill Livingstone Co. 1976; p. 908.
- [9]. Shannak AO. Bilateral traumatic dislocation of the hips with ipsilateral femoral fracture. Clin Orthop Relat Res. 1987 Feb;(215):126-9.
- [10]. Chirag TN, Chetan Puram, Atul Patil, Steve Rocha, Ashok K Shyam, Parag K Sancheti. Traumatic dislocation of hip with ipsilateral femur shaft fracture – A case report. Journal of Orthopaedics and Rehabilitation. 2011 Jan ; 1(1) :125-126