

Spontaneous Rupture of Ventral Hernia: A Rare Presentation

Dr.Srilekha Reddy G¹, Dr.Dinesh B V², Dr.Ramachandra L³

¹(Junior resident, Department of surgery, Kasturba medical College, Manipal University, India)

²(Associate Professor, Department of surgery Kasturba medical college, Manipal University, India)

³(Professor and head of the Department of surgery Kasturba medical college, Manipal University, India)

Abstract: *Of the many complications of a ventral hernia, spontaneous rupture is seldom encountered. It is more common among cirrhotics and is extremely rare otherwise, with few documented cases. A 45 year old lady with a long standing incisional hernia with COPD sustained spontaneous rupture with herniation of ileal loops and complete transection at distal ileum. Patient required ileal resection and primary closure was possible. She improved well was tolerating oral feeds and was ambulating by eleventh post operative day. Our case was complicated by a spontaneous transection, an extremely rare and unique scenario.*

Keywords: *Complication, Hernia, Spontaneous rupture, Ventral, Incisional*

I. Introduction

Spontaneous rupture of ventral incisional hernias are a rare albeit not unheard of complication. It is seldom encountered. There are 9 reported cases of spontaneous rupture of incisional hernia. Patients often have an associated predisposing factor such as COPD. Spontaneous rupture of umbilical hernia is more common in cirrhotics.

II. Case report

45 year old lady presented to casualty with sudden spontaneous rupture of abdomen following a bout of cough. She also complained of loose stools for past 3 days, no history of constipation or abdominal distension. She is a known case of COPD on treatment and suffers from chronic cough and asthmatic episodes. Patient was on oral corticosteroids for the same. She underwent a ventral hernia repair 15 years back and mesh repair of hernia was done. Patient appeared to be well preserved and was conscious at presentation. On examination she had hypotension (blood pressure- 90/60 mm Hg) and tachypnea (respiratory rate- 29/min), pulse was normal (86 /min) Per abdomen a 8x 6 cm infraumbilical abdominal defect with protrusion of congested small bowel loops from a hernia nearly 13 x 10 cm large was noted.

Transected ends of small bowel were visible at superior portion of defect. Abdominal wall skin was thinned out with areas of maceration over the suprapubic region and right iliac fossa, signs of chronic herniation and neglect of underlying skin. Transparent suture material was noted protruding at infraumbilical midline. Patient was started on 100% oxygen supplementation. Bowels were covered with sterile pads and patient was taken up for an emergency exploratory laparotomy. An incision was placed along midline on either sides of defect. On examination nearly 30 cm of ileum was noted to have herniated through the abdominal defect. Distally herniated segment was about 10 cm from ileocaecal junction. Two separate 5 cm segments of ileum with clean transected ends were noted protruding through a separate fascial ring. A large ventral fascial defect of 15 x 8 cm vertically extending beyond skin defect was noted. A resection and anastomosis of herniated ileum was done in view of ischemic changes, and an ileoascending anastomosis was performed. A pelvic drain placed and abdomen closed in layers. Mesh repair was deferred in view of contamination of field. Rectus sheath approximated with intermittent no.1 prolene sutures.

Post-operative recovery was uneventful. She received bronchodilators and corticosteroids for COPD. Oral feeds were started on post-operative day 5. Laparotomy wound healed well. She was ambulating and tolerating normal diet by post-operative day 11.

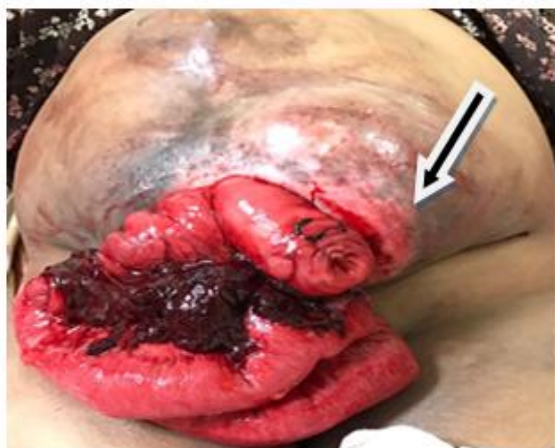

Figure 1

Figure 1 : Eviscerated ileal loops with a visible transected end (marked with arrow). Clot over mesentery

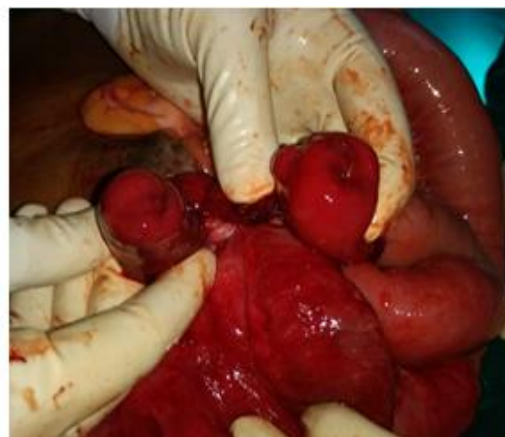

Figure 2

Figure 2 : Both ends of ileal transection.

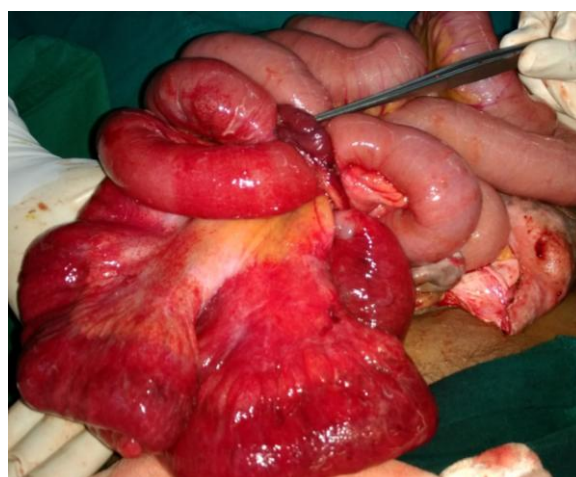


Figure 3

Congested eviscerated distal ileum, was found to be non-viable, resection was done. Note fascial ring (instrument pointed at it) through which the transected ileal ends were protruding.

IV. Discussion

Spontaneous rupture of ventral hernia is a very rare complication in non-cirrhotic population with few reported cases ^[1-9]. It is seen with recurrent groin hernia repair or incisional hernia repair in patients with predisposing factors like chronic cough, where there is a sudden increase in intra-abdominal pressure precipitating rupture ^[9]. It usually occurs in a neglected hernia with thinned out skin and weak abdominal wall. Due to ulceration or sudden raise in intra-abdominal pressure hernia can rupture. The condition is preventable with early surgical intervention for the hernia repair. In such chronic hernias due to loss of domain repositioning bowel contents intra-abdominally may complicate with abdominal compartment syndrome, and special closure techniques like laparostomy or component separation may be necessary. However our case was complicated by a spontaneous transection of ileum, herniated ileum which was not viable was resected and closure could be achieved without tension. A mesh repair was not possible due to contaminated field.

V. Conclusion

Spontaneous rupture of a neglected ventral hernia is a rare complication, this scenario was complicated by an associated spontaneous transection of the herniated ileum. This situation needs emergency surgery and the post-operative course is complicated by comorbidities such as COPD which can be exacerbated by superimposed abdominal compartment syndrome.

References

- [1]. Von Helwig H. Uber sonenannte spontaneous rupture von hernien. Schweiz med wschr 1958;88:662–6
- [2]. Hartely RC. Spontaneous rupture of incisional hernia. Br J surg 1961;49:617–18
- [3]. Hamilton RW. Spontaneous rupture of incisional hernia. Br J Surg 1966;53:477–79
- [4]. Aggarwal P K. Spontaneous rupture of incisional hernia. Br J Clin Pract 1986;40:443–4
- [5]. Singla SL, Kalra U, Singh B, et al. Ruptured incisional hernia. Trop Doct 1997;27:112–13
- [6]. Ogundiran TO, Ayantunde AA, Akute OO. Spontaneous rupture of incisional hernia—a case report. West Afr J Med 2001;20:176–8
- [7]. Sagar J, Sagar B, Shah DK. Spontaneous rupture of incisional hernia. Indian J Surg 2005;67:280–1
- [8]. Gupta, R., S, S. and S C, A. (2011). Spontaneous rupture of incisional hernia: a rare cause of a life-threatening complication. Case Reports, 2011(mar02 1), pp.bcr1120103486-bcr1120103486.
- [9]. Martis JJS, Shridhar KM, Rajeshwara KV, Janardhanan D, Jairaj D. Spontaneous Rupture of Incisional Hernia—A Case Report. The Indian Journal of Surgery. 2011;73(1):68-70. doi:10.1007/s12262-010-0136-y