

## Minimally Invasive Thoracoscopic Procedures - A Single Centre Experience

Rengarajan R<sup>1</sup>, Dr.Muthulingam V<sup>2</sup>, G Rajamani<sup>3</sup>, Raghul M<sup>4</sup>  
<sup>1,2,3,4</sup>(Coimbatore Medical College Hospital, Coimbatore, India)

**Abstract :** VATS is principally employed in the management of pulmonary, mediastinal, and pleural pathology. Its main benefit has been the avoidance of a thoracotomy incision, which allows a shorter operating time, less postoperative morbidity, and earlier return to normal activity than with thoracotomy. Video-assisted thoracoscopic surgical (VATS) procedures are very safe and efficacious in paediatric patients of all age groups. Our study was undertaken to analyse the usefulness of thoracoscopy in Paediatric population in the management of various thoracic pathologies in relation to its feasibility, safety, efficacy and reliability and to compare its advantages over thoracotomy in relation to post operative pain, recovery, morbidity and cosmesis. This study retrospectively analysed the records of patients who had undergone thoracoscopic procedures for various pathologies during January 2001 to December 2015 at the Department of Paediatric Surgery, Coimbatore Medical College Hospital. The study population included cases of Empyema thoracis, Pyopericardium, Congenital Diaphragmatic hernia (CDH), Eventration, Bronchogenic cyst, Foregut Duplication Cyst, Lymphoma, Tracheo Esophageal Fistula. A total of 60 patients were included. Operating time, conversion rate, post operative intercostal drainage tube time, post operative recovery and complication rates were assessed. Thoracoscopy was found to be definitely superior to thoracotomy in the management of Empyema thoracis in relation to pain relief, morbidity, early recovery and requirement of blood transfusion. Pyopericardial patients had better cosmetic results. Thoracoscopy helps better in sick children and the yield of mediastinal biopsy was extremely high. Cystic lesions of the lung were excised safely. Procedure like thoracoscopic esophageal atresia repair needed more operative time and expertise with specialized instruments. Complications encountered in thoracoscopy are usually minor.

**Keywords:** decortication, empyema thoracis, esophageal atresia, Video-assisted thoracoscopic surgery, VATS

### I. Introduction

Video-assisted thoracoscopic surgical (VATS) procedures are being used in children since 1970s. With the advent of smaller endoscopic instruments and improvement in video technology, more VATS procedures are being performed. These procedures are very safe and efficacious in paediatric patients of all age groups including newborns. Initially, the usefulness of thoracoscopy was limited to only biopsies, decortication and deroofting of pulmonary cyst. Today, more than 20 types of VATS procedure are introduced in infants and children. They mainly deal with disease of esophagus, lungs, mediastinal tumors, diseases of the diaphragm, pleura and pericardium. VATS obviously has certain advantages such as superior cosmetic results, prevention of functional disorders of the thorax, lesser post-operative pain and faster recovery. Endosurgery has a considerable learning curve. Future of the thoracoscopy in children depends upon creation of better and new instruments. With this background, the present study is intended to analyse, various thoracoscopic procedures performed in our institution, and examine the merits and demerits of this procedure.

### 2. Aims of the study

To analyse the usefulness of thoracoscopy in Paediatric population in the management of various thoracic pathologies in relation to its

Feasibility

Safety

Efficacy

Reliability

### To compare its advantages over thoracotomy in relation to

Post operative pain

Recovery

Morbidity

Cosmesis

To compare our results with other studies.

## II. Materials And Methods

**3.1 Design:** This is a retrospective and prospective study analyzing various procedures performed at **Coimbatore Medical College Hospital** and the outcome of the various procedures were evaluated.

**3.2 Study period:** This study retrospectively analysed the records of patients who had undergone thoracoscopic procedures for various pathologies during **January 2001 to December 2015**.

**3.3 Study center:** Study carried out at the Department of Paediatric Surgery, **Coimbatore Medical College Hospital**.

**3.4 Subject:** Totally 60 patients had undergone either diagnostic or therapeutic thoracoscopic procedures at our department during the study period.

### 3.5 Instruments Used:

Zero and 30 degree 4 mm telescope (Karl Storz)

30 degree 10 mm telescope (Karl Storz)

Diathermy : Martin/Aesculop

Light source : Halogen

Camera : (Karl Storz)

Insufflator : CO<sub>2</sub> – automatic

Monitor

Video recorder

### 3.6 Hand instruments:

Interchangeable with laparoscopic procedures

### 3.7 Technique:

All patients who were investigated and confirmed of their diagnosis were taken up for therapeutic procedures. All patients received general anaesthesia, controlled ventilation.

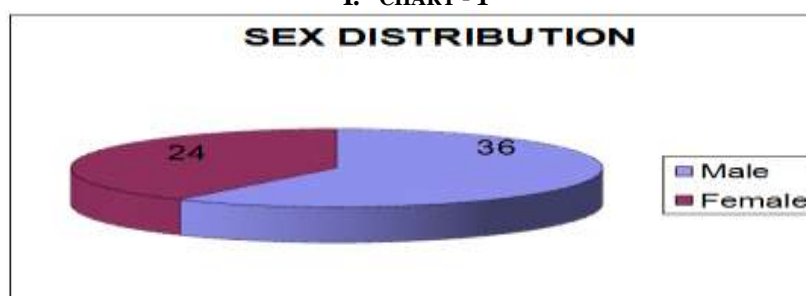
## III. Results and Discussion

Lateral decubitus position with the side of the pathology remaining upwards. Dual lung ventilation used. Pneumothorax created with CO<sub>2</sub> or atmospheric air. Number of ports varied according to the pathology and as operative analgesia as per need. No specialized instruments used. All patients received chest tubes following the procedure. Post The present study analyses various thoracoscopic procedures done in our Department and has reviewed the outcome of various procedures.

Total number of case – 60.

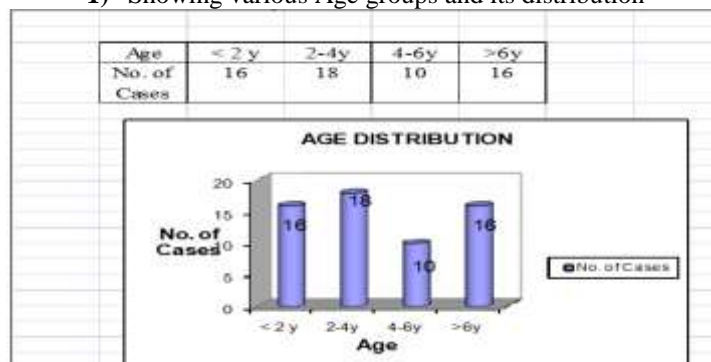
Diagnosis	Procedure	No. of patients
Empyema thoracis	Diagnostic thoracoscopy & Open decortication	16
Empyema thoracis	Thoracoscopic debridement	24
Pyopericardium	Window pericardiectomy	6
CDH	Repair	4
Eventration	Plication	2
Bronchogenic cyst	Excision	2
Foregut Duplication Cyst	Excision	2
Lymphoma	Mediastinal node biopsy	2
TEF	Repair	2

I. CHART - 1



II. CHART – 2

1) Showing various Age groups and its distribution



B.

**4. 1. Empyema thoracis:**

Number of patients treated - 40

This study has reviewed the records of 40 patients who were diagnosed as pyothorax. Most of the patients were received from corresponding medical unit or referred from other hospitals as empyema thoracis.

**4.1.1 Procedure:** Patient received general anaesthesia, endotracheal tube with controlled ventilation. Patient placed in lateral decubitus position with diseased side upwards.<sup>[1,2]</sup> Patient received two to four ports according to the needs. Depending on the stage of the disease either thoracoscopy alone or thoracoscopy followed by open thoracotomy was done if fibrothorax was present. Intercostal drain placed through one of the port sites Pus sent for routine examination and culture. ICD removal done after three to five days. Follow-up chest x-rays taken.

- The average duration of ICD - 3.7 days
- Post op Analgesia - 2.5 days
- Ambulation - 3.1 days

**4.2 Pyopericardium:**

**Number of patients:** 6 This study has analysed three patients with pyopericardium managed thoracoscopically by the way of window pericardiectomy. All the three patients were investigated and evaluated with chest X-ray, ECG and Echo cardiography and found to have moderate amount of pericardial collection. Patient was posted in an elective list. None of the procedure was done in the semi emergency setting.

**4.2.1 Procedure:** GA, with endotracheal tube, conventional method, lateral decubitus position, left side up, three ports introduced, 10mm camera port in two patients and 4 mm camera port in one. Two working ports (5mm) in fourth intercostal space were introduced. Adhesions between lung, pericardium and chest wall were removed. One patient had purulent material in the pleural cavity as well, which was removed. Pericardium was fenestrated with the help of scissors. Pus drained, window was made bigger with the help of monopolar diathermy. Pleural cavity drained by chest tube. Post operative period was uneventful.

ICD kept for 3 days

Analgesic requirement 2.3 days

Ambulation 3 days.

**4.3 Congenital Diaphragmatic Hernia (Bockdolek):**

**Number of patients:** 4

This study has retrospectively analysed the records of two patients who were managed by thoracoscopic repair. One was a newborn presenting with respiratory distress and the other was a 4 year old presenting with recurrent respiratory tract infection.

**4.3.1 Procedure:** GA, endotracheal tube, controlled ventilation, conventional anaesthesia, in lateral decubitus position, left side up, three ports used. 4mm and 10mm camera ports were used in the newborn and the 4 year old respectively. A fourth port introduced without trocar for holding sutures. Contents were reduced with pneumothorax and with forceps. Mobilisation of the posterior lip was done and repair done with 3-0 ethibond continuous sutures and 2-0 ethibond interrupted reinforcing sutures. ICD kept.

**4.4 Eventration of diaphragm:**

**Number of patients: 2** This study has retrospectively analysed the records of one patient who was managed by thoracoscopic plication of right diaphragm. Patient had presented with recurrent respiratory infection. Diagnosis was confirmed by x-ray chest and CT.

**4.4.1 Procedure:** GA, endotracheal tube, controlled ventilation, conventional, in left lateral decubitus position, three ports used. 10 mm camera port, and two 5 mm working ports used. Pneumothorax created upto 8 mm. Diaphragm plicated with 3-0 prolene continuous sutures. ICD kept.

**4.5 Bronchogenic cyst:**

**Number of patients: 2** This study has retrospectively analysed the records of one patient who was managed by thoracoscopic excision. Patient has presented with fever and respiratory infection. Diagnosed with chest X-ray and CT scan.

**4.5.1 Procedure:** GA, endotracheal tube, controlled ventilation, conventional, in left lateral decubitus position, three ports used. 10 mm camera port, and two 5 mm working ports. Pneumothorax created upto 8 mm. Thoracic cyst found in the right apex. Purulent material aspirated. Cyst dissected all around, decompressed and excised using diathermy. No communication to bronchus noted. ICD kept.

**4.6 Foregut duplication cyst:**

**Number of patients: 2** This study has analysed the records of one patient who was managed by thoracoscopic excision. Patient has presented with recurrent respiratory tract infection and severe dyspnoea. Investigated with chest X-ray and CT scan which showed cystic lesion in the mediastinum.

**4.6.1 Procedure:** GA, endotracheal tube, controlled ventilation, conventional, in left lateral decubitus position, three ports used. 10 mm camera port, and two 5 mm working ports. Pneumothorax created upto 8 mm. Mediastinal pleura opened. Cyst aspirated. Cyst wall grasped and completely excised with diathermy. No communication to esophagus noted. ICD kept.

**4.7 Mediastinal Node biopsy:**

**Number of patients: 2** This study has retrospectively analysed the records of one patient who was managed by thoracoscopic node biopsy. Patient has presented with persistent fever. Investigations were non-contributory except for CT chest showing mediastinal widening.

**4.7.1 Procedure:** GA, endotracheal tube, controlled ventilation, conventional, in left lateral decubitus position, three ports used. 10 mm camera port, and two 5 mm working ports. Pneumothorax created upto 8 mm. Mediastinal pleura opened. Enlarged lymph nodes identified and dissected. Node removed in toto. ICD kept.

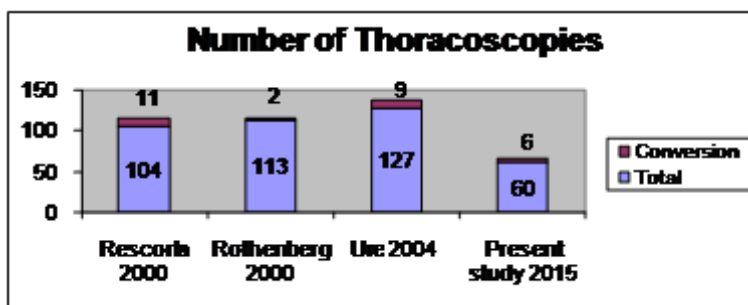
**4.8 Esophageal Atresia with TEF:**

**Number of patients: 2** This study has retrospectively analysed the records of one patient who was managed by thoracoscopic converted to open fistula ligation with end to end esophageal anastomosis.

**4.8.1 Procedure:** GA, endotracheal tube, controlled ventilation, conventional, in left lateral decubitus position, three ports used. 4 mm camera port and two 5 mm working ports. Pneumothorax created with 6 mm CO<sub>2</sub>. Esophageal atresia with distal fistula was made out. Azygous vein identified and mobilized. Upper pouch identified and mobilized. Distal TEF identified and mobilized. Due to lack of space and haemodynamic instability, converted to open. Open procedure done by conventional method. ICD kept.

**C. 4.9 Comparative Analysis**

The various results and observations made from this study were compared with similar studies and the outcome is discussed here. The feasibility and safety of VATS in children has been shown in several series.



Conversion rate according to this series is 7 to 11%

(i) Conversion rate in the present study is 10%

(ii) Empyema Thoracis ( Management algorithm)

According to **one study from Journal of Indian Association of Paediatric Surgery (July – Sep 2005)** The management consensus is according to the duration of illness and Stage of Diseases<sup>[3,4]</sup>

- Stage I - ICD Drainage
- Stage II - VATS Decortication
- Stage III- Open Decortication

The present study has similar management protocol except that in the later part of the study there is a trend towards primary VATS decortication. Duration of Illness & Management Another study from mumbai which done between June 2000-Dec 2002<sup>14</sup>, had managed 14 patients of pyothorax.

Duration	Thoracoscopic decortication	VATS + Open Decortication
< 1 week 10 cases	8 (80%)	2 (20%)
> 1 week 4	1 (25%)	3 (75%)

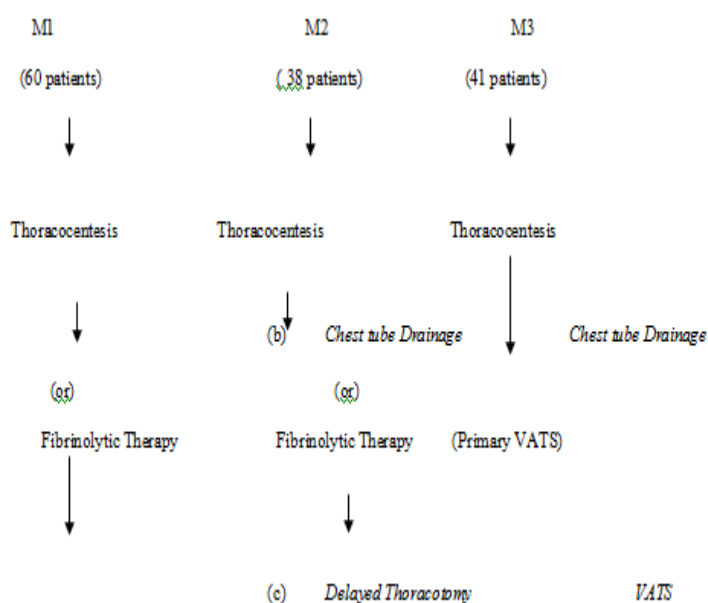
Present Study

Duration	Thoracoscopic decortication	VATS + Open Decortication
< 1 week 11 cases	18 (82%)	4 (18%)
> 1 week 9 cases	6 (33%)	12 (67%)

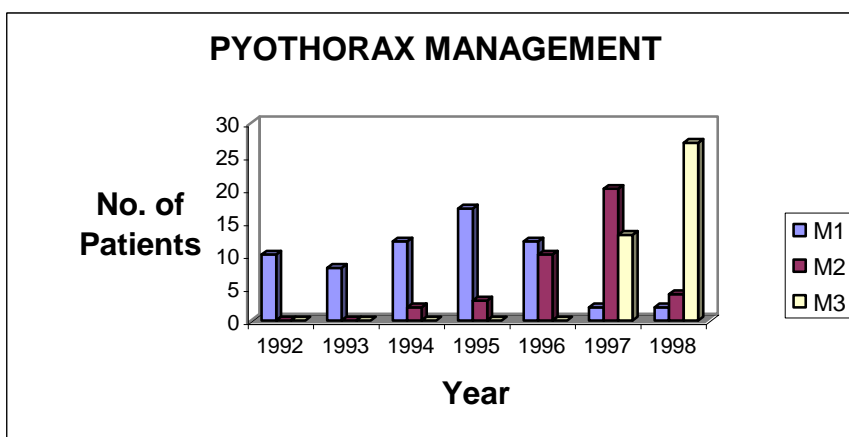
When we compare both the studies the result are similar. If the patients seeks medical help earlier within 1 week, the condition is managed with **thoracoscopic** Decortication. If the duration is more than 1 week, the management depends upon the stage of the disease and most of the patients will require open thoracotomy which increases the morbidity of the patient. **VATS has been used in children for debridement of the pleural space failing conventional management**<sup>15</sup>

A retrospective study done at DALLS, TEXAS between Jan 1992 to July 1998, Which showed the following results.

They divided the patient into 3 groups according to the management algorithm.



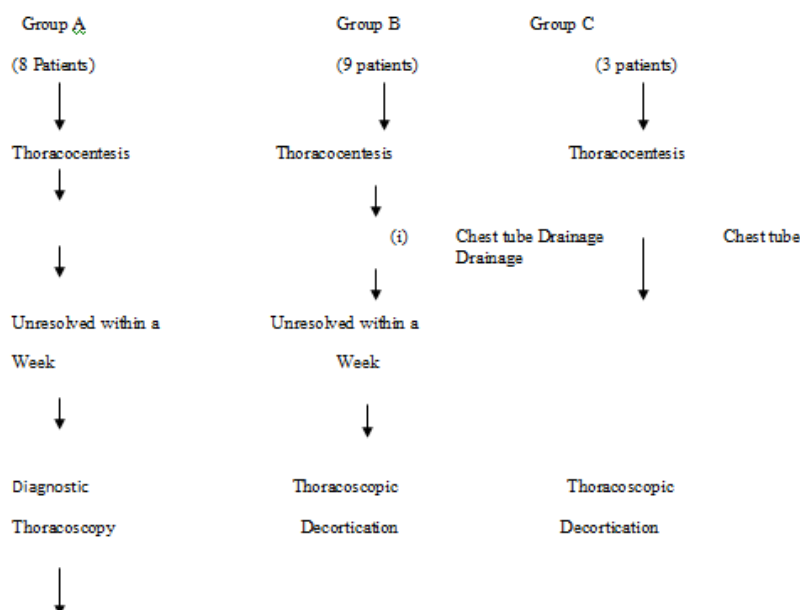
From their study they have analysed that the median length of stay in Hospital was significantly lower. The duration of ICD tube drainage is also significantly reduced in patients who have been managed with primary VATS.



This figure shows that the trend in the management of Empyema Thoracis shifting towards Primary VATS.

The present study is also has similar trend in the management of Empyema Thoracis.

Initially the patients referred to the study center with chest tube placed already. The management sequence is as follows:



If we look at the later part of the study the trend is toward primary VATS as the patients are referred earlier without chest tubes.

	2) A (16 Patients) Average (days)	B (18 Patients)	C (6Patients)	P value
Duration of Chest tube (days)	5	3.7	2.3	-
Length of stay (days)	8.6	5	4	-

When we compare the study group with above study the number of days with chest tube, Early ambulation is similar to that of above group. Primary thoracoscopy has a better outcome when compared to other procedures. Since the study group is very small 'P' value is statistically insignificant.

**Results of VATS in the Treatment of Paediatric empyema.**

Reference	Patients (N)	Preoperative Chest tube (Days)	Postoperative Chest tube (days)	Postoperative LOS (Days)	Total LOS (Days)	Recurrence, Failure, or Death (N)
Kern & Rodgers (1993)	9	6.9± 1.8	8.4 ± 4	13.4 ± 2.9	NA	1
Stovroff et.al. (1995)	12	4 to 6	4	6 to 8	NA	0
Silen & Weber (1995)	3	4 ±1	7 ± 1	8 ± 1	NA	0
Davidoff et.al. (1996)	9	NA	8.5	NA	NA	2
Grewal et. Al. (1998)	25	2 ± 1.6	3.2 ± 2.2	4.9± 2.7	7.3 ± 4	0
Present study (2015)	24	4 to 6	3.7	6 to 8	NA	1

### Pyopericardium

A prospective study conducted at **Central Hospital for children at Vietnam**. July 2002 – June 2004. which showed the length of hospital stay is reduced when pyopericardium is managed by thoracoscopic approach, without much complications.

(i) Management of Pyopericardium Table :

Length of Hospital stay	1-4 days	4-10 days	>10 days
No. of Patients	15	7	2
Present Study	-	6	-

### CDH – Thoracoscopic Approach

A **retrospective** study conducted at Ann Arbor, Michigan. Revealed the following data. <sup>[5,6]</sup>

### Bochdalek Hernias

This study reveals that CDH repair in non new borns is a reasonable option. Thoracoscopy is a better approach for repairing the hernia when compared to laparoscopy. But new borns CDH **repair** should be approach cautiously because of the chances of recurrence and attended complications. But in the present study there are no recurrences and complications. Patient had a very quick recovery.

A study from division of paediatric surgery of St. Justin Hospital Montreal, Quebec, Canada<sup>[7]</sup>, which revealed that the **Thoracoscopic** approach of excision of Isolated duplication cyst has reduced number of chest tube days and hospital stay when compared to thoracotomy.

### Excision Of Isolated FD Cysts

	Thoracotomy (n = 16)	Thoracoscopy	P	Present Study
Chest tube duration (d)	3.3 ± 0.4	1.6 ± 0.5	.01	4
Postoperative length of stay (d)	6.6 ± 1.0	2.6 ± 0.5	.002	6

But in the present study the number of chest tube days has not reduced significantly but the attended morbidity and analgesic requirement is reduced significantly. In most of the reported series the complications in Thoracoscopy are very minimal and are mostly related to Anaesthesia. In our series most of the patient undergone dual lung ventilation with conventional anaesthesia without much complications.

### Post operative complications:

Prolonged air leak – 1

Residual disease – 1

Even though there are two mortality in this series which are unrelated to thoracoscopic procedures

## IV. Conclusion

Thoracoscopy is definitely superior to thoracotomy in the management of Empyema thoracis in relation to

a. Pain relief

b. Morbidity

c. Early recovery

**d. Requirement of blood transfusion**

Primary VATS has a role in the management of empyema thoracis. Thoracoscopy can safely be done in all age groups and even in very sick children. This study reveals that this is an excellent procedure for mediastinal biopsy with a very high yield. This study reveals that thoracoscopy reduced the morbidity and gives better cosmetic results in case of pyopericardium. This study also reveals that it definitely reduces the morbidity and hospital stay in cases of thoracoscopic CDH repair. Cystic lesion of the lung can be excised safely and effectively by thoracoscopy. This study reveals that procedure like thoracoscopic esophageal atresia repair needs more operative time and expertise with specialized instruments. This study also reveals that thoracoscopic procedures can be done with conventional dual lung ventilation with pneumothorax. One lung ventilation or double lumen tubes are not mandatory. This study reveals that complications encountered in thoracoscopy are usually minor.

**Bibliography**

- [1]. Klimkovich, IG, Geldt, VG, Okulor, AB et al. Thoracoscopy in children. *Khirurgiya (mosk)* 47 : 19-24 1972
- [2]. Klimkovich, IG, Geldt, VG, Okulor, AB et al. Thoracoscopy in children. *Khirurgiya (mosk)* 47 : 19-24 1972
- [3]. Antony VB, Mohamed KA. Patho physiology of pleural space infections. *Semin. Respiratory infection* 1999, 14:9-7
- [4]. Klena TW, Cameron BH, Langer JC et al; timing of video –assisted Thoracoscopic debridement for paediatric empyema. *J. Am. coll. suag* 187:404-408, 1998
- [5]. Clark RH, Hardia Jr WD, Hirschl RB et al, currant surgical Management of CDH. A report from CDH study group *J. Paed. Surgery* 1998:33, 1004-9.
- [6]. Area MJ, Bamhart DC, Lelli JL et al; Thoracoscopic Treatment for delayed presentation of CDH in the infant results and lessons learned
- [7]. *J. Paediatric surgery* 2003; 38 : 1563 – 8, MERRYe, Spurbeck W, LobeTE : Resection of foregut derived duplications by minimal – access surgery. *Paed. Surgery int.* 1999:15:224-6