

Open Versus Laparoscopic Pyeloplasty - A Comparative Study

Venkatesa Mohan N¹, Rengarajan R², Raghul M³, Vijaya Raj S⁴

^{1,2,3,4}(Coimbatore Medical College Hospital, India)

Abstract: Dismembered Anderson-Hynes pyeloplasty is the Gold standard surgical treatment for uretero-pelvic junction obstruction. Revision of the renal pelvis treats the obstruction by excising the stenotic adynamic area of the uretero-pelvic junction and creating a more capacious conduit using the tissue of the remaining ureter and renal pelvis. This study focuses on the various indications, techniques, advantages, disadvantages and postoperative outcome of open pyeloplasty and laparoscopic pyeloplasty. A total of 110 children with PUJ obstruction were taken up for study of which 68 were males and 42 females. They were evaluated using renal parameters, ultrasound, Voiding cystourethrogram and DTPA. Patients were randomly taken up for open or laparoscopic pyeloplasty. They were evaluated pre operatively and post operatively regarding renal function, post op pain and hospital stay. Male to female ratio 1.6:1. Most of the patients presented in the age group of 3 to 6 years of age (50%). Majority had left sided lesion with a total of 62 (56.3%), right side 39 (35.5%) and bilateral 9 (8.2%). The most common type of presentation was mass abdomen 47 (42.8%), UTI 31 (28.2%), pain 8 (7.3%), antenatally 24 (21.7%). Among the 110 patients the renogram showed improved differential renal function in 96 patients of which 52 patients belonged to the Laparoscopic group and 44 patients belonged to the open group. Laparoscopic pyeloplasty is a technically sound operation which uses well established principles. The advantages of open pyeloplasty are lesser operating times. The only disadvantage of Laparoscopic pyeloplasty is longer operative time and requires significant skill of intracorporeal knotting. In our series, none of the cases had deterioration in function in **laparoscopic** group with no redo cases. This procedure has a minimal level of morbidity, shorter hospital stay, better cosmetics compared to open approach and has emerged as the standard of care for all irrespective of age.

Keywords: intracorporeal knotting, Laparoscopic pyeloplasty, Voiding cystourethrogram

I. Introduction

Ureteropelvic Junction (UPJ) obstruction is defined as an obstruction of the flow of urine from the renal pelvis to the proximal ureter. The resultant back pressure within the renal pelvis may lead to progressive renal damage and deterioration. UPJ obstruction presents most frequently in childhood, but adults and elderly individuals also can present with a primary obstructive lesion. In children, etiologies for UPJ obstruction are Adynamic segment, ureteral valves, crossing vessel and adhesive bands. Pyeloplasty is the surgical reconstruction of **uretero-pelvic** junction to drain and decompress the kidney. Most commonly it is performed to treat **uretero-pelvic junction** obstruction if residual renal function is adequate.

Dismembered Anderson-Hynes pyeloplasty is the Gold standard surgical treatment for uretero-pelvic junction obstruction. This revision of the renal pelvis treats the obstruction by excising the **stenotic adynamic** area of the uretero-pelvic junction and creating a more capacious conduit using the tissue of the remaining ureter and renal pelvis. This study focuses on the various indications, techniques, advantages, disadvantages and postoperative outcome of open pyeloplasty and **laparoscopic pyeloplasty**.

II. Objectives

- To identify the indications of Pyeloplasty.
- To study the advantages and disadvantages of open and laparoscopic pyeloplasty.
- To evaluate the postoperative outcome of opens versus Laparoscopic pyeloplasty.

III. Methodology

Children diagnosed to have pelvi-ureteric junction obstruction in the department of Pediatric Surgery, Coimbatore Medical College & Hospital, Coimbatore during the period of July-2005-July 2015 were taken up for this study. They were evaluated using ultrasound, micturating cystourethrogram and DTPA. This is a retrospective and prospective study. A total of 110 children with PUJ obstruction were taken up for study of which 68 were males and 42 females. The signs and symptoms of the children were recorded. They were evaluated using renal parameters, ultrasound, Voiding cystourethrogram and DTPA. Patients were randomly taken up for open or laparoscopic pyeloplasty. They were evaluated pre operatively and post operatively regarding renal function, post op pain and hospital stay.

3.1 Inclusion criteria:

All cases with PUJ obstruction.

3.2 Exclusion criteria:

Cases with associated Reflux.
Recurrent cases

3.3 History

Detailed history is taken with reference to age, sex, abdominal pain, and fever and urinary tract infections. Past and family history is taken.

3.4 Procedure:

3.4.1 Open pyeloplasty:

An open pyeloplasty can be performed through a variety of incisions but we performed through and extraperitoneal flank incision. This procedure typically involves the surgical excision of the narrowed segment of the UPJ and performance of a spatulated re-anastomosis of the renal pelvis to the ureter. If significant dilation of the renal pelvis occurs, it is often reduced in size by trimming off redundant tissue, and then it is tailored in such a fashion that it funnels down towards the anastomosis. A double J stent is placed across the anastomosis. And a flank corrugated rubber drain is placed. It is removed post operatively after 48 hours. If an accessory or aberrant vessel exists near the UPJ the anastomosis is positioned anterior to the vessel. Open pyeloplasty remains the criterion standard for the treatment of UPJ obstruction.

3.4.2 Laparoscopic pyeloplasty:

The patient is positioned on the ipsilateral kidney position. A 10mm umbilical trocar for camera is used and two working ports in the midclavicular line are used. Kidney can be identified posterior and lateral to the colon. The posterior peritoneum overlying the kidney is divided from the upper pole to a distance approximately 3cm below the lower pole. Care must be taken so as to not divide the lateral attachments of Gerota's fashion allowing the kidney to "flop" medially. The reno-colic ligaments are divided allowing the colon to passively move medially and provide clear exposure to the UPJ. The ureter is identified by following the psoas muscle to a point just medial to the lower pole of the kidney. The ureter can be distinguished from the gonadal vessels by peristalsis.

An Anderson Hynes repair can be used with any type UPJ obstruction and is the technique of choice. To facilitate this repair the pelvis is dissected so as to allow for optimal visualization and enough mobility to allow for a tension free anastomosis with the ureter. The scissors are used to divide the ureter at the UPJ. With a large redundant pelvis, a reduction needs to be performed prior to final repair. The ureter is then spatulated on its lateral aspect (facing the medial aspect of the kidney). A free hand intra-corporeal suturing is performed. A double J stent is placed.

IV. Results

A total of 110 cases were diagnosed with ureteropelvic junction obstruction, out of which 8 cases were bilateral UPJ obstruction (7.27%)

4.1 Age at Surgery

Of the 110 cases in the study most of the patients presented in the age group of 3 to 6 years of age which was 55 (50%) in number and those less than 6 months of age were 8 (7.27%)

Table 1: Age distribution in months (Numbers)

Age in months	Number of Patients
< 6 months	8
7-12 months	12
13-36 months	14
37-72 months	55
73-120 months	16
121-144 months	5

4.2 Distribution according to sex:

Of the 110 patients we had 68 (61.8%) male children and 42 (38.2%) female children, indicating a 1.6:1 ratio.

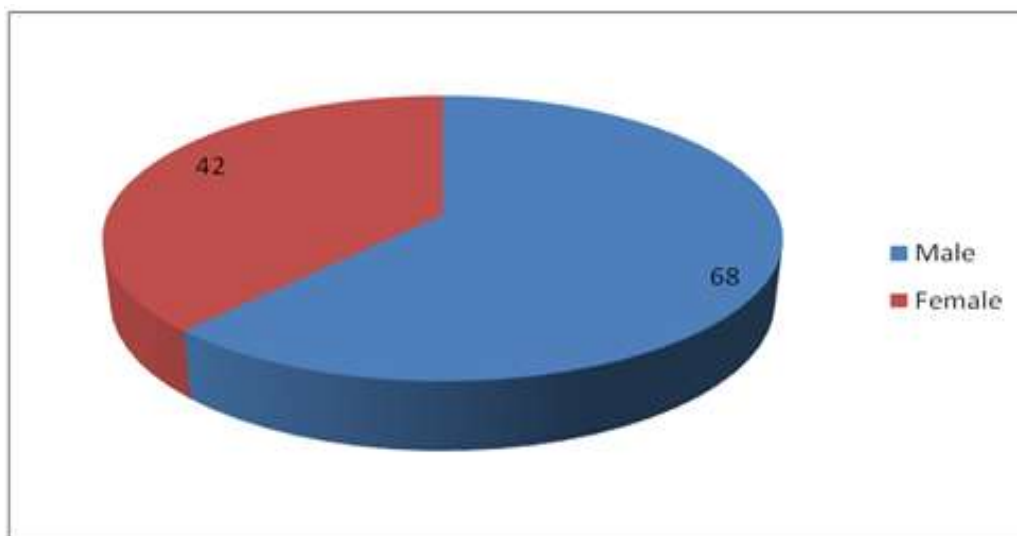


Table 2: Distribution according to Sex:

MALE	68
FEMALE	42

4.3 Distribution according to the side of the lesion:

Of the 110 patients majority had left sided lesion with a total of 62 (56.3%), right side 39 (35.5%) and bilateral 9 (8.2%).

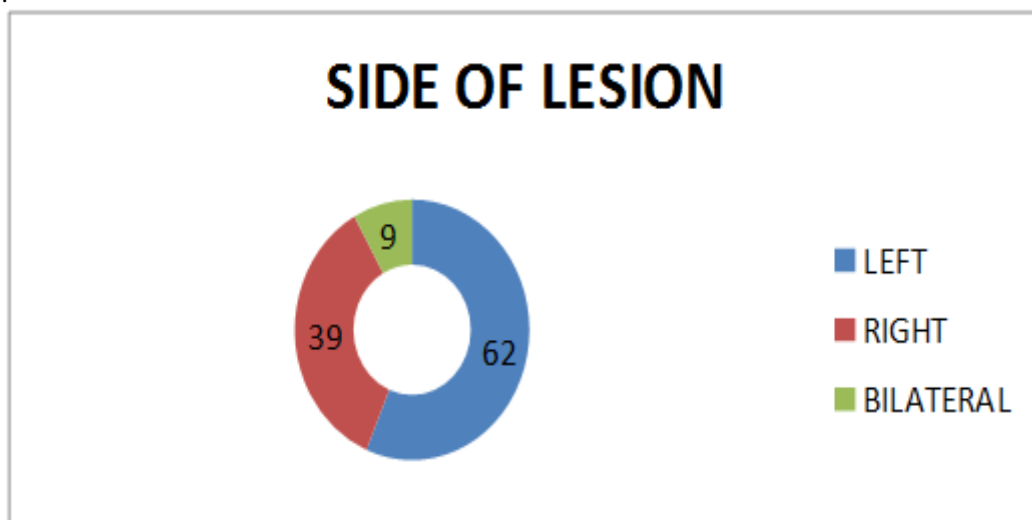


Table 3: Distribution according to the side of the lesion:

LEFT	62
RIGHT	39
BILATERAL	9

4.4 Distribution according to symptoms:

Of the 110 patients 24 were detected antenatally by ultrasound and confirmed postnatally. The most common type of presentation was mass abdomen 47 (42.8%), UTI 31 (28.2%), pain 8 (7.3%), antenatally 24 (21.7%).

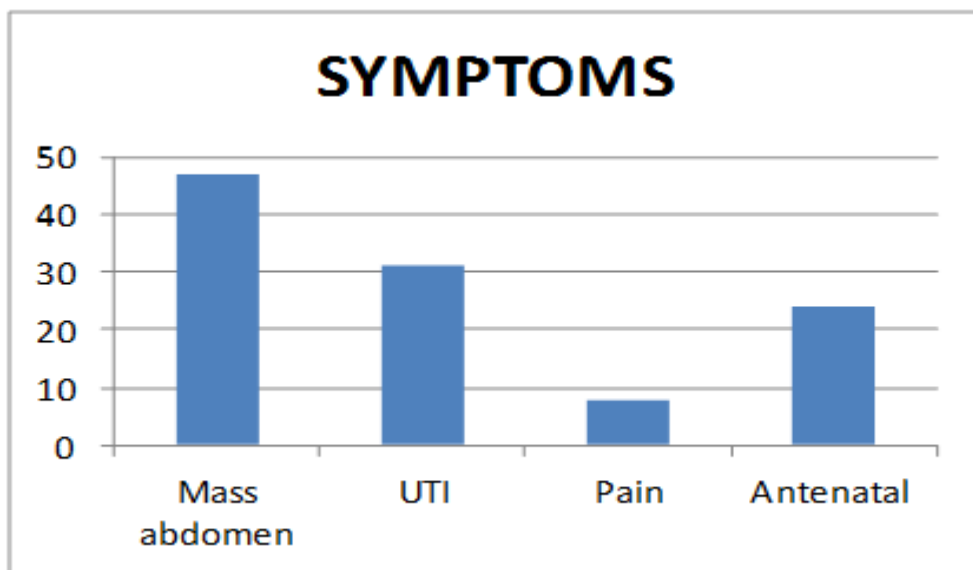


Table 4: Distribution according to symptoms:

Mass abdomen	47
UTI	31
Pain	8
Antenatal	24

4.5 Comparison of Lap Vs Open Pyeloplasties:

A total of 55 Laparoscopic pyeloplasties and 55 open pyeloplasties were performed. All patients in the laparoscopic group had unilateral UPJ obstruction.

4.6 Distribution according to total operative time taken:

Mean Total operative time with stent placement in LP group was 140.2 minutes compared to 122 minutes in open group. Total operative time did improve with experience for LP patients.

4.7Improvement status of the kidney by Renogram-follow up:

Of the 110 patients the renogram showed and improved differential renal function in 96 patients of which 52 patients belonged to the Laparoscopic group and 44 patients belonged to the open group. The renogram remained static in 9 patients of which 6 were in open ground and 3 in laparoscopic group. The remaining 3 had mild decrease in differential function and 2 worsened badly. All these five were from open group The two underwent redo pyeloplasty..

V. Discussion

Among the 110 patients there were 55 patients who were detected antenatally which accounts for 50% cases, where as in literature there were nearly 50% of patients detected antenatally^[1]. Of the 55 patients in laparoscopic group 12 children underwent surgery before 6 months of age and the remaining by 1 year of age.

According to our series left sided lesions were the most common 56.3% than right side which correlates with the literature which gives 66% comparing to the other side^[2]. Males are commonly affected than females with a ratio of 1.6:1 which correlates with the literature. According to the symptoms most children presented with mass abdomen which accounts to 42.8% and other symptoms such as pain and UTI occur less frequently. Several reports have advocated early intervention to prevent renal damage^[3]. Some studies have suggested that affected kidneys with good differential renal function (DRF) at the time of diagnosis are less likely to manifest deterioration of renal function after surgery. In contrast other series concluded that renal function did not improve after pyeloplasty regardless of the pre-op renal functional status. Of the 110 patients the renogram showed an improved differential renal function in 96 patients of which 52 patients belonged to the Laparoscopic group and 44 patients belonged to the open group. The renogram remained static in 9 patients of which 6 were in open group and 3 in laparoscopic group. The remaining 3 had mild decrease in differential function and 2 worsened badly. All these five were from open group. The two underwent redo pyeloplasty. Compared to open pyeloplasty, the postoperative analgesic requirement was significantly less in LP group compared to open group mean. The duration of analgesic requirement was also significantly less in LP group. The postoperative hospital stay in LP was mean 3.14 Days (2-7 days) significantly less than open group mean

8.29 days (7-11 days). The mean follow-up ;in open cases was 33.5 months and in Laparoscopic cases was 34.5 months. There was only conversion in laparoscopic group to open surgery. Two patients in the open group needed redo-pyeloplasty. There was minimal or no scarring of the wound site in patients in the laparoscopic group compared to open. The success rate of laparoscopic pyeloplasty has been reported to be consistently high, at 87-98%^[4] In the present series, we had a success rate of 94%. We considered conversion to open as a failure.

The only disadvantage seems to be longer operative time in published series.^[5,6] However, Zhang et al,¹⁸ reported less operative time in Laparoscopic group (retroperitoneal) than open group. As laparoscopic surgery becomes more entrenched in resident training, the more complex skills such as intracorporeal suturing become less daunting. Moreover, long operative time may be reduced by skill of intracorporeal knotting and development of new robotic equipment,^[6] the performance enhancing feature of Da Vinci robot seems to decrease the difficulty of intra corporeal suturing. In general the reported overall complications rate of laparoscopic pyeloplasty ranges from 4% - 12.7%.^[4] In the present study there was only one major complication and only one conversion to open surgery.

VI. Conclusion

Laparoscopic pyeloplasty is a technically sound operation which uses well established principles.

- The advantages of **open pyeloplasty** are lesser operating times.
- The only disadvantage of Laparoscopic pyeloplasty is longer operative time and requires significant skill of intracorporeal knotting.
- In our series, none of the cases had deterioration in function in **laparoscopic** group
- In our series there are no redo cases with laparoscopic pyeloplasty.
- This procedure has a minimal level of morbidity, short hospital stay, better cosmetics compared to open approach.
- Laparoscopic pyeloplasty has emerged as the **standard** of care for all pyeloplasties. irrespective of age group.

References

- [1]. Comparison of open and endourologic approaches to the obstructed ureteropelvic junction. Urology. 1995 Dec;46(6):791-5. Brooks JD¹, Kavoussi LR, Preminger GM, Schuessler WW, Moore RG
- [2]. Laparoscopic pyeloplasty: the first 100 cases. J Urol. 2002 Mar;167(3):1253-6. Jarrett TW¹, Chan DY, Charambura TC, Fugita O, Kavoussi LR
- [3]. Retrospective comparison of retroperitoneal laparoscopic versus open dismembered pyeloplasty for ureteropelvic junction obstruction. J Urol. 2006 Sep;176(3):1077-80. Zhang X¹, Li HZ, Ma X, Zheng T, Lang B, Zhang J, Fu B, Xu K, Guo XL
- [4]. Retroperitoneal laparoscopic versus open pyeloplasty in children. J Urol. 2005 May;173(5):1710-3; discussion 1713. Bonnard A¹, Fouquet V, Carricaburu E, Aigrain Y, El-Ghoneimi A.
- [5]. Comparison of open versus laparoscopic pyeloplasty techniques in treatment of uretero-pelvic junction obstruction. Eur Urol. 2003 Sep;44(3):340-5. Klingler HC¹, Remzi M, Janetschek G, Kratzik C, Marberger MJ.
- [6]. Retroperitoneal laparoscopic versus open pyeloplasty with a minimal incision: comparison of two surgical approaches. Urology. 2001 Mar;57(3):443-7. Soulié M¹, Thoulouzan M, Seguin P, Mouly P, Vazzoler N, Pontonnier F, Plante P.