

Surgical Management of a Periapical Cyst with an Alloplastic Bone Graft: A Case Report

Siddharth Shah¹, Kishan K. V², Ritika De³, Nidhi Solanki⁴, Parth Patel⁵

^{1,2,3,4,5}(Department of Conservative Dentistry and Endodontics, K.M Shah Dental College and Hospital/Sumandeep Vidyapeeth University, India)

Abstract : It has been observed that the root canal treatment for the preservation of tooth having periapical pathology has shown over 90% of success whereas in the case where the canal is calcified, perforated, ledge is formed, and cases where symptoms still exist after treatment, endodontic treatment may not be the solution in attaining a successful treatment. Thus Apisectomy would generally be done to prevent the loss of tooth having a periapical lesion where treatment prognosis is poorly evaluated by endodontic treatment. In following case endodontic treatment was applied due to a consistent radiolucent lesion in periapical area but the symptoms did not show improvement and therefore apisectomy was performed and an alloplastic bone graft was used to aid in a rapid bone formation.

Keywords: Apisectomy, Bone Graft, Mineral trioxide aggregate.

I. Introduction

Nonsurgical endodontic treatment is a highly predictable treatment option in most cases, but surgery may be indicated for teeth with persistent periapical pathosis unresponsive to nonsurgical approaches. Surgical root canal therapy, including root-end resection, has been practiced since at least the mid-1800s¹. Over the past 2 decades, periapical surgery has continued to evolve into a precise, biologically based adjunct to nonsurgical root canal therapy. The parallel development of new instruments and materials, along with a better understanding of the biology of wound healing, has made surgical treatment a viable alternative to extraction and tooth replacement. Although nonsurgical retreatment generally is believed to be the preferred first approach in the management of persistent apical periodontitis². Periapical surgery is indicated when nonsurgical retreatment is impractical or unlikely to improve on the previous result. Even when surgical treatment is the likely definitive approach, nonsurgical therapy before the procedure may be recommended to help reduce the number of microorganisms in the root canal system and ensure a more favorable long-term prognosis³. The present case report is of an individual with a large periapical cyst.

II. Case Report

A 27-year-old male patient reported to the Department of Conservative Dentistry & Endodontics, KM Shah Dental College and hospital with the chief complaint of pain and pus discharge in the lower front teeth region of jaw. He gave a history of trauma 15 years back for which no treatment was sought. Post trauma, he had pain in relation to mandibular central incisors which subsided after 1 week on its own. He gave a history of swelling along with pus discharge from gums since last 2 years. On clinical examination, 31 & 41 was found to be discolored and a fibrous sinus tract opening was seen with respect to 41.

2.1 Investigation:

Electric pulp testing gave a negative response in relation to 31 and 41. An Intra Oral Periapical Radiograph (IOPA) in relation to 31 & 41 revealed large well defined periapical radiolucency involving central incisors.

2.2 Treatment

An endodontic therapy was planned with respect to 31 & 41. Repeated calcium hydroxide dressings were given at an interval of 5 days for 1 month. However, there was no healing seen of the sinus tract in relation to 41. Hence surgical enucleation of the cyst through a buccal approach was adopted. A full thickness envelope flap was raised extending from the distal papilla of the lateral incisor of one side to that of the opposite side. Bony window was seen in relation to 41 in the apical 1/3rd. The bony window was extended till the apical 1/3rd of 31 with a slow speed fissure cutting bur using water coolant. After which the Cyst enucleation was carried out. Apical resection was made to the amount just required for preparing the retrograde cavity. MTA (Mineral trioxide aggregate) was used as the retrograde filling material after which the cystic cavity was filled with the alloplastic bone graft. Suturing was done with triple-zero silk to reposition the flap. Antibiotics, NSAID and an oral rinse solution were prescribed, and the sutures were removed on the seventh postoperative day. A one month follow up showed complete healing of the sinus tract and significant bone formation

Figures

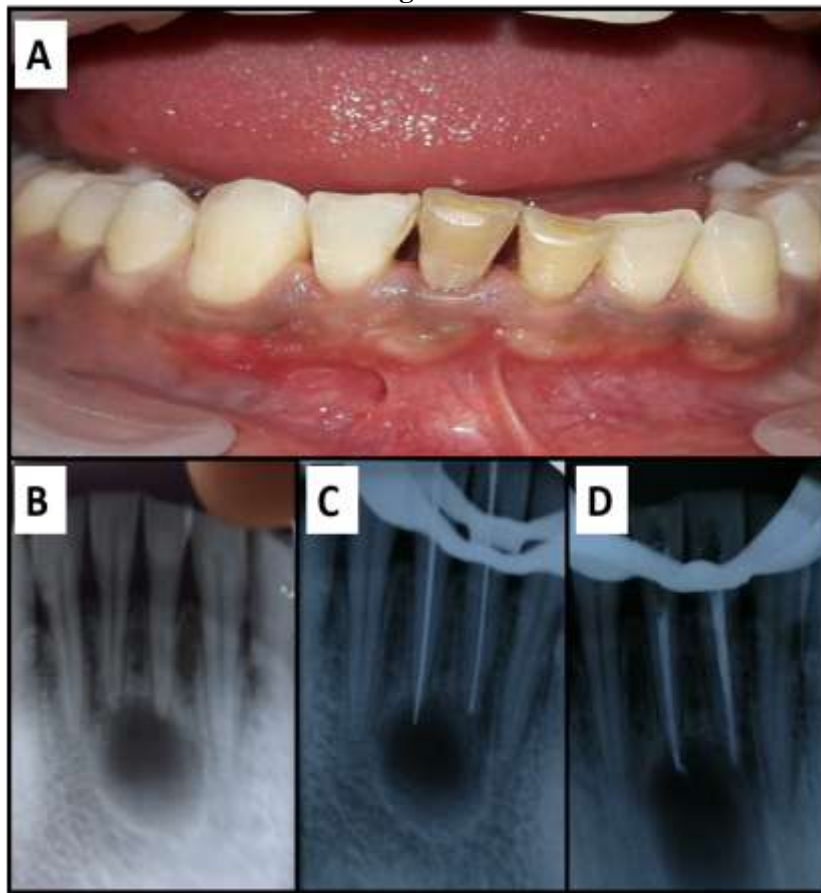


Fig 1: a) Pre-operative clinical photograph, b) Pre- operative radiograph, c) Working length determination, d)

Obturation

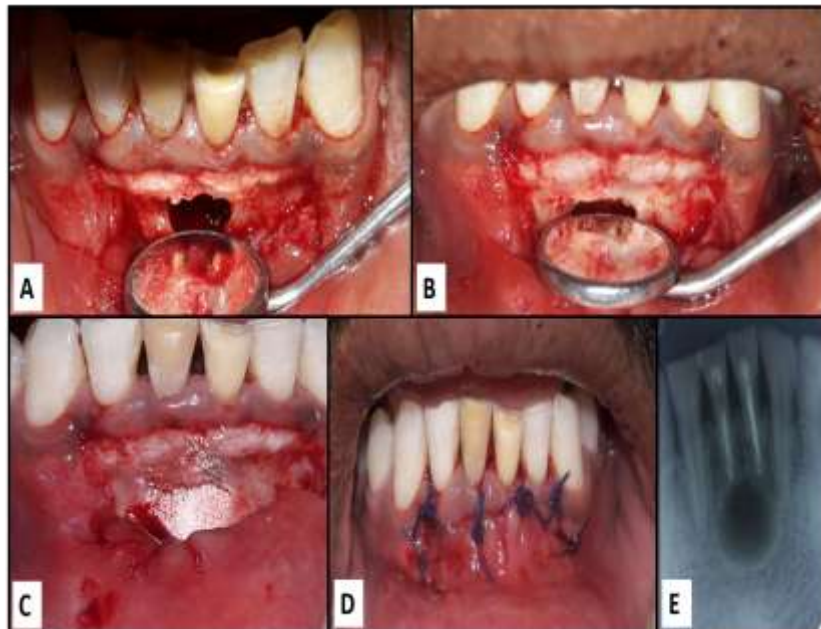

Fig 2: a) Flap reflection and bony window prepared, b) Root end preparation and resection in 31,41, c) Alloplastic bone graft placed after cyst enucleation, d) Interrupted sutures, e) Post MTA root end filling radiograph.

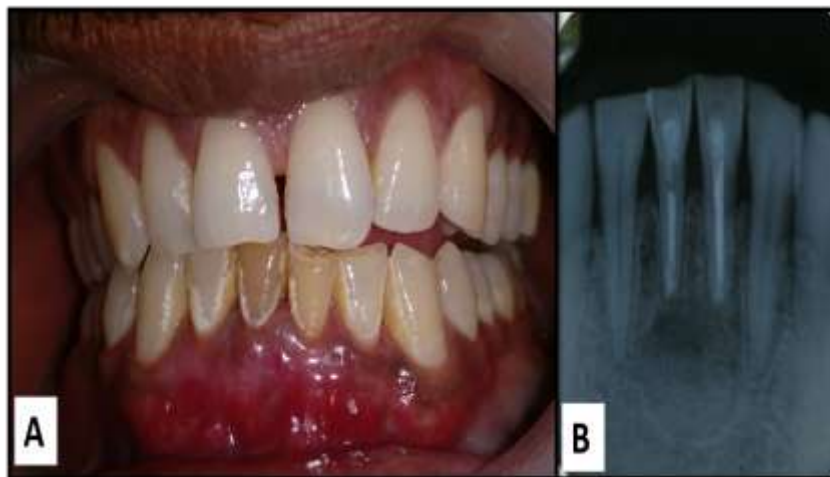


Fig 3: a) 1 month follow up photograph, **b)** 3 month follow up radiograph

III. Discussion

The periapical cyst is the most common odontogenic cyst (52.3-70.7 %) followed by the dentigerous cyst (16.6-21.3%) and odontogenic keratocyst (5.4 - 17.4 %)⁴. The choice of treatment may be determined by factors such as the extension of the lesion, relation with noble structures, evolution, origin, clinical characteristic of the lesion, systemic condition and cooperation of the patient⁵. The treatment of these cysts is still under discussion and many professionals opt for a conservative treatment by means of an endodontic technique⁶. However, in large lesions the endodontic treatment alone is not sufficient and it should be associated with decompression or marsupialisation or enucleation⁷. In the present case, endodontic treatment was carried out in multiple visits with interim calcium hydroxide dressings. The use of root canal dressings between sessions in root canal treatment of teeth with chronic periapical lesions is important for reducing levels of bacteria better than that obtained with mechanical preparation, particularly by penetration of areas that are unreachable by instruments or irrigation solutions, such as dentinal tubules and ramifications. Calcium hydroxide has also shown clinical efficiency in reducing exudate due to its hygroscopic properties. Studies have shown that at least 2 weeks are necessary for calcium hydroxide bactericidal activity⁸. Apisectomy has been recommended as a retreatment procedure after endodontic failure⁹. However, apisectomy, as the first choice of treatment for non-vital incisors with large periapical defects has seldom been documented. In our patient, mineral trioxide aggregate (MTA) was used to obtain the apical seal. It has been known for its outstanding tissue compatibility, and has been found to promote periapical healing and the production of cementum and bone¹⁰.

Torabinejad et al., found a success rate of 77.8% for periapical surgery at 2-4 y and a rate of 71.8% at 4-6 y¹¹. Zuolo et al., recorded success in 91.1% of cases and failure in 8.8%, over a follow-up period between 1-4 y¹². Among the materials employed for the filling of the surgical cavity, according to Reddy et al. ¹³, alloplastic bone graft (G- Bone) is the standard material as it is composed of natural form of Hydroxyapatite in its ceramic, crystalline form, derived from bovine bone available as blocks it provides immunocompatible bone cells, essential for phase I osteogenesis, accounting for the proliferation of bone cells, especially from the osteoid. The rationale behind the filling of the surgical cavity with an alloplastic bone graft: is to be biocompatible, osteoconductive; to stimulate bone neoformation; to be hemostatic; to act as a barrier in guided tissue regeneration against the formation of both conjunctive and epithelial tissue; to be of easy handling; and to decrease the post-surgical healing time.

IV. Conclusion

Based on the literature and the clinical case presented, it could be concluded that endodontic surgery when well indicated and performed in conjunction with root canal treatment using bone formation enhancing materials has a very favorable prognosis. The traditional endodontic treatment eliminates the infection inside the canal, whereas apisectomy with placement of alloplastic bone graft eliminates the infection in the periapical area, allowing rapid neo bone formation.

References

- [1]. Gutmann JL: Perspectives on root-end resection Hist Dent 47:135,1999.
- [2]. Briggs PF, Scott BJ: Evidence-based dentistry: endodontic failure—how should it be managed? Br Dent J 183:159,1997.
- [3]. Hepworth MJ, Friedman S: Treatment outcome of surgical and non-surgical management of endodontic failures. J Can Dent Assoc (Tor) 63:364, 1997.

- [4]. Ali M, Baughman RA: Maxillary odontogenic keratocyst: A common and serious clinical misdiagnosis. *JADA*, 2003;134(7):877-883.
- [5]. Ribeiro PD (Jr.) Gonçalves ES, Neto ES, Pacenko MR: Surgical approaches of extensive Periapical cyst. Considerations about Surgical technique. *Salusvita, Bauru*, 2004;23(2):317-328.
- [6]. Rees JS: Conservative management of a large maxillary cyst. *Int Endo J*, 1997;30(1):64-67.
- [7]. Çaliskan MK: Prognosis of large cyst-like periapical lesions following nonsurgical root canal treatment: a clinical review. *Int Endod J*, 2004;37(6):408-416.
- [8]. Leonardo MR, Silveira FF, Silva LA, Tanomaru Filho M, Utrilla LS: Calcium Hydroxide Root Canal Dressing. Histopathological Evaluation of Periapical Repair at Different Time Periods. *Braz Dent J*, 2002; 13(1):17-22.
- [9]. Furusawa M, Asai Y. SEM observations of resected root canal ends following apicoectomy. *Bull Tokyo Dent Coll*. 2002; 43:7-12.
- [10]. Torabinejad M, Parirokh M. Mineral trioxide aggregate: a comprehensive literature review--part II: leakage and biocompatibility investigations. *J Endod*. 2010; 36:190-202.
- [11]. Torabinejad M, Corr R, Handysides R, Shabahang S. Outcomes of nonsurgical retreatment and endodontic surgery: a systematic review. *J Endod*. 2009; 35:93037.
- [12]. Zuolo M, Ferreira M, Gutmann J. Prognosis in periradicular surgery: a clinical prospective study. *Int Endod J*. 2000; 33:91-8.
- [13]. Pinto JGS, Ciprandi MTO, Aguiar RC, Lima PVP, Hernandez PAG, Silva Júnior AN. Enxerto autógeno x biomateriais no tratamento de fraturas e deformidades faciais – uma revisão de conceitos atuais. *Rev Facul Odontologia UPF*. 2007;12(3):79-84.