

Jejuno-Jejunal Intussusception Secondary to Peutz-Jeghers Polyp; two Rare Case Report

Ramjee Prasad¹, Dinesh Kumar Barolia¹, Soumyodhrity Ghosh¹, Ayush Kumar¹, Neha Sharma²

¹Senior Resident, Department Of Pediatric Surgery, SMS, Jaipur, Rajasthan, India

²Junior Resident, Department of Anaesthesia, SMS, Jaipur, Rajasthan, India

I. Introduction

History: A 7-year-old boy with presented to the emergency department with abdominal pain that had persisted for 20 hours. The pain was located in the whole abdominal region and was described as sharp and intermittent. The patient also reported nausea and several episodes of nonbilious, nonbloody vomiting. There was known family history of Peutz-Jeghers syndrome. The patient father had died due to same complain by Peutz-Jeghers syndrome four month back. Physical examination revealed multiple pigmented lesions on the lower lip and oral mucosa. At abdominal examination, epigastric and periumbilical tenderness, diminished bowel sounds. The patient underwent an exploratory laparotomy, resection of jejuno-jejuno intussusception with high jejuno- ileo resection anastomosis was done, operative finding was multiple jejunal and sigmoidal polyp (fig3), Further plan was done for endoscopic removal after recovery of patient.

A 3-year-old boy with complain of pain abdomen from 10 hours, vomiting with bleeding per rectum, at abdominal examination epigastric tenderness with mass like feeling, per rectal was mucus with stool. The patient underwent an exploratory laparotomy, reduction of jejuna-jejunal bowel intussusception, polypectomy, bowel resection with high jejuno-ileo anastomosis with feeding jejunostomy, the intussuscepted small bowel was dilated and dusky

The initial abdominal radiograph demonstrated a nonspecific bowel gas pattern with no evidence of bowel obstruction or free air. Abdominal ultrasonography (US) was then performed and showed a 60mm long segment jejuno-jejuno intussusceptions in with multiple sub mesenteric lymph node (Fig 1). CT also showed mesenteric fat and vessels interposed between an intussusceptum and the intussusciens, findings that confirmed a diagnosis of small bowel intussusception (Fig 2). The proximal small bowel was mildly dilated to 4.5 cm. The primary gross pathologic specimen consisted of an 8-cm portion of bowel that contained a 6 × 2.5 × 2-cm hemorrhagic lead-point polyp with several smaller polyps aggrega Fig 4. Histologic analysis showed that the lead-point polyp was composed of a core of arborizing smooth muscle that supported nonneoplastic small bowel mucosa, findings consistent with those of a Peutz-Jeghers polyp with mucocutaneous pigmentation (Fig 5). Ischemic necrosis with hemorrhage was prominent over much of the surface of the polyp, a finding consistent with the leading edge of an intussusception. Aggregates of benign small bowel mucosa and pools of mucin were present within the submucosa and muscularis propria at the base of the polyp, a finding that is consistent with epithelial misplacement in a Peutz-Jeghers polyp (Fig 4, 5, 6)

II. Discussion

Peutz-Jeghers syndrome was first described by Peutz in 1921 and Jeghers in 1944 and 1949 (1). The syndrome is characterized by mucocutaneous pigmentation and hamartomas of the gastrointestinal system and is seen in both male and female patients with no racial predominance (2). It is usually diagnosed during childhood or early adulthood. Inheritance of the syndrome is autosomal dominant with incomplete penetrance, with some cases arising from spontaneous mutations (3). Mutations to the serine/threonine kinase 11 tumor suppressor gene on chromosome 19p13.3 have been shown to cause Peutz-Jeghers syndrome (4).

Mucocutaneous pigmentation is a characteristic finding of Peutz-Jeghers syndrome and is present in most, but not all, patients who have the disease. The hyperpigmented lesions contain melanotic deposits and commonly manifest in infancy and childhood. The cutaneous lesions are often seen on the lips and perioral region, as well as on the periorbital region. Involvement of the buccal mucosa is also common (5). The mucocutaneous lesions of Peutz-Jeghers syndrome are considered to be hamartomatous in origin and without potential of becoming malignant.

Gastrointestinal hamartomatous polyps are another classic finding of Peutz-Jeghers syndrome. Although these polyps are most commonly found in the small intestine, they can occur anywhere from the stomach to the rectum (6). Patients with Peutz-Jeghers syndrome often present with a history of intermittent abdominal pain due to small bowel intussusception caused by the polyps. Some intussusceptions spontaneously

reduce. Others lead to development of small bowel obstruction. Peutz-Jeghers polyps can also ulcerate, leading to acute blood loss or chronic anemia (7). Although Peutz-Jeghers polyps are most commonly found in the gastrointestinal system, they can also occur in extraintestinal sites such as the kidney, ureter, gallbladder, bronchial tree, and nasal passages (8).

Patients with Peutz-Jeghers syndrome are at increased risk of developing gastrointestinal adenocarcinomas. The frequency of gastrointestinal malignancies is estimated to be approximately 2%–3%, with the mean age at diagnosis being about 40 years of age (9). The majority of cancers are found in the stomach, duodenum, and colon. Interestingly, the small bowel is the least common site of adenocarcinoma; because Peutz-Jeghers polyps occur most frequently in the small bowel, it is possible that these polyps have a low potential of becoming malignant. However, cases of dysplastic changes in hamartomatous polyps have been reported, so there may be some potential for malignant transformation (9).

Patients with Peutz-Jeghers syndrome are also at increased risk for developing extraintestinal malignancies, the most common of which are pancreatic, breast, and reproductive organ carcinomas such as ovarian and testicular cancer. An analysis of 419 patients with Peutz-Jeghers syndrome by Hearle et al (10) found that the major risk of extraintestinal malignancy in women was for breast cancer, with the upper confidence limit of the estimated risk being 50% at 60 years of age; this risk is comparable to that associated with mutations of *BRCA1* or *BRCA2* (tumor suppressor genes that account for the majority of familial breast cancer cases).

Typical imaging features of Peutz-Jeghers syndrome consist of multiple polypoid lesions involving the stomach, small bowel, and colon. The polyps can be variable in appearance—small or large, sessile or pedunculated. The presence of multiple gastrointestinal polyps is not specific for Peutz-Jeghers syndrome, as they can be seen with other polyposis syndromes, such as familial adenomatous polyposis, juvenile polyposis, Cowden disease, and Cronkhite-Canada syndrome. Clinical features in conjunction with radiologic findings and histologic specimens allow for a correct diagnosis to be made. Although the polyps are often detected with barium studies, they can also be identified with US or CT (11). Some authors have suggested using US or magnetic resonance (MR) imaging for follow-up imaging to reduce the lifetime radiation burden, with the caveat that small polyps less than 1.5 cm in diameter could be missed and clustered polyps could be misinterpreted as a larger mass lesion (12).

Another important imaging finding in Peutz-Jeghers syndrome is intussusception. An intussusception is composed of two parts: the intussusciens, or receiving loop, and the intussusceptum, or donor loop, which includes an entering limb and a returning limb with attached mesenteric fat interposed between them.

Radiography is often performed as an initial imaging study in patients with suspected intussusception. The most common radiographic sign of an intussusception is a soft-tissue mass, usually located in the right upper quadrant. Other nonspecific findings such as a gasless abdomen or small bowel obstruction may also be seen. The target and meniscus signs are the most specific radiographic findings (13). The target sign consists of a concentric lucent rim surrounding a soft-tissue mass; the appearance is caused by mesenteric fat adjacent to the intussusceptum. The meniscus sign is a crescent of intraluminal bowel gas surrounding the apex of an intussusception.

At US, an intussusception may have a “doughnut” or “pseudokidney” appearance on images obtained transversely or longitudinally to the long axis (14). The hypoechoic outer area represents the edematous bowel wall of the intussusciens and the hyperechoic central area represents mesenteric fat that is dragged into the intussusception between the entering and returning limbs of the intussusceptum.

CT findings are similar to those seen at US. On CT images, an intussusception appears as a complex soft-tissue mass composed of a central intussusceptum and outer intussusciens. The mesenteric fat that is dragged into the intussusception appears as a low-attenuation, fatty crescentic mass that separates the intussusceptum from the intussusciens. Enhancing vessels are often seen within the mesenteric fat. The appearance of an intussusception on CT images is similar to that of a “target” mass when the x-ray beam is perpendicular to the longitudinal axis of the intussusception and to that of a “sausage” mass when the x-ray beam is parallel to the longitudinal axis (15).

Because it appears to be composed of nonneoplastic tissue normally found at the site, the Peutz-Jeghers polyp is generally considered a hamartomatous polyp but with an abnormal growth pattern. The most characteristic feature of a Peutz-Jeghers polyp is a central core of smooth muscle that extends into the polyp in an arborizing fashion and that is covered by either normal or hyperplastic mucosa native to the involved site (16). These pathologic features distinguish Peutz-Jeghers polyps from those seen in Cronkhite-Canada syndrome, juvenile polyposis, and Cowden disease, although any large polyp can include a small amount of smooth muscle due to prolapse.

Epithelial misplacement, also referred to as pseudoinvasion, is another feature seen in some Peutz-Jeghers polyps. It is characterized by benign epithelium and supporting lamina propria within the submucosa, muscularis propria, or subserosal layers of the gut adjacent to a polyp and extravasated mucin pools, which are

formed from the mucous secretions of the displaced glands. Epithelial misplacement may be caused by intussusception and is seen in less than 10% of small bowel Peutz-Jeghers polyps; it can mimic the appearance of invasive adenocarcinoma (17). However, noting the lack of epithelial dysplasia, the presence of supporting lamina propria, and the absence of a desmoplastic stromal reaction can help avoid this interpretive error.

In the past, standard therapy for Peutz-Jeghers syndrome has been laparotomy and bowel resection to remove symptomatic gastrointestinal polyps that cause persistent or recurrent intussusceptions. However, some patients require multiple surgical resections, which can lead to short gut syndrome. Because of this, it has been recommended that endoscopy be performed to remove all polyps. During each laparotomy, the small bowel should be examined by means of intraoperative enteroscopy. This more aggressive approach can help to eliminate gastrointestinal symptoms and prevent or postpone repeat abdominal surgeries (18). One study by Oncel et al (19) included 11 Peutz-Jeghers patients who were divided into two groups. One group consisted of eight patients who underwent problem-focused surgery, and the other group consisted of three patients who underwent a “clean sweep” procedure in an attempt to remove all detected polyps. The investigators found that the clean sweep technique significantly reduced the need for further operations ($P = .01$). The clean sweep group required no further surgeries in 21 patient-follow-up-years; the problem-focused surgery group required 23 further operations in 87 patient-follow-up-years.

Because of the increased risk of both gastrointestinal and extraintestinal malignancy, careful surveillance screening of Peutz-Jeghers patients is recommended. Specific testing should include monitoring hemoglobin levels, as well as regular breast, gynecologic, and testicular examinations. Pelvic, testicular, and pancreatic US screening should also be considered. Gastrointestinal tract screening can be performed with endoscopy of the upper and lower tract in combination with enteroclysis or small bowel capsule endoscopy

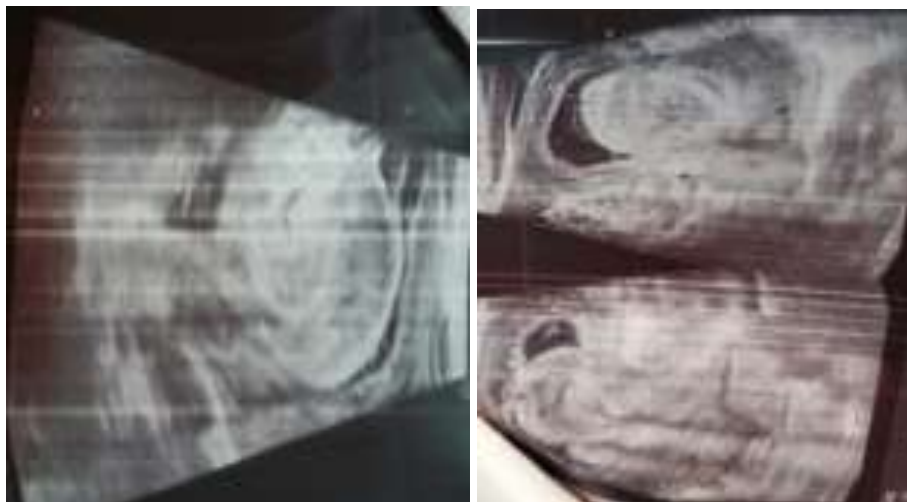


Figure 1. Abdominal US image demonstrates a large long segment jejunal intussusceptions with target sign,

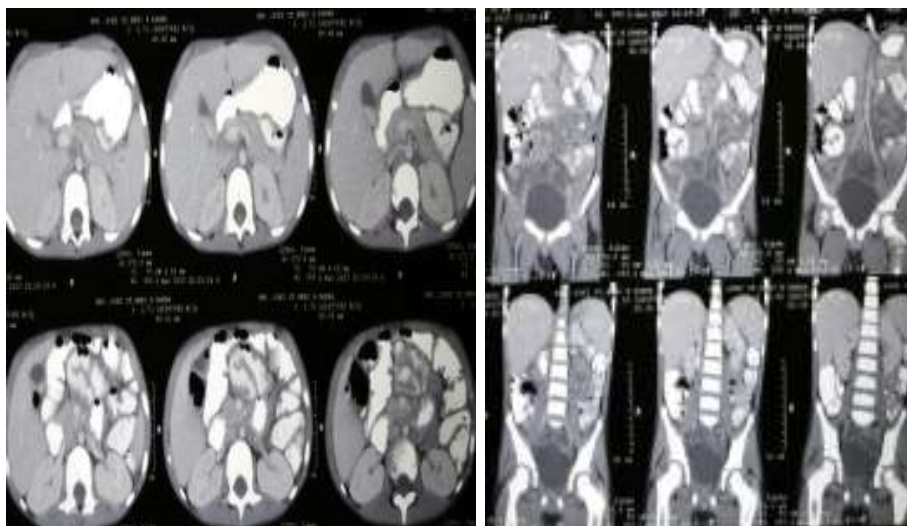


Figure 2a. (a) CECT image oriented parallel to the longitudinal plane of the intussusceptions. **Figure 2b.** CT image oriented parallel to the longitudinal plane of the intussusception demonstrates a Jejunal

intussusception mass with central low-attenuation fat, which is being dragged into the intussusciens by the intussusceptum

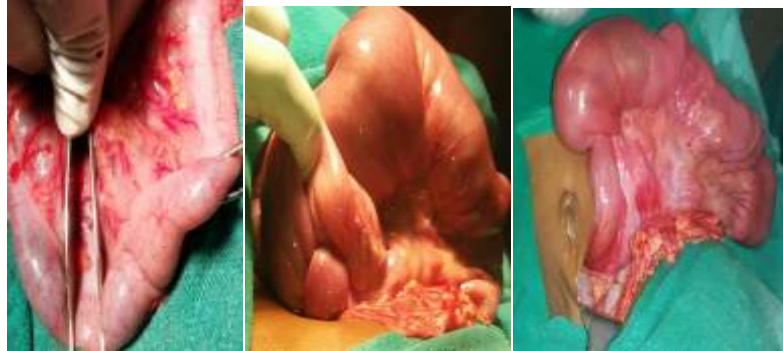

Figure 3.a Intraoperative photograph shows the multiple polyp on sigmoid region, 3b. transition zone of the intussusceptions on high jejunum-jejunal region, which was caused by a lead-point polyp. The intussusceptum is dilating and obstructing the intussusciens with jejunal multiple polyp, 3c another patient showing high jejunal intussusceptions.



Figure 4.a Photograph of the gross bowel specimen demonstrates the lead-point polyp with several smaller polyps aggregated at the base of the dominant polyp, with intussusceptions. 4b. gross bowel specimen demonstrates the lead-point polyp with intussusception. 4c multiple jejunal polyps with necrosis



Fig 5 a Photomicrograph of magnification X100 hematoxylin-eosin stain demonstrates that Peutz-Jeghers polyp characteristically contains a core of arborizing smooth muscle, upon which rests mucosa that is crevate to the site of the polyp, in this case small bowel mucosa. 5b. Photomicrograph shows that this large Peutz-Jeghers polyp includes nests of benign mucosa that are located in the submucosa and muscularis propria with hyperplastic epithelial misplacement.

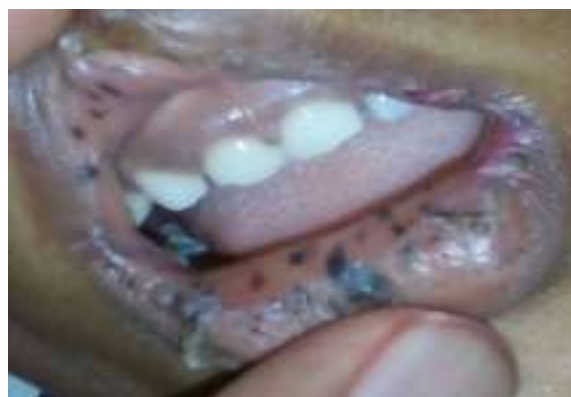

Fig 6 shows multiple mucocutaneous pigmentation on lip

References

- [1]. Rebsdorf Pederson I, Hartvigsen A, Fischer Hansen B, Toftgaard C, Konstantin-Hansen K, Bulow S. Management of Peutz-Jeghers syndrome: experience with patients from the Danish Polyposis Register. *Int J Colorectal Dis*1994; 9: 177–179. CrossRef, Medline
- [2]. Bartholomew LG, Moore CE, Dahlin DC, Waugh JM. Intestinal polyposis associated with mucocutaneous pigmentation. *Surg Gynecol Obstet*1962; 115: 1–11. Medline
- [3]. Buck JL, Harned RK, Lichtenstein JE, Sobin LH. Peutz-Jeghers syndrome. *RadioGraphics*1992; 12: 365–387. Lin
- [4]. Schreiber IR, Baker M, Amos C, McGarrity T. The hamartomatous polyposis syndromes: a clinical and molecular review. *Am J Gastroenterol*2005; 100: 476–490. CrossRef, Medline
- [5]. Utsunomiya J, Gocho H, Miyanga T, et al. Peutz-Jeghers syndrome: its natural course and management. *Johns Hopkins Med J*1975; 136: 71–82. Medline
- [6]. Spigelman AD, Phillips RKS. Peutz-Jeghers syndrome. In: Phillips RKS, Spigelman AD, Thomson JPS, eds. *Familial adenomatous polyposis and other polyposis syndromes*. London, England: Edward Arnold, 1994; 188–202.
- [7]. Kitagawa S, Townsend BL, Hebert AA. Peutz-Jeghers syndrome. *Dermatol Clin*1995; 13: 127–133. Medline
- [8]. Latchford A, Greenhalf W, Vitone LJ, et al. Peutz-Jeghers syndrome and screening for pancreatic cancer. *Br J Surg*2006; 93: 1146–1455.
- [9]. Flageole H, Raptis S, Trudel JL, Lough JO. Progression toward malignancy of hamartomas in a patient with Peutz-Jeghers syndrome: a case report and literature review. *Can J Surg*1994; 37: 231–236. Medline
- [10]. Hearle N, Schumacher V, Menko F, et al. Frequency and spectrum of cancers in the Peutz-Jeghers syndrome. *Clin Cancer Res*2006; 12(10): 3209–3215. CrossRef, Medline
- [11]. Sener RN, Kumcuoglu Z, Elmas N, Oyar O, Tugran C. Peutz-Jeghers syndrome: CT and US demonstration of small bowel polyps. *Gastrointest Radiol*1991; 16: 21–23. CrossRef, Medline
- [12]. Kurugoglu S, Aksoy H, Kantarci F, et al. Radiologic work-up in Peutz-Jeghers syndrome. *Pediatr Radiol*2003; 33: 766–771. Medline
- [13]. Del-Pozo G, Albillos JC, Tejedor D, et al. Intussusception in children: current concepts in diagnosis and enema reduction. *RadioGraphics*1999; 19: 299–319. Link
- [14]. Swischuk LE, Hayden CK, Boulden T. Intussusception indications for ultrasonography and/or explanation of the doughnut and pseudokidney signs. *Pediatr Radiol*1985; 15: 388–391. CrossRef, Medline
- [15]. Gayer G, Hertz M, Zissin R. CT findings of intussusception in adults. *Semin Ultrasound CT MR*2003; 24: 377–386. CrossRef, Medline
- [16]. Rintala A. The histological appearance of gastrointestinal polyps in the Peutz-Jeghers syndrome. *Acta Chir Scand*1959; 117: 366–373. Medline
- [17]. Shepherd NA. Polyps and polyposis syndromes of the intestine. *Curr Diagn Pathol*1997; 4: 222–238. CrossRef
- [18]. Panos RG, Opelka FG, Noguera JJ. Peutz-Jeghers syndrome: a call for intraoperative enteroscopy. *Am Surg*1990; 56: 331–333. Medline
- [19]. Oncel M, Remzi FH, Church JM, Connor JT, Fazio VW. Benefits of ‘clean sweep’ in Peutz-Jeghers patients. *Colorectal Disease*2004; 6: 332–335