

## An Unusual Presentation of All the 6 Mandibular Anterior Teeth Having 2 Root Canals in a Single Patient –A Case Report

\*<sup>1</sup>Dr. Ramesh Chandra, <sup>2</sup>Dr. Shailja Singh, <sup>3</sup>Dr. IjajAhamad M. Tamboli,  
<sup>4</sup>Dr. Divya Chowdhary, <sup>5</sup>Dr. Amaan Khan  
Corresponding Author: Dr. Ramesh Chandra,

### **Abstract:**

**Aim:** Report of unusual presentation of two root canals in all mandibular anterior in a single patient.

**Summary -** The dental pulp presents with a variety of configurations and shapes throughout the dentition. Varying number of the root canals in different teeth, their anatomy and interconnections have been studied and reported. This case report describes two root canals in all mandibular anterior teeth in single individual, in which the successful endodontic treatment has done in mandibular lower left anterior teeth. Radiographic examination revealed multiple canals in all mandibular central, lateral incisors and canine having two canals in all of them. Endodontic intervention resulted in successful treatment of this unusual canal morphology. Literature reveals multiple canals in the mandibular central and lateral incisor and canine teeth individually, but the highlight of this case report is finding of two canals in all 6 mandibular anterior teeth.

Date of Submission:09-12-2017

Date of acceptance: 23-12-2017

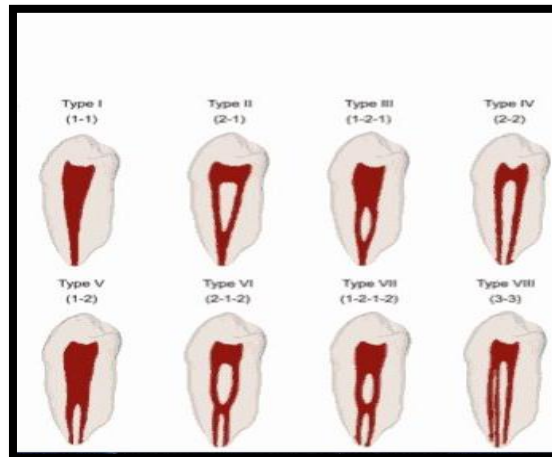
### **I. Introduction**

The Dental Pulp Presents With A Variety Of Configurations and shapes throughout the dentition. Therefore, a thorough knowledge of tooth morphology, careful interpretation of radiographic documentation and adequate access to exploration of the pulpal space are prerequisites for all root canal procedures. <sup>(1)</sup> The root canal system of mandibular incisors often have three pulp horns and a single root canal, but it is also been demonstrated that there is presence of bifurcated and lateral canals also. The bifurcation of a root canal is the position at which a single canal separates into two smaller canals that follow divergent pathways; but in some cases, the canals may rejoin to form a single canal again. <sup>(2)</sup> As reported, more than 40% of mandibular incisors show the presence of two canals and teeth more than 1% has two separate apical foramina. <sup>(3,4)</sup> Despite the low prevalence, clinicians should take into consideration the possible variations in the number of roots and root canals of mandibular incisors. Failure by the operator to recognize the anatomy of a root canal system and the possible developmental anomalies may lead to inadequate cleaning and shaping of the root canal system, which in turn may contribute to failure of endodontic treatment and lead to need for endodontic retreatment. <sup>(5)</sup> A wide morphological divergence of the root canal systems is known to exist. Varying number of the root canals in different teeth, their anatomy and interconnections have been studied and reported by several authors (**figure I**). The striking feature of this report however was the presence of two root canals in all mandibular incisor teeth, each with 2 canals.

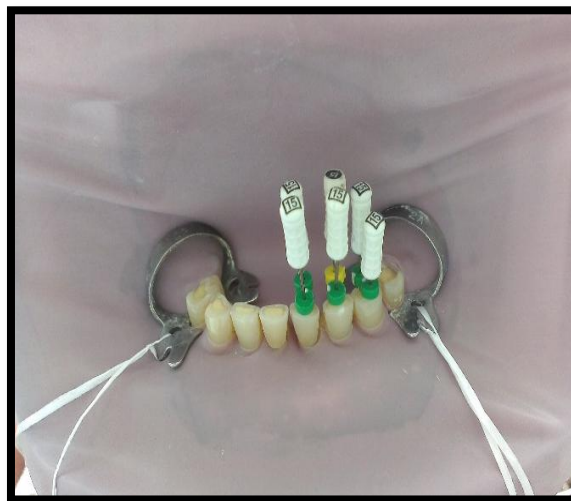### **II. Case Report**

A 48-year-old male patient reported to the department of conservative dentistry and endodontics, Career Post Graduate Institute of Dental Sciences and Hospital, with the chief complaints of pain with lower left front region of the jaw since a month. The medical history was noncontributory. Patient had experienced trauma to the mandibular left anterior region 2 years back. The clinical examination revealed pain on percussion and no response was seen to thermal and electrical pulp sensitivity tests on lower left incisors and canine. Widening of periodontal ligament space was seen in the pre-operative radiograph. A pre-operative radiograph of mandibular right (a) and left anteriors (b) showed presence of two canals in each root (**Fig.III a and b**).

**2.1 Clinical and Radiographical images at different stages of Treatment**

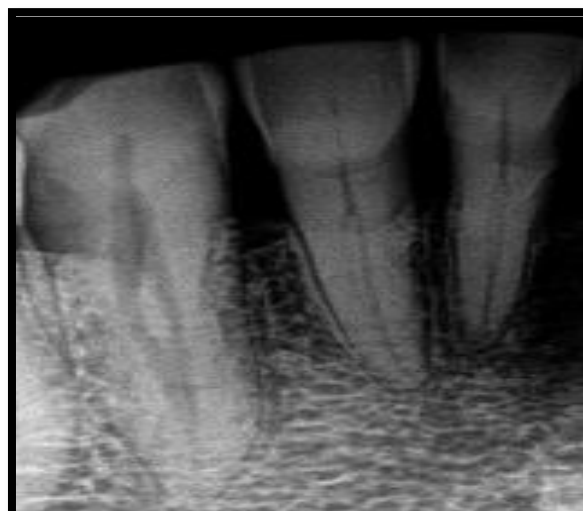

**Fig.I** Vertucci's classification of morphological variation of root canals

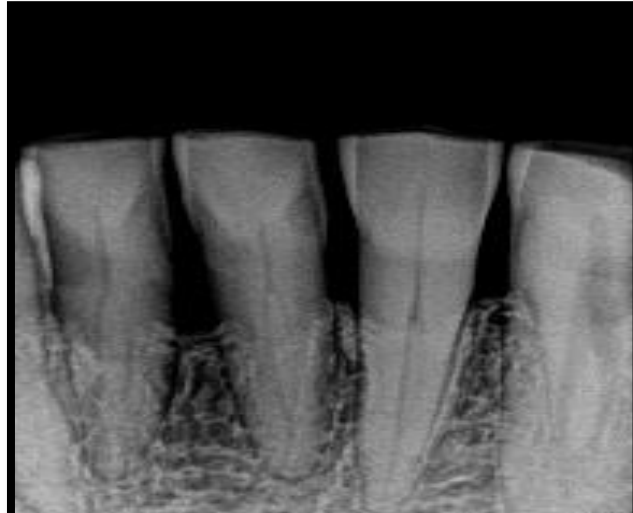


**Fig. II**

At the first appointment, under rubber dam isolation (Hygienic, Coltene Whaledent Inc.,USA) access opening was prepared on mandibular left central incisor ,lateral incisor and canine (**Fig. II**) . The pulp chamber was noted as to have a large size and a second root canal orifice was found in the lingual portion of the pulp chamber after widening the access cavity buccolingually in both the teeth.The patency was confirmed using a no. 10 k file. Working length determination was

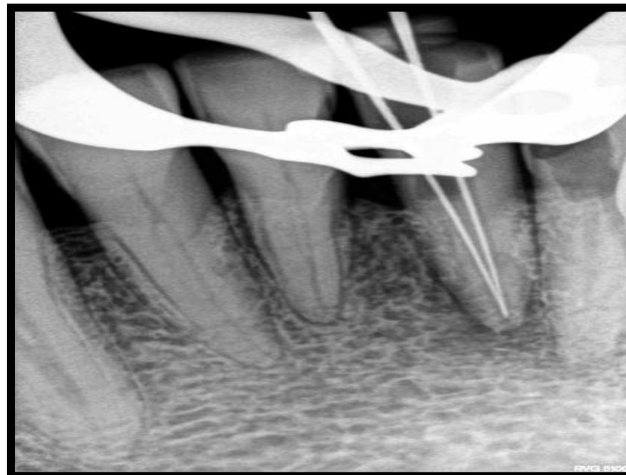


**Fig. III(a)**

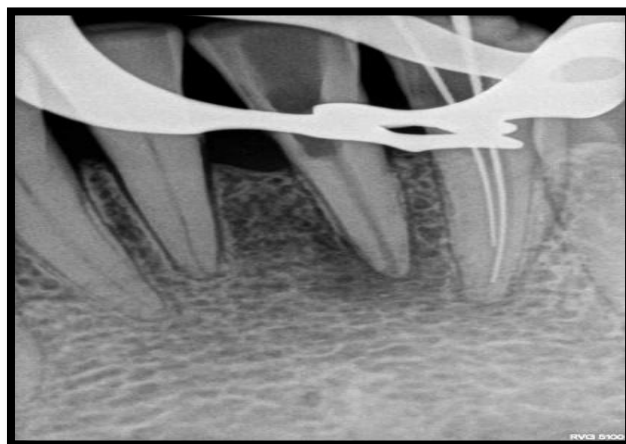


**Fig. III (b)**

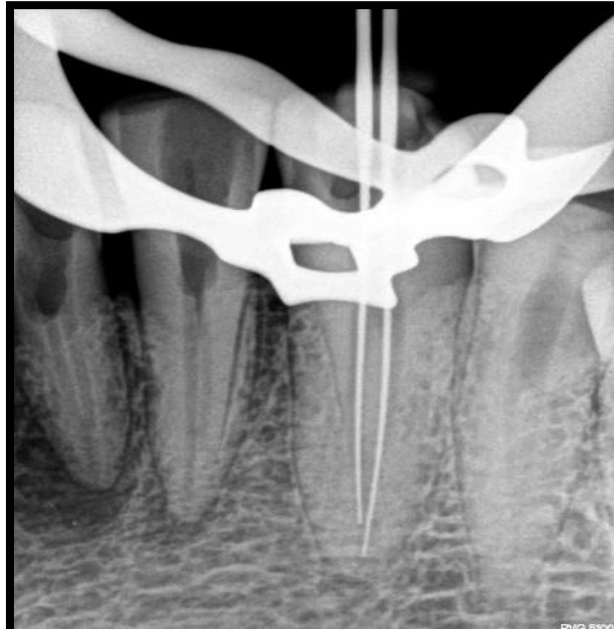done by using a 15. K file. The presence of separate canals was confirmed using different radiographic angulations (**Figure IV a, b and c**). Biomechanical preparation was done using step back technique. Three percent of sodium hypochlorite and 17% EDTA were used for simultaneous irrigation. The canals were thoroughly rinsed with normal saline after each instrument and calcium hydroxide dressing was given for 8 days. In the next visit, master cone radiograph(**Fig. V and VI**) and obturation was done by lateral condensation technique.<sup>(6)</sup>



**a. Central incisor**



**b. Lateral incisor**



c. Canine (fig. IV)

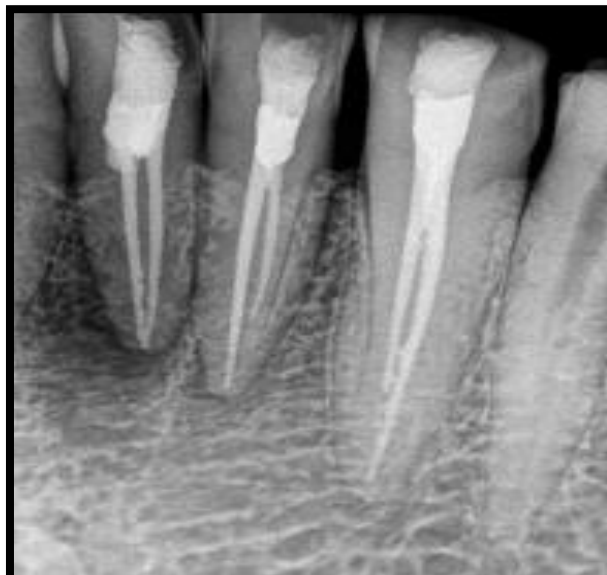
### III. Discussion

The canal configurations were categorized according to Frank J Vertucci's classification <sup>(7)</sup>. The case presented in this report had Vertucci type III canal configuration (1-2-1) for all six mandibular anterior teeth. It is uncommon that occurrence of all six mandibular anterior teeth in the same patient with Vertucci type III (1-2-1) root. <sup>(8)</sup> Since the success of the endodontic treatment is related to a thorough debridement of the root canals and three dimensional seal of the obturated materials, a good preoperative radiographic evaluation is necessary. The anatomy of root canal systems dictates the condition under which root canal therapy is carried out and can directly affect its prognosis. Extra root or root canals if not detected are a major reason for failure of this treatment <sup>(9)</sup>.

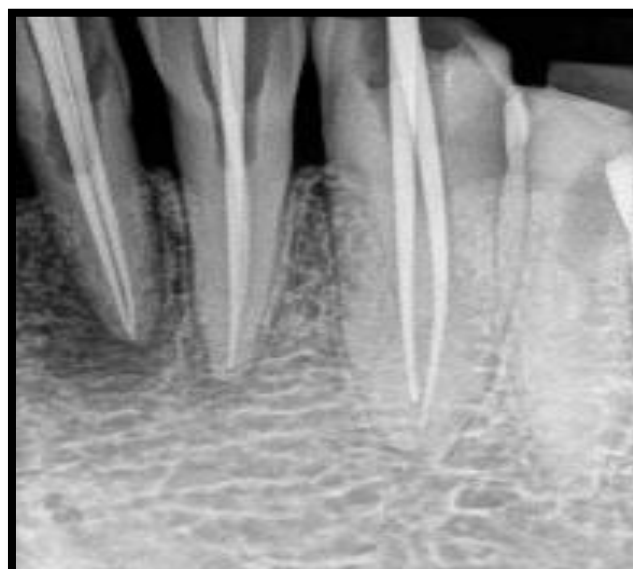

Fig. V

Historically, the lingual approach was used for esthetic and restorative reasons; but, with the improvement of restorative materials this should be less of a concern today. When a lingual access is made, a prominent bulge of dentin is often left in the cingulum area which makes detection and debridement of a lingual canal difficult. Hence Janik has proposed extension of the lingual wall to involve more of the cingulum area in order to explore the lingual canal. While in cases with moderate to extensive incisal wears, Mauger has proposed an



**Fig.VI**

incisal access for straight line access to both the canals.<sup>(10)</sup> Root canal treatment is based primarily on the removal of microbial infection from the complex root canal system. Numerous antimicrobial agents have been recommended as inter appointment dressings<sup>(11,12)</sup>. Calcium hydroxide paste being one of the simplest and remarkably effective antimicrobial medicament was used in this case.

#### **IV. Conclusion**

The complexity of the root canal system is best understood by the integration of thorough knowledge of tooth anatomy and correct interpretation of radiographs is important. Radiographs taken from at least two different angles must be studied. Modification of the access opening were required, which will assist the clinician for a more thorough assessment and successful treatment.

#### **References**

- [1]. Cohen's Pathways of the pulp, 11th ed. by Kenneth M Hargreaves, Louis H Berman Mosby Year Book Inc.; 2016. p. 130.
- [2]. Deepak D Kakde et al Mandibular incisors with two canals in a patient: A rare case JIMD 2016;(3): 164-167
- [3]. Carrotte P. Endodontics: part 4. Morphology of the root canal system. BrDent J 2004; 197: 379-83
- [4]. Saraswathi FK, Toran S, Kumar P.
- [5]. Supplemental Rudimentary Tuberculates with Unusual Morphology: A Case Report. Int J Dent Clinics 2010; 2: 42
- [6]. abak YS, Abbott PV. Endodontic treatment of mandibular incisors with two root canals: report of two cases. Aust Endod J 2007; 33:27-31
- [7]. Vertucci FJ. Root canal anatomy of the mandibular anterior teeth. J Am Dent Assoc 1974; 89:369-71.
- [8]. Vertucci FJ. Root canal anatomy of the human permanent teeth. Oral surgery, oral medicine, oral pathology. 1984;58:589-99.
- [9]. Vertucci FJ. Root canal anatomy of the human permanent teeth. Oral Surgery, Oral Medicine, Oral Pathology 1984; 58: 589-99
- [10]. Slowey RR. Radiographic aids in detection of extra root canals. Oral Surgery Oral Medicine Oral Pathology 1974;37: 762-71. Mauger MJ, Waite RM, Alexander JB, Schindler WG. Ideal endodontic access in mandibular incisors. Journal of Endodontics. 1999;25:206-7.
- [11]. Bystrom A, Claesson R, Sundquist G. The antibacterial effect of camphorated paramonochlorophenol, camphorated phenol, and calcium hydroxide in the treatment of infected root canals. Endodontics and Dental Traumatology 1985;1:170-5.
- [12]. Hasselgren G, Olsson B, Cvek M. Effects of calcium hydroxide and sodium hypochlorite on the dissolution of necrotic porcine muscle tissue. Journal of Endodontics 1988;14:125-7

\*Dr. Ramesh Chandra. "An Unusual Presentation of All the 6 Mandibular Anterior Teeth Having 2 Root Canals in a Single Patient –A Case Report." IOSR Journal of Dental and Medical Sciences (IOSR-JDMS) 16.12 (2017): 61-65