

Original Research article

## Importance of Ligating The Sciatic Nerve in Above Knee Amputation To Prevent Neuroma Formation

Dr. Amit Saraf<sup>1</sup>, Dr. Poonji Gupta<sup>2</sup>

<sup>1</sup>Associate Professor MBBS MS (Orthopaedics) Teerthanker Mahaveer medical college & research centre, Moradabad

<sup>2</sup>Senior Resident MBBS MS (ENT) Teerthanker Mahaveer medical college & research centre, Moradabad  
Corresponding Author : Dr. Amit Saraf MBBS MS (Ortho)

**Abstract:** Sciatic nerve having rich vascularity, has a very high tendency to develop neuroma formation after being cut in above knee amputation<sup>1</sup>. We compared neuroma formation at its cut end after ligating the cord to its being left open in patients who undergo above knee amputation. Patients were assessed for nerve thickening by comparing it with opposite site at same level with a sonogram. Patients with cut ends ligated had less chance of developing neuroma formation. We thus conclude that it is better to ligate the cut end of sciatic nerve in above knee amputation.

Date of Submission: 29-11-2017

Date of acceptance: 09-12-2017

### I. Introduction

Neuroma is a bulbous or hypertrophic enlargement within or cut end of a nerve which is often painful<sup>2</sup>. Sciatic nerve is one of the commonest nerve to develop neuroma after being cut. Sciatic nerve is the thickest nerve in human body. Neural sheath of sciatic nerve is rich in microvasculature. Hypertrophy of the sciatic nerve after lower-limb amputation in patients with sarcomas has been previously reported by magnetic resonance imaging and sonograms; however, there are very less studies on sonographic evaluation of the sciatic nerve after lower-limb amputation due to non-malignant reasons<sup>3</sup>. In this study we compared neuroma formation after ligating the sciatic nerve to leaving its cut end open in patients who undergo above knee amputation.

### II. Aim

To compare the appearance of sciatic nerve after ligating it to leaving cut end open in above knee amputation

### III. Material And Methods

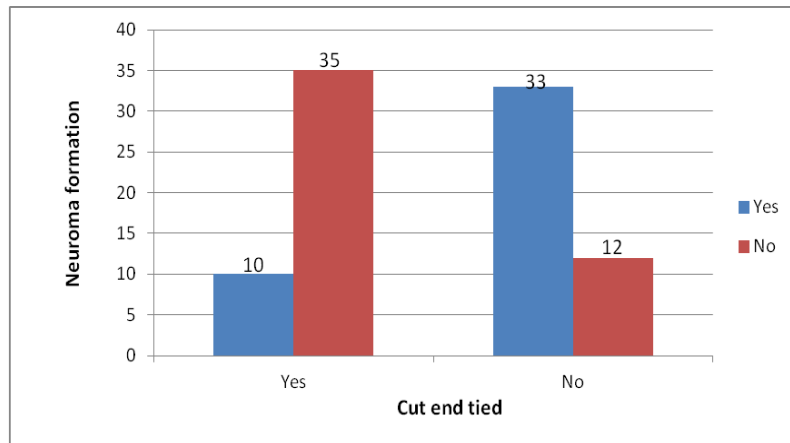
In this study we followed a total of 90 patients who underwent above knee amputation. Only the patients who underwent amputation due to traumatic reasons and burns were included in this study. In half of these patients, cut end of sciatic nerve was left open and in other half, the nerve was tied. Patients in both the groups were age, sex and BMI matched. Neuroma formation in the stump was assessed one year after surgery. This assessment was done by measuring the diameter of sciatic nerve ending using sonogram. Sciatic nerve diameter was measured bilaterally at the same level, and the value of the normal limb was taken as control. Patients with bilateral lower limb trauma, amputation due to medical conditions like diabetes, malignancy, infections, congenital anomalies, or due to side effects of drug intake were excluded from this study.

### IV. Results

Out of 45 patients who underwent ligation of sciatic nerve, only 10 patients developed thickening of the cut end of sciatic nerve in comparison to opposite limb. On the other hand, 45 patients in whom the cut end was left open, 35 patients developed neuroma formation. This result was statistically significant with a p value <0.05

	Neuroma formation	
	Yes	No
Cut end tied	35	10
Cut end not tied	10	35

**Table 1 :** Patients distribution with neuroma formation



**Fig 1** : Neuroma formation in the nerve when cut end are tied versus left open

### **V. Conclusion**

Rich microvasculature of sciatic nerve results in the formation of haematoma beneath the cut end, if it is left open. This haematoma eventually results in growth of neural fibres. As a result of this, neuroma formation occurs at cut end of sciatic nerve in above knee amputation. We thus conclude, it is always wise to ligate the cut end of sciatic nerve in above knee amputation to prevent neuroma formation. Also it is recommended to retract the nerve before ligating so that once the nerve is cut, it retracts back into the tissue and is not left superficial at the stump site to prevent any frictional hypertrophy.

### **References**

- [1]. Thomas L, Mcallister F : Complications following lower extremity amputation : Surg Gynecol Obstet : 1965 : 301-304
- [2]. Kerimoglu U, Canyigit M. Paradoxical hypertrophy of the sciatic nerve in adult patients after above-knee amputation. Acta Radiol. 2007 Nov;48(9):1028-31.
- [3]. Göktepe AS, Özçakar L, Kömürcü E, Safaz I, Yazicioğlu K. Sonographic evaluation of the sciatic nerve in patients with lower-limb amputations. Muscle Nerve. 2010 Jun;41(6):763-6.
- [4]. Appenzeller O : Effects of nervous system lesions on phantom experience in amputees : Neurology : 1969 : 19 : 141-146
- [5]. Aulivola B, Hile C N , Handan A D, Campbell D R, Skillman J J : Major Lower extremity amputation. Outcome of a modern series : Archeives of Surgery : 2004: 139: 395- 399