

Corrective Osteotomy in Obafemi Awolowo University Teaching Hospitals Complex: A 15 Year Review

Orimolade EA^{1, 2}, Asuquo JE³, Akinwande IO², Oyagbesan OS², Ikem IC^{1, 2}

¹Department of Orthopaedic Surgery and Traumatology, Faculty of Clinical Sciences, College of Health Sciences, Obafemi Awolowo University, Ile-Ife, Osun State, Nigeria

²Department of Orthopaedic Surgery and Traumatology, Obafemi Awolowo University Teaching Hospitals Complex, Ile-Ife, Osun State, Nigeria

³Department of Orthopaedic Surgery, University of Calabar Teaching Hospital, Calabar, Cross-River State, Nigeria

Corresponding Author: Dr. I.O. Akinwande

Abstract

Background: Corrective osteotomy is performed most often to correct angular or rotational deformities in the lower limbs. Many deformities in growing children have potentials for spontaneous corrections while some will require corrective osteotomy to effect corrections. The aim of this study is to see the common indications for corrective osteotomy in our centre and their common complications.

Methods: This is a retrospective study in which clinical information were retrieved from the case notes of patients who had corrective osteotomy at the Obafemi Awolowo University Teaching Hospitals' Complex over a 15 year period (March 2000 to February 2015). Information on age, the diagnosis, types of deformities, severity and complications of the surgeries were retrieved.

Results: One hundred and twenty seven patients, whose case notes were found, were studied. Forty nine were males while 78 were females with M: F of 1:1.6. Blount's disease was the most common indication for corrective osteotomy in our centre being present in 54 (42.9%) patients. Rickets was the second most common indication seen in 36 (28.6%) of the patients. Angular deformities from osteoarthritis were the only indication for corrective osteotomy in the middle aged and elderly. The deformities in these patients were often severe. Wound dehiscence was the commonest complication found in 22 (19.0%) of the patients.

Conclusion: Blount's disease was the commonest indication for corrective osteotomy in our centre followed by rickets. The deformities are often severe. Patients with rickets present earlier for correction than patients with Blount's disease. Knee Osteoarthritis was the main indication for corrective osteotomy in the middle age and elderly.

Date of Submission: 24 -10-2017

Date of acceptance: 07-12-2017

I. Introduction

Corrective osteotomy is one of the common orthopaedic surgeries and it is often performed to correct angular and/or rotational deformities. It is the gold standard for angular deformities and a number of these deformities occur frequently in infancy and childhood¹. Angular and torsional deformities are the most common musculoskeletal complaints encountered by paediatricians and a common cause of referral to orthopaedic surgeons¹. In addition to being a cosmetic problem and major concern to parents, it can lead to early osteoarthritis in later life because of joint overload². Physiological genu varum and genu valgum should be recognized as these deformities represent normal variations of the growth and development of the child and needs no treatment except for observation and reassurance of the parents³. Several studies in Nigeria have shown rickets to be the commonest cause of angular deformity of the knee in children and indeed the commonest cause of pathologic knee deformity⁴⁻⁶. It has also been suggested that in Nigeria, the commonest aetiology for rickets is a dietary lack of calcium^{7-8, 11}. Indeed, there is literary evidence of resolution of symptoms of rickets with treatment with calcium replacement only⁹⁻¹¹. Failure of resolution of the deformities with medical treatment will necessitate surgical care with corrective osteotomy and hence the objectives of this study were to determine the commonest indication and complications of corrective osteotomies in our centre.

II. Materials And Methods

This was a retrospective study in which clinical information were retrieved from the medical records of patients who had corrective osteotomy at the Obafemi Awolowo University Teaching Hospitals' Complex over a 15 year period (March 2000 to February 2015). A total number of 127 case notes were retrieved and

information on age, gender, diagnosis, deformity, severity and complication of the surgeries obtained, were entered into a structured proforma. The data obtained were analyzed with Statistical Package for Scientific Solution (SPSS) Version 23 (IBM SPSS Incorporated, Chicago, Illinois) and the results presented as table and figures.

III. Results

There were 49 (38.6%) males and 78 (61.4%) females giving a male: female ratio of 1:1.6 (Figure 1). The age of the patients ranged from 2 to 76 years with a mean of 16.4 years. Paediatric angular knee deformity was the commonest indication for corrective osteotomy with 102 (80.3%) patients below the age of 20 years. The knee was affected in 118 (92.9%) patients.

Table 1: Age Distribution

Age (years)	Group	0-10	11-20	21-30	31-40	41-50	51-60	61-70	71-80	Total
Frequency		82	20	5	3	2	7	5	3	127
Percent (%)		64.6	15.7	3.9	2.4	1.6	5.5	3.9	2.4	100.0

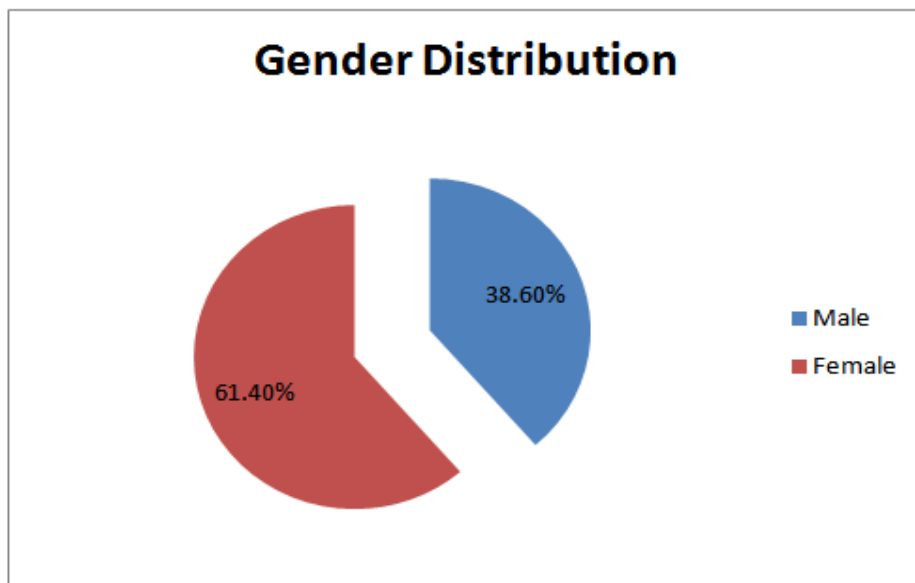
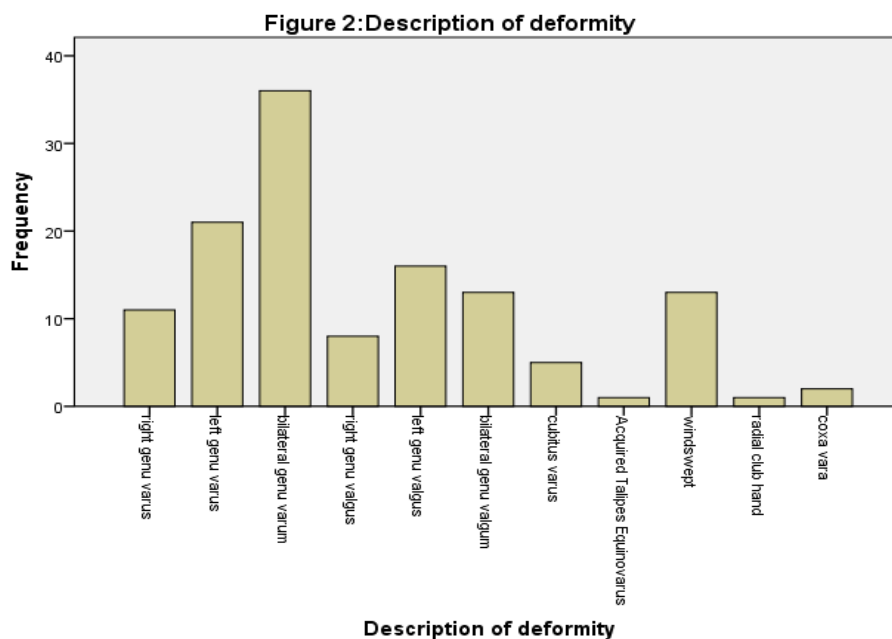
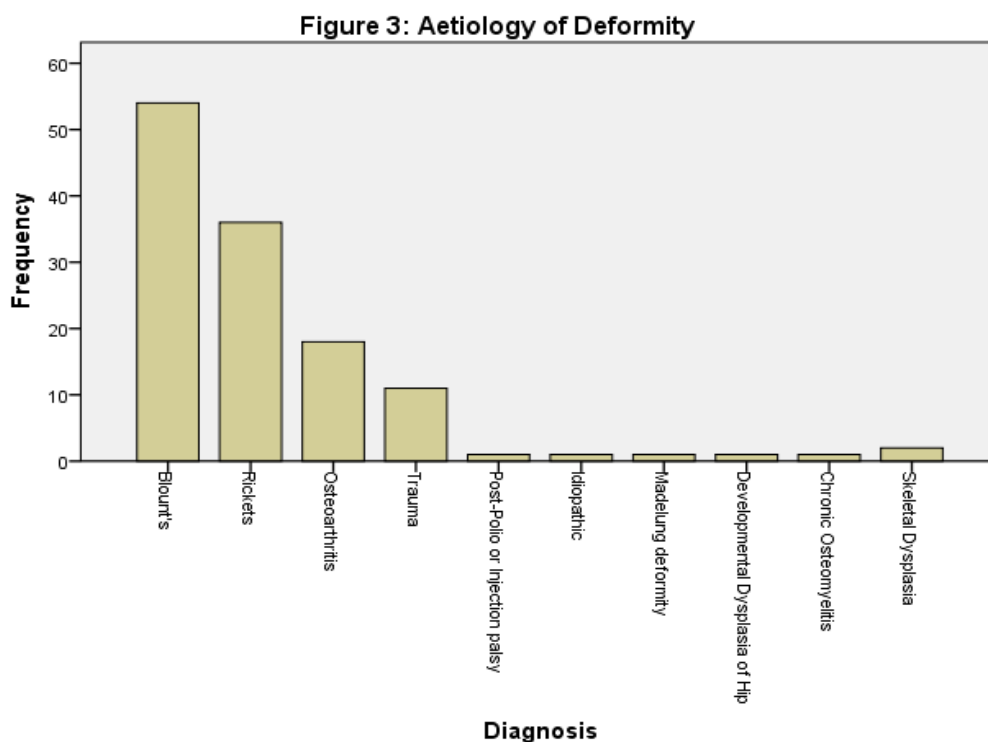


Figure 1: Gender Distribution



The commonest deformity was bilateral genu varum in 36 patients (28.3%) out of which 31 (24.4%) patients were diagnosed to have Blount's disease. Angular deformities were rare in the upper limbs where cubitus varus was found in 5 patients (3.9%); all were due to malunited supracondylar humeral fractures (Figure 2). Blount's disease was the most common underlying aetiology for corrective osteotomy in our centre being present in 54 (42.9%) patients. Rickets was the second most common indication seen in 36 (28.6%) of the patients. Osteoarthritis (primary and secondary) was the only indication for corrective osteotomy in the middle aged and elderly. Twelve out of the 18 patients had genu valgum deformity (Figure 3).



Six, 6 (4.7%) patients presented with recurrent deformity, out of which 3 patients had Blount's disease, 2 patients with rickets and the last patient had trauma. Cast orthosis was the commonest method of postoperative stabilization (114 (89.8%) patients), followed by Implant combined with Cast in eight patients(6.3%). Only five patients (3.9%) had implant stabilization without cast application. Most of the deformities were severe as only 42 (35.6%) patients did not require postoperative serial manipulation. Wound dehiscence was the commonest complication found in 22 (19.0%) of the patients followed by flap necrosis in 4 (3.4%) patients.

IV. Discussion

Angular deformity of the knee remains a common presentation to orthopaedic surgeons. There are several aetiologies of which rickets have been identified as the commonest cause in our environment. Salawu in Zaria evaluated 103 children with angular knee deformities and found a 70% incidence of rickets⁴. Oyemade found a 41% incidence of rickets among 114 subjects studied in Ibadan⁵. Bafor et al found a 46% incidence of rickets among 78 patients with angular knee deformities in University of Benin Teaching Hospital⁶. Solagberu in a study carried out at Ilorin, North Central, Nigeria, found physiological and post-rickets deformities as the common causes of angular deformities of the knee in children¹³. Rickets being the commonest cause of angular knee deformity in our environment was expected to be the commonest indication for corrective osteotomy. However, Blount's disease was found to be the commonest indication for corrective osteotomy in our centre which accounted for 42.9% (54 patients). This is comparable to the study by Adewole et al which found Blount's disease to account for 48.7% of surgically corrected limb deformities¹². Blount's disease is a progressive disease that rarely corrects without surgical intervention as compared to rickets whose skeletal manifestations mostly tend to correct with medical treatment with calcium and vitamin D by restoring mineralization of the osteoid. In Blount's disease, continuous compression of the tibial upper postero-medial physis is believed to retard physeal growth medially while the lateral tibial and fibula physes grows normally. This differential growth results in medial bowing seen in Blount's disease (Heuter-Volkman's principle)¹⁴. Physiological angular knee deformities usually corrects spontaneously with growth. In our study, bilateral genu

varum was found in 28.3% (36 patients). Adewole et al also found bilateral genu varum as the commonest deformity in 45.1% of the study population in Lagos¹². The need for postoperative serial manipulation in 76 patients (64.4%) was due to the severity of the deformities at presentation. The tibio-femoral angle measurement in standing orthogonal radiograph is the best way to measure the severity of these deformities. This is not routinely done in our environment. The few cases in which angles were documented showed no distinction between clinical and radiological measurements, hence cannot be compared. The poor health seeking behaviour and poor socio-economic state of our populace may account for the severity of the deformities. Guardian or parents may be anticipating spontaneous correction as often seen in physiological deformities or patients with rickets adequately treated with calcium and vitamin D. In Blount's disease, this delay leads to worsening of deformities as it often fails to correct. Patients and guardians should be educated on the entity called Blount's disease which does not correct spontaneously or with medical treatment. Diagnosis of Blount's disease can be made in radiographs of 3-4 year old when present. Even though, recurrence is common in patients operated early for Blount's disease, it is still advised. Overcorrection into valgus should be done in younger patients with many years of remaining growth to reduce or delay recurrence in Blount's disease unlike Rickets in which correction into normal alignment at surgery or at post-operative manipulations often suffices. The commonest complication was wound dehiscence in 22 patients (19.0%). The medial wound used for the tibia osteotomy is often affected while the lateral fibulotomy or fibulectomy wounds of proximal tibial corrective osteotomies are usually not affected. The medial wound is under stretch with valgus manipulation to correct varus deformities. The more the varus deformity, the more the stretch of the medial skin and the higher the chances of wound dehiscence. Premature removal of sutures before completion of the manipulation may worsen this complication. Acute overcorrection of severe deformities should be avoided to prevent vascular spasm.

V. Conclusion

Corrective osteotomy is one of the common orthopaedic surgeries performed in our centre. Even though rickets has been widely reported as the most common cause of angular deformities in our environment, the commonest indication for corrective osteotomy is Blount's disease followed by Rickets. The commonest complication found is wound dehiscence. The populace should be educated on Blount's disease whose treatment is usually surgical.

VI. Limitation

This is a retrospective study with its limitation of incomplete information. The measurement of the angles on appropriately taken radiographs would have best described the severity of the deformities.

References

- [1]. Bruce RW. Torsional and Angular Deformities Pediatric Clinics of North America. 1996;43(4):867-882.
- [2]. Janakiraman N, Teichtahl AJ, Wluka AE et al., "Static knee alignment is associated with the risk of unicompartmental knee cartilage defects," *Journal of Orthopaedic Research*. 2008; 26(2): 225-230.
- [3]. Espandar R, Mortazavi SM, Baghdadi T. Angular Deformities of the Lower Limb in Children *Asian Journal of Sports Medicine*. 2010; 1 (1): 46-53.
- [4]. Salawu SA. Knock-knee and bow leg in Zaria. *Orient Journal of Medicine*. 1992; 4: 69-72.
- [5]. Oyemade GAA. Aetiological factors in genu valga, vara and varovalga in Nigerian children. *Environmental Child Health*. 1975; 167-172.
- [6]. Bafor A, Ogbemudia AO, Umebese PFA. Epidemiology of angular deformities of the knee in children in Benin. *Sahel Medical Journal*. 2008; 11(4): 114-117.
- [7]. Oginni LM, Worsfold M, Oyelami OA, Sharp CA, Powell DE, Davie MWJ. Etiology of rickets in Nigerian children. *J Paed*. 1996;128(5): 692-94.
- [8]. Okonofua F, Gill DS, Alabi ZO, Thomas M, Bell JL, Dandona P. Rickets in Nigerian Children: a consequence of calcium malnutrition. *Metabolism*. 1991; 40:209-13.
- [9]. Oginni LM, Sharp CA, Badru OS, Risteli J, Davie MWJ, Worsfold M. Radiological and biochemical resolution of nutritional rickets with calcium. *Arch Dis Child*. 2003; 88:812-817.
- [10]. Oginni LM, Sharp CA, Worsfold M et al. Healing of rickets after calcium supplementation. *Lancet*. 1999; 353:296-297.
- [11]. Bafor A, Ogbemudia AO. Musculoskeletal Manifestations of Rickets: An Eighteen-month Observational Study *African Journal of Tropical Medicine and Biomedical Research*. 2012;2 (1): 27-32
- [12]. Adewole OA, Fadeyibi IO, Giwa SO, Kayode MO, Shoga MO, Fasawe AA. Limb Deformities: The Lagos, Nigeria Experience *Sahel Medical Journal*. 2009;12(1):6 - 9
- [13]. Solagberu BA. Angular deformities of the knees in children. *Nig J Surg Res*. 2000; 2:62 - 67
- [14]. Cook SD et al. A Biomechanical Analysis of the Etiology of Tibia Vara. *Journal of Paediatric Orthopaedics*. 1983; 3(4): 449-454