

Hollow Vaginal Dilator- A Case Report

P.Gnanavi¹, K.Ram kumar², G.Gomathi², K.Bakyala kshmi², P.Siva kumar³

¹(Senior Intern, Department Of Dental Surgery, Stanley Medical College, India, Chennai)

²(Professor Department Of Dental Surgery, Stanley Medical College, India, Chennai)

³(Dental Technician, Department of Dental Surgery, Stanley Medical College)

Corresponding Author: P.Gnanavi

Abstract: Mullerian Agenesis is a congenital malformation of female genital tract; it is either absence of vagina or absence of uterus or combination of both. It is a rare condition that occurs in females. There are different treatment modalities such as surgical, non-surgical method. Non-surgical method is providing a prosthetic vaginal dilator, where the prosthodontist play an important role. This article discuss about the steps followed in fabrication of a hollow prosthetic vaginal dilator.

Keywords: Hollow vaginal dilator, Mullerian Agenesis, functional impression.

Date of Submission: 14 -12-2017

Date of acceptance: 25-12-2017

I. Introduction

Vagina being a part of female genital tract is a muscular and an elastic organ. The lining of the vaginal canal is soft and flexible due to its elasticity; the nerve ending in vagina is very sensitive which provides the sensation, there are different malformations that occur in female genital organ, and one such malformation is Mullerian Agenesis. Occurrence of Mullerian Agenesis is one in 4,000 to 10,000 females [1]. Mullerian Agenesis is a congenital malformation that occurs in females due to developmental failure of vagina from the mullerian duct resulting in missing uterus and variable malformation of vagina [2]. Mullerian Agenesis is also referred to as Vaginal Agenesis, Congenital Absence of Uterus and Vagina (CAUV), Mullarian Aplasia, Mayer-Rokitansky-kuster-Hauser-Syndrome (MRKH SYNDROME), Genital Renal Ear Syndrome (GRES).It occurs due to heterozygous transformation of WNT4 gene on chromosome 1p36[3]. This gene is responsible for female reproductive system; in its absence, duct generally is absent or deformed or never grows the female reproductive system. The MRKH syndrome shows normal development of secondary sexual characteristics and a normal 46, XX karyotype [4]. Symptoms include lack of menstrual cycle during puberty, kidney problem, bone malformation, renal anomalies, hearing loss. The initial sign and most common sign for MRKH syndrome is primary amenorrhea [2][4][5]. Where, Amenorrhea is absence of menstrual periods in a woman. They are classified as primary and secondary amenorrhea. Primary amenorrhea is a condition in woman who have not reached menarche up to 16 years of age, whereas secondary amenorrhea is, woman giving a history of irregular periods. The MRKH syndrome are of two types, Type I (isolated) and Type II or MURCS association (Mullerian duct aplasia, renal dysplasia and cervical somite anomalies)[2][3][5].Type I MRKH syndrome is characterized by the presence of two rudimentary uterine buds connected by a peritoneal fold, normal fallopian tubes and absence of the upper part of the vagina[7].Type II MRKH syndrome there is asymmetrical hypoplasia of the uterine buds with or without hypoplasia of one or both fallopian tubes[7]. Investigation for mullerian agenesis includes two-dimensional ultrasound, three-dimensional ultrasound, of which the first is cost effective and the later, is more accurate and very effective diagnostic tool for MRKH syndrome. Magnetic resonance imaging (MRI) also provides a more sensitive and specific means of diagnosis [7]. Management for MRKH syndrome is psychological support to the patient, surgical or non-surgical creation of neo-vagina. Even After surgical management a nonsurgical treatment is necessary. Usage of a vaginal dilator is a non-surgical method of treating vaginal agenesis. To create a vaginal dilator Maxillofacial Prosthodontist plays a major role.

II. Case History

A thirteen year old female reported to the department of dental surgery, Government Stanley Medical College for a prosthetic vaginal dilator, from department of Obstetrics and Gynecology, Government Stanley Medical College (RSRM); history revealed that the patient complained of lower abdominal pain for the past two months and also complained that the patient has not attained menarche, it also revealed that the patient had developed secondary sexual characters (pubic hair and breast development). The patient was planned for reconstruction of vagina (vaginoplasty) under GA. Examination of vagina was done with the help of a gynecologist. Then the wall of the vaginal cavity was coated with lignocaine gel to anesthetize the area for an

impression. Later, Vaseline was applied for easier removal of the impression. The material used for impression was impression compound. The impression compound was needed well with the help of hot water; at bearable temperature the impression of the vaginal cavity was taken. A functional impression was taken by asking the patient to open and close her legs so that the impression gets molded (Figure-1).

III. Fabrication

Once the material was set it was removed and washed thoroughly under running water and immersed in 2% alkaline glutaraldehyde solution for disinfection. The impression was flasked (figure-2). Once the plaster set, the impression compound it was removed by using hot water ; a layer of wax was applied around the entire surface leaving it hollow (Figure-3). The base of the previous flask was deflasked and a new counter was poured, thus, a new counterpart was made and dewaxed now the mould is hollow (Figure-4). Heat cure acrylic was mixed in dough stage packed and cured at 740C for 2 hours and then increased the temperature of water bath to 1000C and processing for 1 hour [6].The final prosthesis was very well trimmed and polished to eliminate sharp areas in the dilator (Figure-5). The prosthetic vaginal dilator measured 5 cm x 1.5 cm (Figure-6). The vaginal dilator was inserted by applying lignocaine gel for it to be less painful. As per requirement of the gynecologist a through and through hole was made in the vaginal dilator to check for discharge (Figure-7). The patient was asked to do functional movements, it had good stability, and a self-usable prosthesis. The patient was instructed on the usage of vaginal dilator. The case was posted under GA for increasing the length as the length was deficient, perivaginal examination was done, deficiency in length of the prosthetic dilator was noted. A silicon coated foley balloon catheter was inserted in the through and through hole of the prosthetic dilator, Impression compound and greenstick was needed together, placed on the tip of the catheter, inserted in to the vaginal cavity and molding done (Figure 8A). The balloon of the catheter was inflated using normal saline and verified (Figure 8 b).The increased length is shown in relation to the scale in (Figure 9).The balloon was deflated by removing the saline and inserted in to the vaginal cavity and inflated now and kept in position for two days .The dilator was removed patient was comfortable with the length ,the added impression compound with the foley was acrylized and the final prosthesis shown in (Figure 10 a), patient was able to insert and remove and comfortably. The final prosthesis size increased up to 7.5 cm x 0.8mm (Figure 10 b).

IV. Discussion

Mullerian Agenesis is a rare congenital sporadic anomaly that affects the female reproductive system. It is a common cause of primary amenorrhea. The treatment options are surgical and non-surgical. There are various surgical method for creation of Neovagina. 1. Perineal vaginal dilation with inlay skin flap (Mcindole), 2. Peritoneal vaginoplasty (Davydov), 3. Local cutaneous flap (Williams operation), 4. Myocutaneous flap, 5. Laproscopic Vecchiotti operation. Surgical technique has its own advantages and disadvantages, decided based on the need of the patient. Non surgical creation of neovagina can be achieved by Frank dilator method & Ingram method. Frank's hand held dilator method is self dilation of the vagina by using fingers; the limitation of this method is fatigue and uncomfortable position. Whereas, Ingram method is dilation achieved by using elevated anterior portion of bicycle in outpatient clinic. This patient has been treated surgically and followed by prosthetic vaginal dilator. Surgical technique is by perineal vaginal dilation without skin flap modified form of Mcindole technique was used in this case .Frank hand held dilator were in which prosthetic vaginal dilator made of hard acrylic resin were used in this case.

Case report of making a customized acrylic prosthesis in arbitrary bases with the help of a gynecologist has concluded a satisfactory result. A study was conducted on seven patients using a vaginal dilators again, a customized prosthesis was made by arbitrary measurement and worn with the help of a T-shaped perineal bandage, the results concluded a satisfactory result [5]. A solid vaginal dilator made on arbitrary measurements from the surgeons was made with the help of borosil glass [8]. Custom made acrylic hollow vaginal stent was made to serve the purpose of being light weight and the patient was comfortable [9].

All the case reports on vaginal dilator was made by the measurements given by the gynecologist and the further modification in the length and width was made arbitrarily. In this case to make the vaginal dilator more functional and stable, functional impression of the vaginal was taken and hollow dilator was made. Vaginal cavity will have undercuts and cannot be visualized, elastic impression material like alginate and elastomers cannot be used. Rigid impression material like impression compound will be ideal, as the flow of the material can be controlled by the amount of pressure, impression compound was used to record the impression. Functional movements like opening and closing of the leg was done by the patient to make the prosthesis functionally stable .Case reports on vaginal dilator have discussed about the arbitrary method of fabrication, rough measurement of the length and width was suggested by the gynecologist based on this, prosthetic dilator was made. In this case to make the prosthesis more stable impression of the vaginal cavity was taken. The dilator was made hollow for two purposes – to make the prosthesis weight less and to allow the discharge to

drain. Vaginal dilator was stable on insertion and the patient was very much comfortable. This prosthesis was made user friendly so that the patient can remove and wear it by themselves.

V. Conclusion

Non-surgical method of treating MRKH syndrome by using a prosthetic vaginal dilator is very effective. These dilators are user friendly, cost effective. These vaginal dilators have been very successful in treating this rare condition.

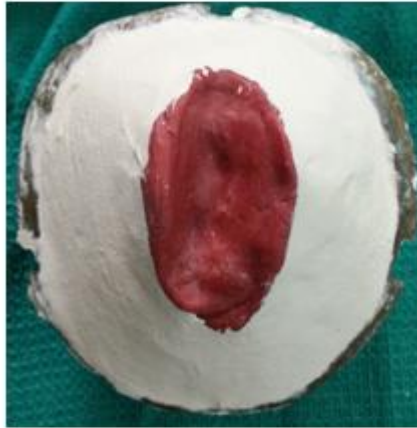
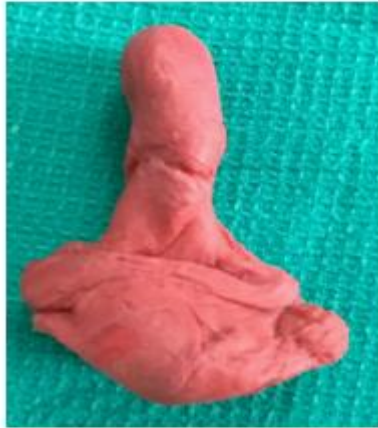

Fig 1 – Impression of the vaginal cavity **Fig 2-** Flasking of the impression



Fig 3 – layer of wax to make hollow

Fig 4 – Mould is hollow, note projection in the base will make the prosthesis hollow

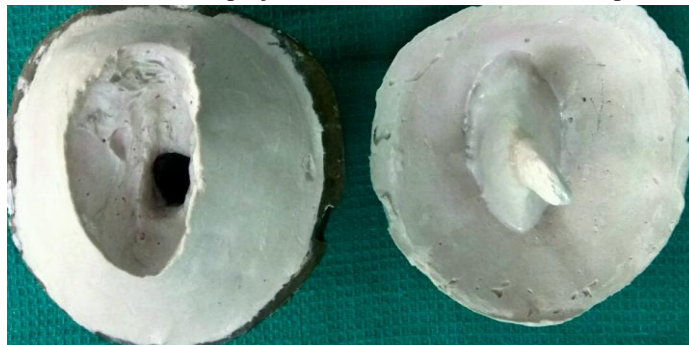


Fig 5 - The final prosthesis

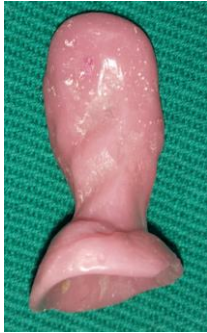

Fig 6 - Prosthesis in relation to scale made hollow

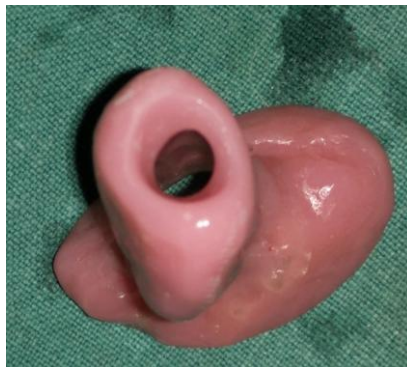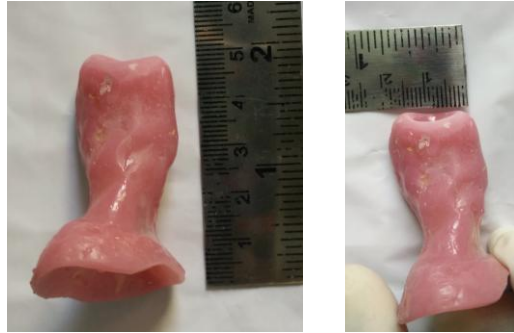


Fig 7 - Hole made on the end of the prosthesis

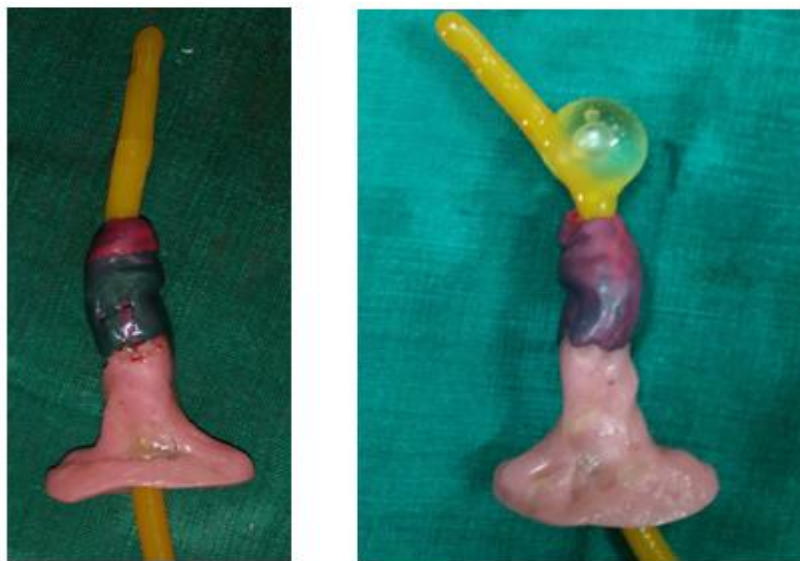

Fig 8 a, b -length increased with Foley and impression compound

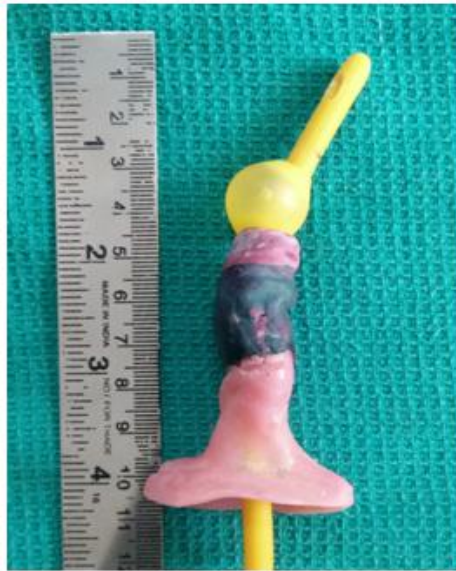

Fig 9 - The increased length in relation to scale

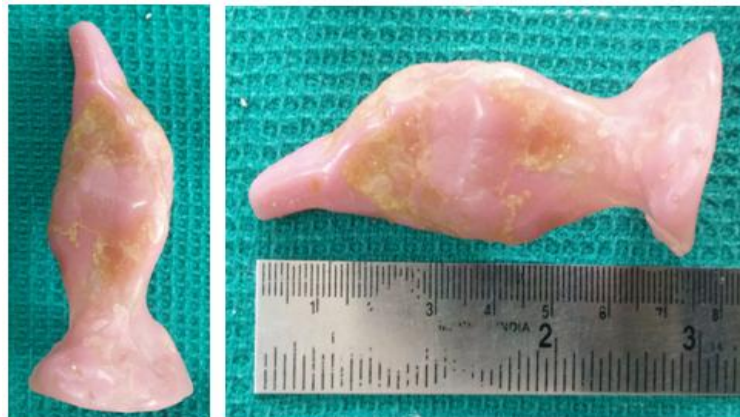

Fig 10 a, b - The final prosthesis with increased length

Acknowledgements

I would like to thank Dr. Rani, head of department; department of obstetrics and gynecology for giving this opportunity to treat the thirteen year old.

References

- [1]. Mullerian agenesis: diagnosis, management and treatment. Committee opinion, The American College of Obstetricians and Gynecologist Number 562 may 2013.
- [2]. PRasmi, TPadmanaban et al. prosthetic vaginal dilator- a case report. Journal of gynecology and obstetrics. 2010 volume 15 number1.
- [3]. Charles sultan et al. Mayer-rokitansky-kuster-hauser syndrome: recent clinical and genetic findings. 29 June 2008.
- [4]. Karinemorcel, Laure Camboriux et al. Mayer-Rokitansky-Kuster-Hauser(MRKH) syndrome. Orphaned journal of rare disease 2007. 2:13.
- [5]. K Sangeetha, G Usha Rani et al. vaginal reconstruction in mullerian agenesis with user-friendly indigeneous prosthetic vaginal dilators. Journal of south asian federation of menopause societies, July- December2014; 2(2).75-78.
- [6]. Phillip's science of dental materials 11th edition Pg: 733 chapter 22.
- [7]. SaudabiValappil, Uma Chetan et al. Mayer-Rokitansky-Kuster-Hauser syndrome: diagnosis and management 2012; 14:93-98.
- [8]. Ramandeep Singh Gambhir fabrication of a prosthesis for a patient with vaginal agenesis. Journal of family medicine and community health.
- [9]. TanviJaiewal et al. custom made acrylic vaginal stent as an adjunct after vaginoplasty for a young female with agenesis of vagina.

P.Gnanavi. "Hollow Vaginal Dilator- A Case Report." IOSR Journal of Dental and Medical Sciences (IOSR-JDMS) 16.12 (2017): 09-13